

---

The Journal of Nuclear Medicine

---

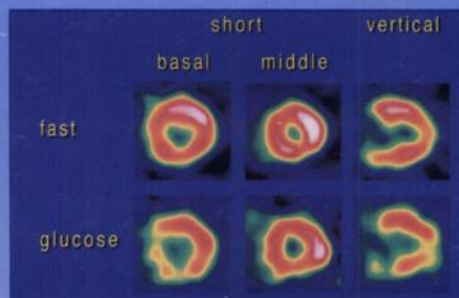
# JNM

---

Volume 38, Number 2 • February 1997

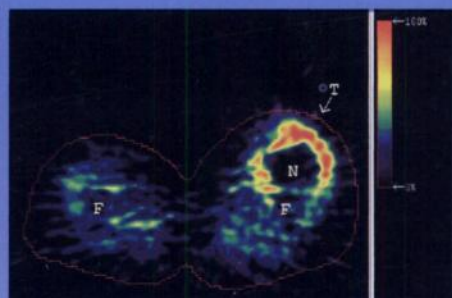
---

## Nuclear Cardiology



Myocardial  $^{123}\text{I}$ -BMIPP images of a patient with effort angina. See pages 175-180.

## Nuclear Oncology



Transaxial PET slice of the upper legs of Patient 3 who has a 16-cm diameter highly malignant necrosis (N) in the right leg (F=femur). See pages 191-194.



---

The Official Publication of  
the Society of Nuclear Medicine, Inc.

---

---

The Journal of Nuclear Medicine

---

**JNMM**

---

Volume 38, Number 2 • February 1997

---

**ADDRESS CHANGE  
EFFECTIVE IMMEDIATELY**

*Submission of manuscripts  
and editorial correspondence  
should be sent to:*

Stanley J. Goldsmith, MD  
Editor-in-Chief

The Journal of Nuclear Medicine  
New York Hospital-  
Cornell Medical Center  
525 E. 68th St.  
Box 311

New York, New York 10021

Phone: (212) 746-9066

Fax: (212) 746-9056



---

The Official Publication of  
the Society of Nuclear Medicine, Inc.

---