suggested interstitial lung disease. Probably these two patients were at special risk of developing interstitial lung disease. Ueda et al. (*30*) detected antibodies to hepatitis C virus in 19 of 66 patients (29%) with interstitial lung disease, the incidence being significantly higher than that in 9464 apparently healthy volunteers (346, or 4%, had such antibodies), and they suggested that hepatitis C virus might be implicated in this lung disease. If so, there being several patients before IFN therapy with unusually high Lu/B may be accounted for.

CONCLUSION

Changes in the accumulation of ^{67}Ga-citrate were measured by calculation of the count per unit size in the ROI. Such changes could not have been inspected visually. This technique made numerical evaluation of the accumulation possible, so it seemed useful for the early diagnosis of interstitial lung disease caused by IFN and other drugs. Patients given IFN for treatment of liver disease had increased uptake of the radionuclide in their lungs, showing an increased immune response that might in some patients lead to interstitial lung disease.

REFERENCES

1. Hoofnagle JH, Peters M, Mullen KD, et al. Randomized, controlled trial of recombinant human α-interferon in patients with chronic hepatitis B. *Gastroenterology* 1988;95:1318–1325.
2. Di Bisceglie AM, Martin P, Kassianides C, et al. Recombinant interferon alfa therapy for chronic hepatitis C: a randomized, double-blind, placebo-controlled trial. *N Engl J Med* 1989;321:1506–1510.
3. Schultz M, Müller R, von zur Mühlen A, Brabant G. Induction of hyperthyroidism by interferon-α-2b. *Lancet* 1989;1:1452.
4. Chung Y-H, Shong YK. Development of thyroid autoimmunity after administration of recombinant human interferon-α-2b for chronic viral hepatitis. *Am J Gastroenterol* 1993;88:244–247.
5. Mayet W-J, Hess G, Gerken G, et al. Treatment of chronic type B hepatitis with recombinant α-interferon induces autoantibodies not specific for autoimmune chronic hepatitis. *Hepatology* 1989;10:24–28.
6. Silva MO, Reddy KR, Jeffers LJ, Hill M, Schiff ER. Interferon-induced chronic active hepatitis? *Gastroenterology* 1991;101:840–842.
7. Koivisto VA, Pelkonen R, Cantell K. Effect of interferon on glucose tolerance and insulin sensitivity. *Diabetes* 1989;38:641–647.
8. Fabris P, Betterle C, Floreani A, et al. Development of type 1 diabetes mellitus during interferon alfa therapy for chronic HCV hepatitis. *Lancet* 1992;340:548.
9. Renault PF, Hoofnagle JH, Park Y, et al. Psychiatric complications of long-term interferon alfa therapy. *Arch Intern Med* 1987;147:1577–1580.
10. Meyers CA, Scheibel RS, Forman AD. Persistent neurotoxicity of systemically administered interferon-alpha. *Neurology* 1991;41:672–676.
11. Cohen MC, Huberman MS, Nesto RW. Recombinant alpha$_2$ interferon-related cardiomyopathy. *Am J Med* 1988;85:549–551.
12. Sonnenblick M, Rosin A. Cardiotoxicity of interferon: a review of 44 cases. *Chest* 1991;99:557–561.
13. Chin K, Tabata C, Satake N, Nagai S, Moriyasu F, Kuno K. Pneumonitis associated with natural and recombinant interferon alfa therapy for chronic hepatitis C. *Chest* 1994;105:939–941.
14. Kamitsukasa H, Ohtake M, Kawashima H, Yagura M, Harada H, Katayama T. Two cases of interstitial pneumonia induced by interferon therapy for chronic aggressive hepatitis, type C. *Acta Hepatol Jpn* 1993; 34:478–483 (in Japanese with English abstract).
15. Daito K, Suou T, Kawasaki H. A case of chronic hepatitis C with interstitial pneumonitis during interferon therapy. *Acta Hepatol Jpn* 1993; 34:718–722 (in Japanese with English abstract).
16. Yamamoto S, Shimabara M, Yamamoto R, et al. A case of chronic hepatitis C with pneumonitis during interferon therapy. *Nippon Shokakibyo Gakkai Zasshi* 1993;90: 2142–2146 (in Japanese).
17. Crystal RG, Fulmer JD, Roberts WC, Moss ML, Line BR, Reynolds HY. Idiopathic pulmonary fibrosis: clinical, histologic, radiographic, physiologic, scintigraphic, cytologic and biochemical aspects. *Ann Intern Med* 1976;85:769–788.
18. Niden AH, Mishkin FS, Khurana MML. Gallium-67-citrate lung scans in interstitial lung disease. *Chest* 1976;69(suppl):266–268.
19. Scheuer PJ, Thaler H, Desmet VJ, et al. Acute and chronic hepatitis revisited: review by an international group. *Lancet* 1977;2:914–919.
20. DeGroote J, Desmet VJ, Gedigk P, et al. A classification of chronic hepatitis. *Lancet* 1968;2:626–628.
21. Tzen K-Y, Oster ZH, Wagner HN Jr, Tsan M-F. Role of iron-binding proteins and enhanced capillary permeability on the accumulation of gallium-67. *J Nucl Med* 1980;21:31–35.
22. Nishiguchi S, Kuroki T, Nakatani S, et al. Randomized trial of effects of interferon-α on incidence of hepatocellular carcinoma in chronic active hepatitis C with cirrhosis. *Lancet* 1995;346:1051–1055.
23. Siemsen JK, Grebe SF, Sargent EN, Wentz D. Gallium-67 scintigraphy of pulmonary diseases as a complement to radiography. *Radiology* 1976;118:371–375.
24. Kinoshita F, Ushio T, Maekawa A, Ariwa R, Kubo A. Scintiscanning of pulmonary diseases with ^{67}Ga-citrate. *J Nucl Med* 1973;15:227–233.
25. Swartzendruber DC, Nelson B, Hayes RL. Gallium-67 localization in lysosomal-like granules of leukemic and nonleukemic murine tissues. *J Natl Cancer Inst* 1971;46: 941–952.
26. Line BR, Fulmer JD, Reynolds HY, et al. Gallium-67-citrate scanning in the staging of idiopathic pulmonary fibrosis: correlation with physiologic and morphologic features and bronchoalveolar lavage. *Am Rev Respir Dis* 1978;118:355–365.
27. Cooper JAD Jr, White DA, Matthay RA. Drug-induced pulmonary disease. Part 1: cytotoxic drugs. *Am Rev Respir Dis* 1986;133:321–340.
28. Cooper JAD Jr, White DA, Matthay RA. Drug-induced pulmonary disease. Part 2: noncytotoxic drugs. *Am Rev Respir Dis* 1986;133:488–505.
29. Roth JA, Frank DE. Recombinant bovine interferon-γ as an immunomodulator in dexamethasone-treated and nontreated cattle. *J Interferon Res* 1989;9:143–151.
30. Ueda T, Ohta K, Suzuki N, et al. Idiopathic pulmonary fibrosis and high prevalence of serum antibodies to hepatitis C virus. *Am Rev Respir Dis* 1992;146:266–268.

Detection of Postoperative Deep-Venous Thrombosis Using Technetium-99m-Labeled Tissue Plasminogen Activator

S. Patrick Butler, Tan Rahman, Samantha J. Boyd, Sharon L. Parkes and Richard J. Quinn

Department of Nuclear Medicine, St. George Hospital, Sydney, Australia

The current noninvasive methods of deep-venous thrombosis (DVT) detection in the asymptomatic patient are sufficiently inaccurate so as to preclude their routine use. This present study reports the accuracy of scintigraphic scanning with ^{99m}Tc-rt-PA in asymptomatic postoperative patients using contrast venography as the gold standard. **Methods:** Fifty-three consecutive postarthroplasty patients (30 THR, 23 TKR) (16 women, 37 men; mean age 71 yr; range 52–85 yr) underwent scintigraphic scanning with ^{99m}Tc-rt-PA and contrast venography, on the operated leg, in order to assess the accuracy of this new technique in these asymptomatic patients. **Results:** Eighty-four segments were of diagnostic quality on contrast venography. Of the 15 thrombosed segments, 14 had positive scans. In the 69 nonthrombosed segments, 63 had negative scans. Thus, scintigraphic scanning with ^{99m}Tc-rt-PA had a sensitivity of 93% and a specificity of 91%. **Conclusion:** This study demonstrated that scintigraphic scanning with modified ^{99m}Tc-rt-PA is accurate in the detection of DVT in patients undergoing total hip or total knee arthroplasty.

Key Words: technetium-99m; recombinant tissue plasminogen activator; deep-venous thrombosis

J Nucl Med 1997; 38:219–223

Received Feb. 28, 1996; revision accepted May 8, 1996.

For correspondence or reprints contact: S.P. Butler, MD, Dept. of Nuclear Medicine, St. George Hospital, Sydney 2217, Australia.

It is well established that prophylaxis is effective in preventing the formation of postoperative deep-venous thrombosis (DVT) and pulmonary embolism. Collins et al. (*1*) reviewed more than 70 randomized trials in 16,000 patients that assessed the efficacy of subcutaneous heparin in the prevention of DVT and pulmonary embolism. That study demonstrated that heparin prophylaxis prevents the formation of approximately two-thirds of the cases of DVT and almost half the cases of pulmonary embolism that would be expected if no prophylaxis was used. Further, death due to pulmonary embolism was also reduced. Such prophylaxis is, however, imperfect in that proximal vein thrombosis still was seen in approximately 15% of patients despite optimal prophylaxis. In view of this, it has been proposed to perform routine venography before hospital discharge in addition to primary prophylaxis in patients undergoing major orthopedic surgery (*2*).

Of all the postoperative patients at risk of DVT, the post-total hip and knee replacement group is particularly prone to DVT. Clagett et al. (*3*) reviewed the prevalence of DVT in patients undergoing total hip replacement in 47 clinical trials involving more than 2500 patients. Without prophylaxis, the incidence of DVT was 50%. With various forms of prophylaxis, the incidence was seen to vary from 11% with adjusted dose heparin, to 45% with aspirin. In total knee replacement, the incidence of DVT without prophylaxis approaches 60% (*4*) with prophylaxis being relatively ineffective: 50% DVT incidence in patients with low-dose subcutaneous heparin prophylaxis (*5*), 52% with aspirin prophylaxis (*6*), 50% with postoperative warfarin prophylaxis and 37% with low mole weight heparin prophylaxis (*7*).

Contrast venography is the gold standard for detecting DVT in both symptomatic and asymptomatic high-risk patients (*8*). As contrast venography has well-recognized limitations, several noninvasive diagnostic modalities have been proposed as alternatives. The pathophysiology of a symptomatic thrombosis is different than that of an asymptomatic thrombosis in a postoperative patient (*9*). The thrombi in these asymptomatic patients tend to be isolated in the calf veins, nonocclusive and relatively small. Thus techniques that display a high degree of accuracy in DVT detection in symptomatic patients may not necessarily be applicable to asymptomatic patients.

A recent Phase III clinical trial (*10*) of ^{99m}Tc-labeled modified recombinant tissue plasminogen activator (^{99m}Tc-rt-PA) has demonstrated a high sensitivity and specificity in DVT detection in symptomatic patients. This study reports the accuracy of scintigraphic scanning with ^{99m}Tc-rt-PA in asymptomatic patients using contrast venography as the gold standard.

MATERIALS AND METHODS

Patients

Fifty-three consecutive inpatients of the St. George Hospital, Sydney (16 women; 37 men; mean age 71 yr; range 52–85 yr), who underwent joint arthroplasty (23 total knee replacements, 30 total hip replacements), were entered into this study. All patients had no symptoms of DVT or pulmonary emboli and had an uncomplicated postoperative course. The patients underwent scintigraphic scanning with ^{99m}Tc-rt-PA followed by contrast venography on the operated leg, usually within a 2-hr period. The studies were performed before discharge at an average of 7 days from the time of operation (range 6–13 days). All patients gave informed written consent and the study protocol had been approved by the Legal, Ethics and Morals Committee of the Southern Sydney Area Health Service. All patients were receiving subcutaneous prophylactic heparin (11 standard heparin, 42 low mole weight heparin) when the studies were performed. All patients wore compression elastic stockings and were mobilized early after their surgery. In two patients, the contrast venography was performed after the scintigraphic scan.

Preparation of Radiolabeled Tracer

Technetium-99m-pertechnetate (1 GBq) in 2.5 ml normal saline was added to a prepared kit of modified rt-PA as previously described (*10*) and incubated for 5 min prior to injection. Each patient received 1.5 mg rt-PA with an average activity of 600 MBq (range 400–760 MBq). Injection site was in the arm, usually in an antecubital vein. Instant thin-layer paper chromatography was performed before injection using ITLC-SG support (Gelman Sciences, Ann Arbor, MI) with normal saline and acetone as the eluents. More than 97% of the activity remained protein bound at all times.

Contrast Venography

This was performed according to standard methodology (*11*). After placement of tourniquets at the ankle and calf, 50–100 ml of nonionic contrast was injected into a dorsal foot vein of the operated limb. Anterior, lateral oblique and medial oblique radiographs of the calf were obtained together with anterior views of the thigh. Additional views were taken as needed. The criterion for thrombosis was the presence of a persistent intraluminal filling defect. All the deep veins of the lower extremity needed to be adequately filled with contrast for the venogram to be considered interpretable. Venograms were viewed by two radiologists who were blinded to all other investigations. Venograms were analyzed on a segment-by-segment basis. Venograms were divided into two segments: proximal (involving the popliteal and the femoral vein) or distal (involving only the calf veins). All segments were classified as being normal, positive for thrombosis or uninterpretable. If there was a difference of opinion between both radiologists, the venogram was classified as being uninterpretable.

Scintigraphic Imaging

Images were obtained with a Siemens Diacam gamma camera (Siemens Gammasonics, Hoffman Estates, IL) interfaced with a Siemens ICON computer (Siemens Gammasonics, Hoffman Estates, IL). A high-resolution collimator was used with the data acquired in 256 × 256 format. The energy window was set from 5% below to 10% above the ^{99m}Tc photopeak. Imaging was performed at 4 hr postinjection. An anterior view of the thighs and a posterior view of the calves and knees were obtained. Imaging was performed for 10 min per image with 382K counts (s.e.m. ± 18K) obtained in the thigh image and 187K counts (s.e.m. ± 10k) in the calf. All scans were viewed by two nuclear medicine physicians and graded by consensus. The readers were blinded to the results of contrast venography. Images were viewed on video monitor using an interactive gray-scale threshold. The positive criteria were as follows:

1. Femoral vein: increased tracer accumulation in comparison with the contralateral side.
2. Calf veins: increased tracer accumulation in the deep veins in comparison with the contralateral side.
3. Popliteal vein: increased tracer accumulation in comparison with the contralateral side in a patient with co-existing calf or femoral thrombosis.

Using these criteria, thrombosis involving the popliteal vein can only be diagnosed in the setting of thrombosis involving either calf veins or proximal veins or both. The popliteal vein is very superficial when imaged posteriorly and always appears to have increased tracer accumulation as compared to the adjacent calf veins. It was considered that minor dilatation of the popliteal vein induced by knee surgery could result in false-positive results. In

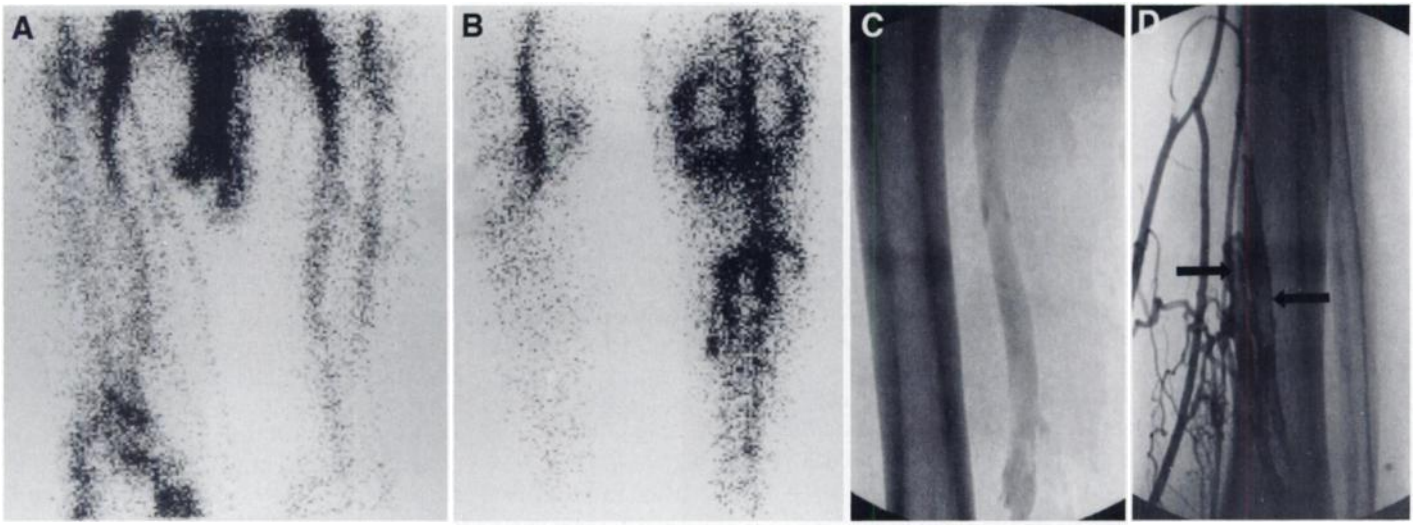

FIGURE 1. (A) Anterior thigh image demonstrating symmetrical tracer accumulation in femoral veins. Uptake of tracer surrounding the right total knee replacement is prominent. (B) Posterior calf scan demonstrating marked accumulation of tracer in the right midcalf region. Minimal tracer uptake is seen in the contralateral calf. (C) Normal contrast venogram of right femoral vein in same patient. (D) Contrast venogram of right calf veins demonstrating thrombosis involving the deep veins of the calf (arrows).

previous work (*10*), uptake in the femoral vein was compared to that of the bone marrow. That was not feasible in this group of patients, as bone marrow distribution has been altered due to the recent hip surgery. Uptake of tracer into the bone marrow does not interfere with scan interpretation as the femoral vein lies medial to the femur.

Disagreement between Venography and Scanning

After the initial analysis, all venograms and scans that did not agree were reviewed in an attempt to understand the limitations of the scanning technique.

RESULTS

Contrast Venography

Eighty-four segments were of diagnostic quality with 22 segments being uninterpretable and excluded from the analysis. The uninterpretable segments were due to inadequate filling of the calf veins in 10 segments, inadequate filling of the proximal veins in 11 segments and disagreement between observers in one case in the calf veins. Thromboses were seen in 15 segments (1 proximal, 14 distal) and no thrombosis was identified in 69 segments. In those patients with diagnostic contrast venography, DVT was detected in 13% of total hip replacement patients and in 65% of total knee replacement patients.

Scintigraphic Imaging

All scans were considered to be of diagnostic quality. Typical scans and corresponding contrast venograms are depicted in Figures 1 and 2. Of the 15 thrombosed segments, 14 had positive scans; in the 69 nonthrombosed segments, 63 had negative scans. One thrombosed segment had a negative scan; 6 nonthrombosed segments had positive scans. Thus, scintigraphic scanning with ^{99m}Tc-rt-PA had a sensitivity of 93% and a specificity of 91%. Twenty-two segments were uninterpretable on contrast venography. In these segments, ^{99m}Tc-rt-PA scanning was positive in four segments and negative in 18 segments. The usual reason for the uninterpretable contrast venograms is inadequate filling of the veins. If it is assumed that these venograms are most likely negative for thrombosis, then

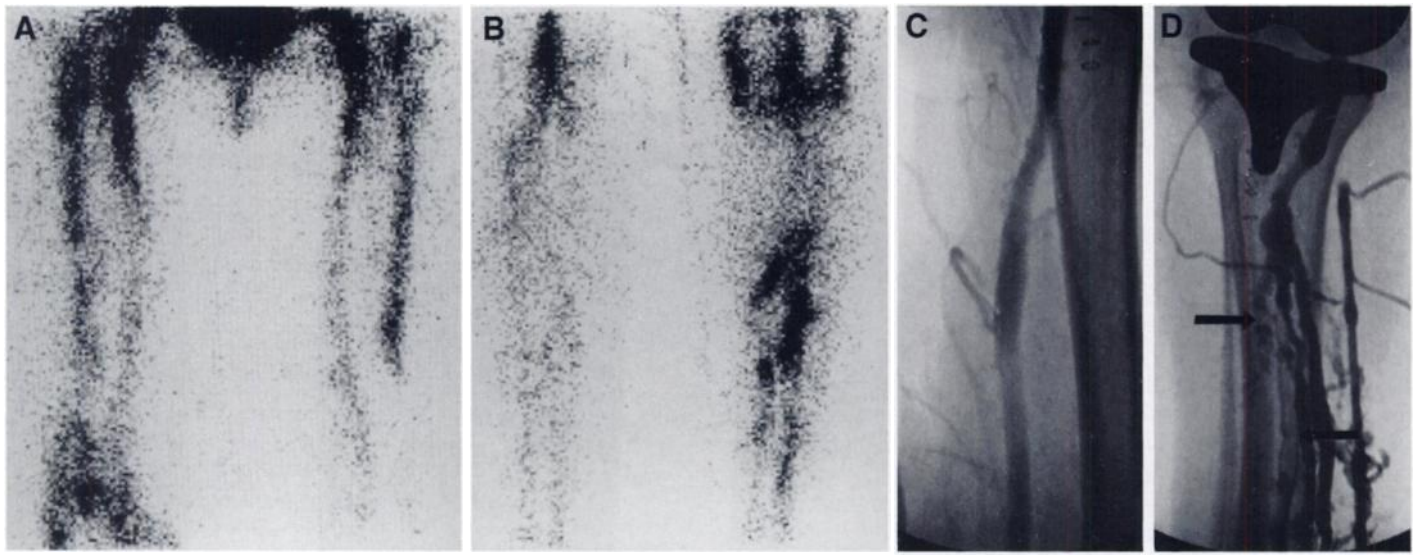

FIGURE 2. (A) Anterior thigh image demonstrating symmetrical tracer accumulation in femoral veins. Uptake of tracer surrounding the right total knee replacement and in the bone marrow of the femoral shafts is prominent. (B) Posterior calf scan demonstrating marked accumulation of tracer in the right midcalf region. Minimal tracer uptake is seen in the contralateral calf. (C) Normal contrast venogram of right femoral vein in same patient. (D) Contrast venogram of right calf veins demonstrating thrombosis involving the deep veins of the calf (arrows).

^{99m}Tc-rt-PA scanning in these cases was correct in 18 of 22. If these venograms are included in the analysis, ^{99m}Tc-rt-PA has a sensitivity of 92% and a specificity of 89% in detecting DVT.

Disagreement between Venography and Scanning

One patient had a positive contrast venogram with a negative ^{99m}Tc-rt-PA scan. This patient had undergone a total hip replacement 8 days previously with the contrast venogram demonstrating a 4- to 5-cm nonocclusive thrombus in the mid femoral vein with no proximal or distal extension. Six patients had a negative contrast venogram with positive ^{99m}Tc-rt-PA scans. Upon review, three venograms were considered to be equivocal as there was inadequate filling of the calf veins at the location of the positive uptake on ^{99m}Tc-rt-PA scan. In the remaining three cases, one case showed very mild abnormal ^{99m}Tc rt-PA accumulation in the calf and in the other two, no definite explanation could be found to explain the differences.

DISCUSSION

The numerous techniques that have been developed to detect postoperative DVT testify to the difficulty of the task and the limitations of all these modalities. Iodine-125 fibrinogen leg scanning was originally introduced in the 1970s (*12*), and initial studies demonstrated a high accuracy in DVT detection (*13–15*). Subsequent studies, however, have failed to confirm these initial studies, and the test is not widely used. Lensing et al. (*16*) recently reviewed the accuracy of ^{125}I-fibrinogen leg scanning in postoperative patients. In six well-designed studies in postoperative orthopedic patients, 2484 legs were examined by both ^{125}I-fibrinogen scanning and contrast venography. Iodine-125-fibrinogen scanning had a sensitivity of 45% and a specificity of 92%, and the authors conclude that this technique has serious limitations in thrombosis detection in the asymptomatic patient.

Impedance plethysmography, either alone or in combination with other noninvasive modalities, has been investigated in the assessment of DVT in the postoperative patient. Cruickshank et al. (*17*) demonstrated a sensitivity of 13% and a specificity of 95% with this technique in more than 1000 patients after hip surgery with other studies confirming their results (*18–19*).

Initial studies of compression ultrasound in DVT detection in asymptomatic patients demonstrated an acceptable level of accuracy (*20–21*), but more recent studies have failed to confirm this initial promise. Comerota et al. (*22*) reviewed nine studies involving over 1000 asymptomatic patients. The sensitivity in detecting proximal DVT was 78% while detecting calf vein thrombosis was only 29%. A more recent study (*9*) in patients undergoing hip or knee replacement demonstrated a sensitivity of 38% and a specificity of 92% in the detection of proximal vein thrombosis. If calf vein thrombosis was included in the analysis, the sensitivity dropped to 20%. It has been concluded that compression ultrasound has marked limitations in the screening of asymptomatic patients, and its use in these patients is not recommended (*23–24*).

In this study, ^{99m}Tc-rt-PA scanning shows a high level of sensitivity and specificity in the detection of DVT. In this study, 14 of 15 of the thrombi detected on venography were isolated in the calf veins. This localization is not unusual in this group of patients and is best explained by the prophylaxis employed in this patient group and the operations performed (*6*). All patients were receiving heparin prophylaxis, and all patients wore compression elastic stockings. Furthermore, all patients were mobilized early after their surgery. The only case of DVT involving the proximal veins was not detected on ^{99m}Tc-rt-PA scanning, as discussed above. In previous work (*10*), accuracy in the detection of proximal DVT was very high.

The clinical significance of postoperative thrombi, particularly isolated calf thrombi, is somewhat unclear. It has been shown that patients with asymptomatic calf thrombi develop both symptomatic and asymptomatic pulmonary emboli (*6*) and that these pulmonary emboli can be fatal (*25*). From our knowledge of symptomatic calf thrombosis, isolated calf thrombosis propagates into the popliteal vein and femoral veins in 12%–20% of cases if left untreated (*26–28*). It has also been shown in symptomatic patients that if isolated calf vein thrombosis is left untreated, there is a 29% recurrence rate at 3 mo as compared to zero recurrence if treated (*29*). Several authors consider that treatment of these thrombi is justified in the majority of patients (*22*); or, if not treated, the patient is closely monitored to detect thrombus propagation (*6*).

One of the possible limitations of this technique is that bilateral DVT may be difficult to detect. As asymmetry is the criterion for a positive scan, bilateral DVT may not be detected. The true incidence of post operative bilateral DVT is unknown as it is difficult to perform bilateral contrast venography on asymptomatic patients. Larger studies will need to be performed to ascertain if this theoretical limitation has any clinical implications.

This study demonstrates that scintigraphic scanning with ^{99m}Tc-rt-PA is accurate in the detection of DVT in patients undergoing total hip or knee arthroplasty. This technique may prove valuable in the monitoring of high-risk patients and also in the evaluation of prophylaxis trials aimed to prevent DVT developing.

ACKNOWLEDGMENTS

We thank Drs. I. Lovett and P. Travers for their assistance with the contrast venography interpretation.

REFERENCES

1. Collins R, Scrimgeour A, Yusuf S, Peto R. Reduction in fatal pulmonary embolism and venous thrombosis by perioperative administration of subcutaneous heparin. *N Engl J Med* 1988;318:1162–1173.
2. Hull R, Raskob G, Pineo G, Rosenbloom D, Evans W, Mallory T. A comparison of subcutaneous low molecular weight heparin with warfarin sodium for prophylaxis against deep vein thrombosis after hip or knee implantation. *N Engl J Med* 1993;329:1370–1376.
3. Clagett GP, Anderson FA, Levine MN, Salzman EW, Wheeler HB. Prevention of venous thromboembolism. *Chest* 1992;102:391S–407S.
4. Stringer MD, Steadman CA, Hedges AR, Thomas EM, Morley TR, Kakkar VV. Deep vein thrombosis after elective knee surgery. *J Bone Joint Surg* 1989;71-B:492–497.
5. Stulberg BN, Insall JN, Williams GW, Ghelman B. Deep vein thrombosis following total knee replacement: an analysis of 638 arthroplasties. *J Bone Joint Surg* 1984;66-A:194–201.
6. Haas SB, Tribus CB, Insall JN, Becker MW, Windsor RE. The significance of calf thrombi after total knee arthroplasty. *J Bone Joint Surg Br* 1992;74:799–802.
7. Leclerc JR, Geerts WH, Desjardins L, et al. Prevention of venous thromboembolism after knee arthroplasty—a randomized double blind trial comparing enoxaparin to warfarin sodium. *Chest* 1994;106:48S.
8. Salzman EW. Venous thrombosis made easy. *N Engl J Med* 1987;314:847–848.
9. Davidson BL, Elliot CG, Lensing AWA, et al. Low accuracy of color doppler ultrasound in the detection of proximal leg vein thrombosis in asymptomatic high risk patients. *Ann Int Med* 1992;117:735–738.
10. Butler S, Boyd S, Parkes S, Quinn R. Results of Phase III trial of ^{99m}Tc-modified recombinant tissue plasminogen activator for the detection of DVT. *J Nucl Med* 1996; 37:744–748.
11. Rabinov K, Paulin S. Roentgen diagnosis of venous thrombosis in the leg. *Arch Surg* 1972;104:134–144.
12. Kakkar VV. Fibrinogen uptake test for the detection of deep vein thrombosis—a review of current practice. *Semin Nucl Med* 1977;7:229–244.
13. Kakkar VV. The diagnosis of DVT using the I-125-lableled fibrinogen test. *Arch Surg* 1972;104:152–159.
14. Kakkar VV. Deep venous thrombosis. *Detec Preven Circ* 1975;51:8–19.
15. Lambie JM, Mahaffy RG, Barber DC, Karmody AM, Scott MM, Matheson NA. Diagnostic accuracy in venous thrombosis. *Br Med J* 1970;2:142–143.
16. Lensing AW, Hirsh J. Iodine-125-fibrinogen leg scanning: re-assessment of its role for the diagnosis of venous thrombosis in postoperative patients. *Thromb Haemost* 1993;69:2–7.
17. Cruickshank MK, Levine MN, Hirsh J, et al. An evaluation of impedance plethysmography and ^{125}I fibrinogen leg scanning in patients following hip surgery. *Throm Haemos* 1989;62:830–834.
18. Ginsberg J, Wells P, Hirsh J, et al. Re-evaluation of the sensitivity of impedance

plethysmography for the detection of proximal deep vein thrombosis. *Arch Intern Med* 1994;154:1930–1933.
19. Paiement G, Wessinger SJ, Waltman AC, Harris WH. Surveillance of deep vein thrombosis in asymptomatic total hip replacement patients. *Am J Surg* 1988;155:400–404.
20. Raghavendra BN, Rosen RJ, Lam S. Deep venous thrombosis detection by high resolution real-time ultrasonography. *Radiology* 1984;152:789–793.
21. Appleman PT, de Jong TT, Lampman LE. Deep venous thrombosis of the leg: US findings. *Radiology* 1987;163:743–746.
22. Comerota AJ, Katz ML, Hashemi HA. Venous duplex imaging for the diagnosis of acute deep venous thrombosis. *Haemostasis* 1993;23(supp 1):61–71.
23. Jongbloets LMM, Lensing AWA, Koopman MMW, Buller HR, ten Cate JW. Limitations of compression ultrasound for the detection of symptomless postoperative deep venous thrombosis. *Lancet* 1994;343:1142–1144.
24. Wells P, Lensing A, Davidson B, Prins M, Hirsh J. Accuracy of ultrasound for the diagnosis of deep venous thrombosis in asymptomatic patients after orthopedic surgery. *Ann Intern Med* 1995;122:47–53.
25. Pellegrini VD, Rancis CW, Harris C, Totterman S. Embolic complications of calf vein thrombosis following total hip arthroplasty. *J Arthroplasty* 1993;8:449–457.
26. Kakkar VV, Howe CT, Flanc C, Clarke MB. Natural history of postoperative deep vein thrombosis. *Lancet* 1969;2:230–232.
27. Lohr JM, Kerr TM, Lutter KS, Cranley RD, Spirtoff K, Cranley JJ. Lower extremity calf thrombosis: to treat or not to treat? *J Vasc Surg* 1991;14:618–623.
28. Maynard MJ, Sculco TP, Ghelman B. Progression and regression of deep vein thrombosis after total knee arthroplasty. *Clin Orthop* 1991;273:125–130.
29. Lagerstedt CI, Ollsson CG, Fagher BO, Oqvist BW, Albrechtsson U. Need for long-term anticoagulant treatment in symptomatic calf vein thrombosis. *Lancet* 1985;7:515–518.

The Role of Thallium-201 Uptake and Retention in Intracranial Tumors After Radiotherapy

Mordechai Lorberboym, Lynda R. Mandell, Roger E. Mosesson, Isabelle Germano, Wendy Lou, Maria DaCosta, Debra G. Linzer and Josef Machac

Division of Nuclear Medicine, Department of Radiology and Departments of Radiation Oncology, Diagnostic Radiology, Neurosurgery and Biomathematical Sciences, Mount Sinai School of Medicine, City University of New York, New York

This study prospectively assessed the diagnostic accuracy and prognostic value of ^{201}Tl uptake and retention in primary and metastatic intracranial tumors treated by conventional radiotherapy and/or radiosurgery. **Methods:** An initial ^{201}Tl study (early and delayed images), was obtained in 60 postsurgical patients, 6–12 wk after radiotherapy or radiosurgery. Repeat imaging was performed as clinically warranted. Tumor-to-background count ratios and a retention index (RI) were calculated for all lesions. **Results:** Abnormally increased ^{201}Tl uptake was observed in 40 of 60 patients. In all patients with positive results, the diagnosis of residual tumor was confirmed at biopsy or by clinical follow-up. In 20 of 60 patients, no abnormal ^{201}Tl uptake was observed, despite findings on CT and/or MRI scans that were suspicious for tumor. Ten of the negative ^{201}Tl studies were confirmed as true-negatives by the clinical course and by resolution of CT/MRI abnormalities. The remaining 10 negative SPECT studies ultimately proved to be false-negatives: six of these patients had lesions <1 cm in maximum diameter; one patient had a large metastatic choriocarcinoma; and three patients had low-grade astrocytomas >2 cm in minimum diameter. Tumor-to-background ratio of ^{201}Tl uptake did not distinguish between tumor type, or predict clinical outcome. The RI of ^{201}Tl was significantly higher for metastatic melanoma than for other tumor metastases. It demonstrated reasonably good correlation with clinical outcome: 6/7 patients with eventual tumor regression showed a decrease in RI on follow-up examination, and 4/5 patients with eventual tumor progression had an increase in RI. **Conclusion:** Thallium-201 brain SPECT appears to be a useful noninvasive imaging technique in patients irradiated for intracranial tumors. Thallium-201 scintigraphy has very high specificity (100% in this cohort) for detecting viable residual tumor. False-negative findings may occur. Quantitative analysis of ^{201}Tl uptake has limited diagnostic and prognostic significance, but changes in ^{201}Tl retention after radiation therapy seems to have prognostic value.

Key Words: thallium-201; intracranial tumors; radiation therapy; retention index

J Nucl Med 1997; 38:223–226

Received Feb. 15, 1996; revision accepted June 15, 1996.

For correspondence or reprints contact: Mordechai Lorberboym, MD, Division of Nuclear Medicine, Mount Sinai Medical Center, Box 1141, New York, NY 10029.

Experience of past decades has established that radiation therapy is an effective adjunct to surgery in the treatment of intracranial tumors (*1,2*). More recently, stereotactically guided radiotherapy (radiosurgery) has been used alone and in combination with surgery for aggressive treatment of a variety of adult and pediatric intracranial malignancies, primary and metastatic (*3,4*). Radiosurgery and conventional radiation therapy may induce severe parenchymal changes that are clinically indistinguishable from changes induced by tumor growth (*5–8*).

CT and MRI are sensitive but not specific in evaluating tumor response to radiation therapy (*9*). Although even very small lesions are detected by these imaging modalities, any single postradiation abnormality on MRI or CT may be viable tumor or may represent radiation-induced necrosis or gliosis. Since these alternatives cannot be differentiated by clinical criteria, tissue biopsy has often been necessary for definitive evaluation (*10*).

Because ^{201}Tl, a potassium analog, is taken up by viable tumor cells but not by necrotic tissue or nonproliferating glial cells (*11*), brain imaging with this radionuclide has been introduced as a noninvasive method of improving the specificity of CT and MRI. Several reports have shown that if brain SPECT is performed after ^{201}Tl administration, the radiotracer localizes in tumor with a clinically useful target-to-background ratio, apparently in proportion to the rate of neoplasm cell growth (*9,11,12*). Furthermore, the ^{201}Tl retention has been reported to be a reliable quantitative parameter for predicting tumor type and grade (*13,14*).

This prospective study evaluates the diagnostic accuracy and prognostic value of ^{201}Tl brain SPECT for irradiated primary and metastatic intracranial tumors in a large cohort of patients. Scintigraphic images were evaluated visually and analyzed quantitatively. Long-term follow-up is available for all patients.

MATERIALS AND METHODS

Patients

From November 1993 to November 1995, 60 consecutive patients with pathologically defined primary and metastatic intra-