

- immunoglobulin and technetium-99m monoclonal antibodies for imaging chronic osteomyelitis. *Eur J Nucl Med* 1991;18:401-407.
12. Bosslet K, Lüben G, Schwarz A, et al. Immunohistochemical localization and molecular characteristics of three monoclonal antibody-defined epitopes detectable on carcinoembryonic antigen (CEA). *Int J Cancer* 1985;33:643.
  13. Otte P, Schlegel KF. Aktuelle orthopädie, Behandlung der sekundär-chronischen osteomyelitis. Stuttgart, Germany: Ferdinand Enke Verlag; 1872;1-18.
  14. Jacobson AF, Gilles CP, Cerqueira MD. Photopenic defects in marrow-containing skeleton on indium-111 leukocyte scintigraphy: prevalence at sites suspected of osteomyelitis and as an incidental finding. *Eur J Nucl Med* 1992;19:858-864.
  15. Becker W, Bair J, Behr T, et al. Detection of soft-tissue infections and osteomyelitis using a technetium-99m-labeled antigranulocyte monoclonal antibody fragment. *J Nucl Med* 1994;35:1436-1443.
  16. Serafini AN. From monoclonal antibodies to peptides and molecular recognition units: an overview. *J Nucl Med* 1993;34:533-536.

## Changes in Results of Gallium-67-Citrate Scanning after Interferon Therapy for Chronic Hepatitis C

Susumu Shiomi, Tetsuo Kuroki, Tadashi Yokogawa, Tadashi Takeda, Shuhei Nishiguchi, Shinya Nakajima, Takashi Tanaka, Terue Okamura and Hironobu Ochi

Third Department of Internal Medicine, Department of Public Health and Division of Nuclear Medicine, Osaka City University Medical School, Osaka, Japan

Gallium-67 scanning is useful for early diagnosis and grading of interstitial lung disease. In a study of the side effects of interferon (IFN) on the lungs of patients with chronic hepatitis C, we performed  $^{67}\text{Ga}$  scanning before and after IFN therapy. **Methods:** The 66 subjects who underwent at least one scanning, before IFN therapy, were 8 patients with chronic persistent hepatitis (CPH), 21 with chronic aggressive hepatitis 2A (CAH-2A), 25 with chronic aggressive hepatitis 2B (CAH-2B) and 12 with cirrhosis. All had underlying hepatitis C viral infection. Of those patients, 20 were examined again within 1 mo after IFN therapy. Patients received an intravenous injection of 340 MBq  $^{67}\text{Ga}$ -citrate and were imaged 72 hr later. ROIs were established for anterior views of the lungs (Lu), liver (Li) and soft tissue of the upper arm as background (B). The counts per unit size of each region of interest were used in calculation of the ratios Lu/B and Li/B. **Results:** The medians of Lu/B were 2.46 in CPH, 2.56 in CAH-2A, 2.50 in CAH-2B and 2.47 in cirrhosis. These differences were not statistically significant. The medians of Li/B were 6.42 in CPH, 6.14 in CAH-2A, 5.11 in CAH-2B and 4.03 in cirrhosis. The differences between the median Li/B of cirrhotic patients and the medians for patients with CPH, CAH-2A and CAH-2B were significant. After therapy, Lu/B was higher than before in 16 of the 20 patients and lower in the four other patients; the overall rise was significant (Wilcoxon rank-sum test). Li/B was higher than before in 11 of the 20 patients and lower in the nine other patients. **Conclusion:** IFN caused uptake of the radionuclide to increase in most patients. This method showed changes in the accumulation of  $^{67}\text{Ga}$ -citrate that could have been missed if the results had been inspected by eye. IFN can cause interstitial lung disease, but unlike other drugs with this side effect, the onset seems to be gradual enough to be detected quantitatively by  $^{67}\text{Ga}$  scanning.

**Key Words:** gallium-67-citrate; interferon-alpha; hepatitis C; interstitial lung disease

*J Nucl Med* 1997; 38:216-219

Chronic hepatitis B is often treated with interferon (IFN) (1), which can cause such side effects as fever of 38°C or more, influenza-like symptoms, thrombocytopenia, leukocytopenia, proteinuria and alopecia (2). Administration is long term when infection is with the hepatitis C virus (3), and further side effects may appear. The most troublesome are autoimmune thyroid disease (4-6), autoimmune hepatitis (7,8), worsening

of diabetes mellitus (9,10), psychiatric disorders (11,12) and interstitial lung disease (13-17). Interstitial lung disease, in particular, has a poor prognosis, and early diagnosis and treatment are needed. Gallium-67 scanning is generally useful for the early diagnosis of interstitial lung disease (18). It might be improved by being made quantitative rather than qualitative. To identify the effect of IFN on the lungs, we performed  $^{67}\text{Ga}$  scanning in patients with chronic hepatitis C before and after IFN therapy, with quantitative results used to monitor responses and, in some cases, to exclude patients from IFN therapy when uptake in the first scanning was unusually high.

### MATERIALS AND METHODS

#### Patients

Sixty-six patients with underlying hepatitis C viral infection underwent at least one scanning (before IFN therapy). Thirty-six patients were men and 30 were women; the mean age was 50 yr (range 21-67 yr). Chronic hepatitis C was diagnosed by the detection of antibodies to hepatitis C virus. Diagnoses of the liver condition were based on histological examination of liver specimens obtained by laparoscopy or needle biopsy done under ultrasonic guidance between April 1993 and August 1995. Results of the histological examination, which was done by internationally established criteria (19), showed that there were eight patients with chronic persistent hepatitis (CPH), 21 patients with chronic aggressive hepatitis 2A (CAH-2A) with moderate piecemeal necrosis and inflammation (20), 25 patients with chronic aggressive hepatitis 2B in which these two signs were severe (CAH-2B) and 12 patients with cirrhosis of the liver. The  $^{67}\text{Ga}$  scanning before therapy was done within 1 wk of liver biopsy. All patients were asked and 20 patients agreed to return as outpatients to be examined a second time within 1 mo of the end of IFN therapy. We classified all patients into three categories according to their changes in alanine aminotransferase (ALT) activity with IFN therapy. Responders were those in whom ALT activity at the end of IFN therapy was normal. Partial responders were those in whom ALT activity had decreased but not to the normal level by the end of IFN therapy. Nonresponders were those in whom ALT activity had not decreased by the end of IFN therapy. The clinical background of patients scanned twice and their responses to IFN therapy are shown in Table 1.

Received Jan. 9, 1996; revision accepted June 15, 1996.

For correspondence or reprints contact: Susumu Shiomi, MD, Third Department of Internal Medicine, Osaka City University Medical School, 1-5-7 Asahimachi, Abeno-ku, Osaka 545, Japan.

**TABLE 1**  
Background and Results for Patients with Chronic Hepatitis C

Patient no.	Diagnosis	Sex	Age (yr)	Interferon	Duration (wk)	Total dose (MIU)	Response
1	CPH	Male	30	$\alpha$ -2b	14	480	NR
2	CPH	Female	39	$\alpha$ -2b	14	288	NR
3	CPH	Female	40	$\alpha$ -2b	24	210	NR
4	CPH	Male	44	$\alpha$ -2a	14	180	NR
5	CPH	Male	57	natural- $\alpha$	24	390	R
6	CAH-2A	Male	53	natural- $\alpha$	24	468	NR
7	CAH-2A	Female	21	natural- $\alpha$	24	468	PR
8	CAH-2A	Female	26	$\alpha$ -2b	16	610	R
9	CAH-2A	Male	29	$\alpha$ -2a	24	792	R
10	CAH-2A	Male	54	$\alpha$ -2a	24	792	R
11	CAH-2A	Female	57	natural- $\alpha$	16	324	R
12	CAH-2B	Female	48	natural- $\alpha$	24	528	NR
13	CAH-2B	Female	54	$\alpha$ -2b	16	396	PR
14	CAH-2B	Female	58	natural- $\alpha$	24	474	PR
15	CAH-2B	Female	62	$\alpha$ -2a	24	792	PR
16	CAH-2B	Female	67	$\alpha$ -2a	20	531	PR
17	CAH-2B	Male	51	$\alpha$ -2a	24	792	R
18	Cirrhosis	Male	42	natural- $\alpha$	24	360	PR
19	Cirrhosis	Male	62	natural- $\alpha$	24	552	PR
20	Cirrhosis	Male	52	$\alpha$ -2a	24	693	R

CPH = chronic persistent hepatitis; CAH = chronic aggressive hepatitis; R = responder; PR = partial responder; NR = nonresponder.

### Scintigraphy

Patients received an intravenous injection of 340 MBq of  $^{67}\text{Ga}$ -citrate, and both anterior and posterior views of the thorax were taken 72 hr later with a gamma camera (Sopha Medical DSX, Paris, France) fitted with a medium-energy collimator. The pulse-height analyzer was set for 93-, 184- and 296-keV photopeaks. Anterior views, in which one view comprised 800,000 counts, were analyzed.

The collected data were processed by computer and shown on a color display. ROIs were established for the anterior views of the lungs (Lu), liver (Li) and soft tissue of the upper arm as background (B). The counts per unit size of each ROI were used in calculations of the ratio of the lung count to the background count (Lu/B) and the ratio of the liver count to the background count (Li/B).

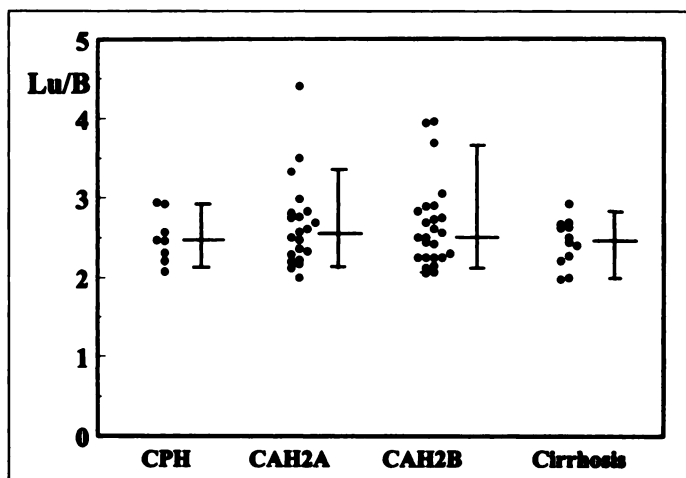
### Statistical analysis

Results are expressed as medians with tenth and 90th percentiles. The significance of differences between medians was evaluated by the Mann-Whitney U-test (two-tailed). The changes in Lu/B and Li/B after IFN therapy were evaluated with the Wilcoxon rank-sum test (two-tailed). For both tests, differences with probability values of less than 0.05 were considered to be statistically significant.

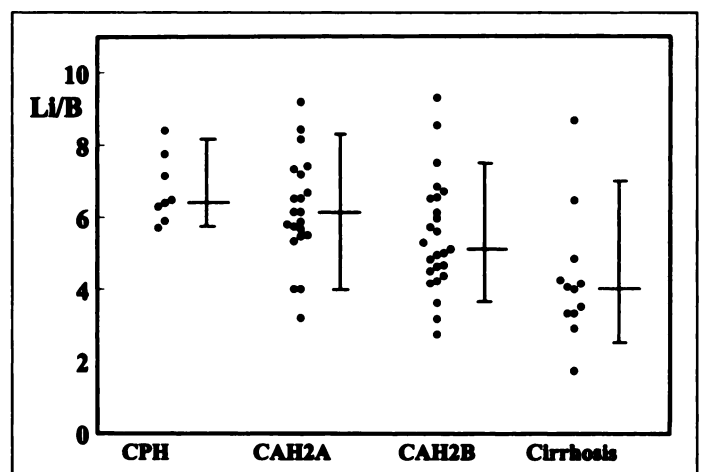
### RESULTS

#### Lung and Liver Uptake of Gallium-67-Citrate in Chronic Liver Diseases

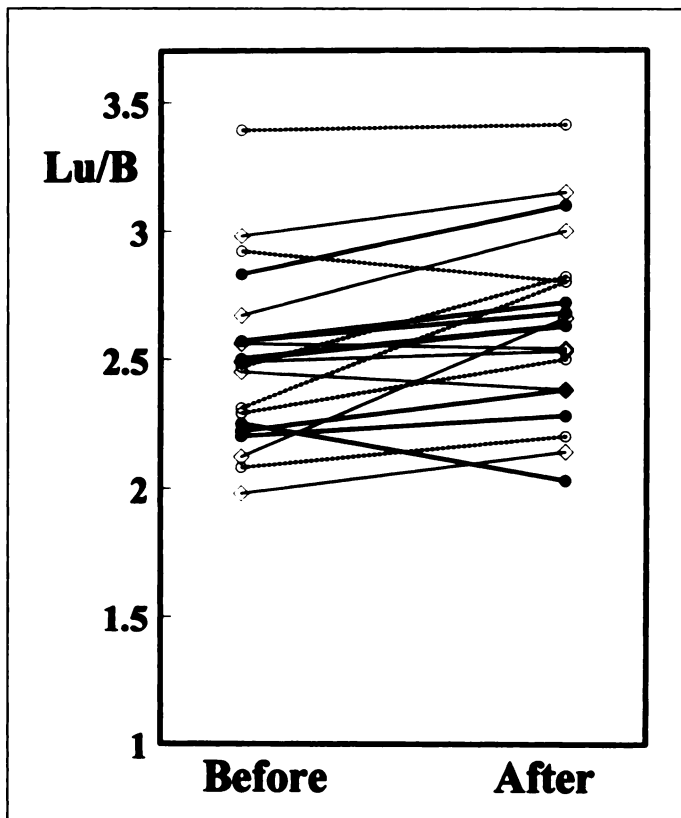
The medians (tenth and 90th percentiles) of Lu/B were 2.46 (2.12, 2.93) in CPH, 2.56 (2.15, 3.39) in CAH-2A, 2.50 (2.12, 3.69) in CAH-2B and 2.47 (2.00, 2.74) in cirrhosis of the liver



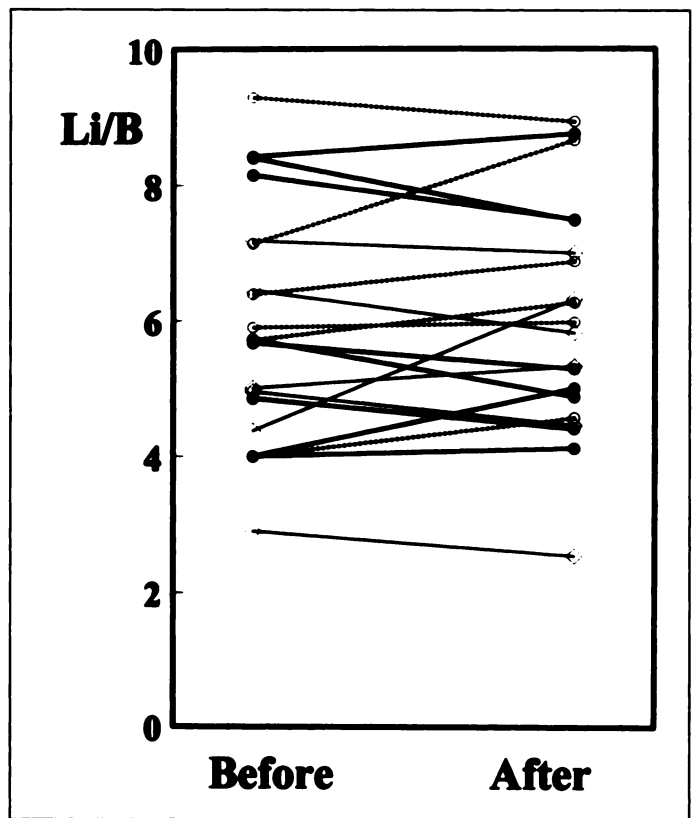
**FIGURE 1.** Lu/B in patients with chronic liver diseases examined before IFN therapy. Horizontal lines on the bars show the tenth percentile, median and 90th percentile, from bottom to top. CPH = chronic persistent hepatitis; CAH = chronic aggressive hepatitis. The differences among these groups were not statistically significant.



**FIGURE 2.** Li/B in patients with chronic liver diseases examined before IFN therapy. Horizontal lines on the bars show the tenth percentile, median and 90th percentile, from bottom to top. The differences between the median Li/B of cirrhotic patients and patients with CPH ( $p = 0.0054$ ), CAH-2A ( $p = 0.0040$ ) and CAH-2B ( $p = 0.0124$ ) were significant.



**FIGURE 3.** Changes in Lu/B with interferon therapy. The Lu/B after interferon therapy was significantly higher than that before therapy ( $p = 0.0024$ ). ● = responder; ◇ = partial responder; ○ = nonresponder.



**FIGURE 4.** Changes in Li/B with IFN therapy. The Li/B before and after IFN therapy were not significantly different ( $p = 0.9405$ ). ● = responder; ◇ = partial responder; ○ = nonresponder.

(Fig. 1). The differences among these groups were not significant.

The medians (tenth and 90th percentiles) of Li/B were 6.42 (5.77, 8.20) in CPH, 6.14 (4.00, 8.25) in CAH-2A, 5.11 (3.62, 7.50) in CAH-2B and 4.03 (2.62, 7.00) in cirrhosis of the liver (Fig. 2). The differences between the median Li/B of cirrhotic patients and the medians for patients with CPH, CAH-2A and CAH-2B were significant.

#### Changes in Lung and Liver Uptake of Gallium-67-Citrate with IFN Therapy

Figure 3 shows changes in Lu/B with IFN therapy. Lu/B increased in 16 of the 20 patients; it decreased in the other four patients. By the Wilcoxon rank-sum test, the overall increase was significant ( $p < 0.01$ ).

Figure 4 shows changes in Li/B with IFN therapy. Li/B increased in 11 of the 20 patients; it decreased in the other nine patients. The Wilcoxon rank-sum test showed no significant change.

#### DISCUSSION

Gallium-67-citrate couples to transferrin and lactoferrin in the blood and circulates through the body in the bloodstream to accumulate at inflammatory sites where it is taken into macrophages and neutrophils (21). We found significantly less accumulation in the liver in patients with cirrhosis than in patients with chronic hepatitis. This decrease is correlated with the decreased liver blood flow in cirrhosis, so Li/B could be an index of hepatic functional reserve. The counts per unit size of liver scans did not show enough improvement in hepatic functional reserve with IFN therapy to produce the increased  $^{67}\text{Ga}$ -citrate uptake observed after the therapy. Nishiguchi et al. (22) noticed improved hepatic functional reserve in cirrhosis

after IFN therapy, but the improvement occurred a few years later and not during therapy.

Alveolar inflammation is probably an early manifestation of idiopathic pulmonary fibrosis. Physiologic methods (coefficient of retraction and exercise tests of  $\Delta\text{Po}_2/\Delta\text{Vo}_2$ ) can detect the progress of fibrosis, but it is difficult to evaluate alveolar inflammation in this disease without repeated lung biopsies. Gallium-67 scanning might be used to monitor the alveolitis of idiopathic pulmonary fibrosis because this isotope accumulates in regions of inflammation (23,24). Gallium-67-citrate is used to detect and characterize the inflammation of idiopathic pulmonary fibrosis because it binds to neutrophils [probably in lysosomes (25)], which are found in the parenchyma in this condition. Line et al. (26) reported that  $^{67}\text{Ga}$  scanning is useful not only for diagnosis but also for identification of the stage of the activity of this disease.

Drugs both cytotoxic (27) and not (28) can cause pulmonary disease. Cytotoxic drugs include anticancer drugs, and noncytotoxic drugs include antibacterial agents. IFN seems to have a different mechanism of action from either of these groups of drugs. We found a significant rise in  $^{67}\text{Ga}$ -citrate uptake into the lung after administration of IFN. This cytokine may trigger an excessive immune response, causing interstitial lung disease. (The unexpected decrease in uptake by four of the 20 patients might have occurred because of long-term fever and anorexia, both side effects of IFN therapy, causing decreased immune response.) Roth and Frank (29) reported the induction of acute interstitial pneumonia in cattle by a subcutaneous injection of bovine IFN- $\gamma$ . Interstitial lung disease did not develop in the subjects of this study. IFN treatment was not started in two patients (with two of the four highest values in Fig. 1) because we noticed much accumulation of  $^{67}\text{Ga}$ -citrate in their lungs in the preliminary scanning and exercise tests of  $\Delta\text{Po}_2/\Delta\text{Vo}_2$

suggested interstitial lung disease. Probably these two patients were at special risk of developing interstitial lung disease. Ueda et al. (30) detected antibodies to hepatitis C virus in 19 of 66 patients (29%) with interstitial lung disease, the incidence being significantly higher than that in 9464 apparently healthy volunteers (346, or 4%, had such antibodies), and they suggested that hepatitis C virus might be implicated in this lung disease. If so, there being several patients before IFN therapy with unusually high Lu/B may be accounted for.

## CONCLUSION

Changes in the accumulation of  $^{67}\text{Ga}$ -citrate were measured by calculation of the count per unit size in the ROI. Such changes could not have been inspected visually. This technique made numerical evaluation of the accumulation possible, so it seemed useful for the early diagnosis of interstitial lung disease caused by IFN and other drugs. Patients given IFN for treatment of liver disease had increased uptake of the radionuclide in their lungs, showing an increased immune response that might in some patients lead to interstitial lung disease.

## REFERENCES

1. Hoofnagle JH, Peters M, Mullen KD, et al. Randomized, controlled trial of recombinant human  $\alpha$ -interferon in patients with chronic hepatitis B. *Gastroenterology* 1988;95:1318-1325.
2. Di Bisceglie AM, Martin P, Kassianides C, et al. Recombinant interferon alfa therapy for chronic hepatitis C: a randomized, double-blind, placebo-controlled trial. *N Engl J Med* 1989;321:1506-1510.
3. Schultz M, Müller R, von zur Mühlen A, Brabant G. Induction of hyperthyroidism by interferon- $\alpha$ -2b. *Lancet* 1989;1:1452.
4. Chung Y-H, Shong YK. Development of thyroid autoimmunity after administration of recombinant human interferon- $\alpha$ -2b for chronic viral hepatitis. *Am J Gastroenterol* 1993;88:244-247.
5. Mayet W-J, Hess G, Gerken G, et al. Treatment of chronic type B hepatitis with recombinant  $\alpha$ -interferon induces autoantibodies not specific for autoimmune chronic hepatitis. *Hepatology* 1989;10:24-28.
6. Silva MO, Reddy KR, Jeffers LJ, Hill M, Schiff ER. Interferon-induced chronic active hepatitis? *Gastroenterology* 1991;101:840-842.
7. Koivisto VA, Pelkonen R, Cantell K. Effect of interferon on glucose tolerance and insulin sensitivity. *Diabetes* 1989;38:641-647.
8. Fabris P, Betterle C, Floreani A, et al. Development of type 1 diabetes mellitus during interferon alfa therapy for chronic HCV hepatitis. *Lancet* 1992;340:548.
9. Renault PF, Hoofnagle JH, Park Y, et al. Psychiatric complications of long-term interferon alfa therapy. *Arch Intern Med* 1987;147:1577-1580.
10. Meyers CA, Scheibel RS, Forman AD. Persistent neurotoxicity of systemically administered interferon- $\alpha$ . *Neurology* 1991;41:672-676.
11. Cohen MC, Huberman MS, Nesto RW. Recombinant  $\alpha_2$  interferon-related cardiomyopathy. *Am J Med* 1988;85:549-551.
12. Sonnenblick M, Rosin A. Cardiotoxicity of interferon: a review of 44 cases. *Chest* 1991;99:557-561.
13. Chin K, Tabata C, Satake N, Nagai S, Moriyasu F, Kuno K. Pneumonitis associated with natural and recombinant interferon alfa therapy for chronic hepatitis C. *Chest* 1994;105:939-941.
14. Kamitsukasa H, Ohtake M, Kawashima H, Yagura M, Harada H, Katayama T. Two cases of interstitial pneumonia induced by interferon therapy for chronic aggressive hepatitis, type C. *Acta Hepatol Jpn* 1993; 34:478-483 (in Japanese with English abstract).
15. Daito K, Suou T, Kawasaki H. A case of chronic hepatitis C with interstitial pneumonitis during interferon therapy. *Acta Hepatol Jpn* 1993; 34:718-722 (in Japanese with English abstract).
16. Yamamoto S, Shimabara M, Yamamoto R, et al. A case of chronic hepatitis C with pneumonitis during interferon therapy. *Nippon Shokakibyo Gakkai Zasshi* 1993;90: 2142-2146 (in Japanese).
17. Crystal RG, Fulmer JD, Roberts WC, Moss ML, Line BR, Reynolds HY. Idiopathic pulmonary fibrosis: clinical, histologic, radiographic, physiologic, scintigraphic, cytologic and biochemical aspects. *Ann Intern Med* 1976;85:769-788.
18. Niden AH, Mishkin FS, Khurana MML. Gallium-67-citrate lung scans in interstitial lung disease. *Chest* 1976;69(suppl):266-268.
19. Scheuer PJ, Thaler H, Desmet VJ, et al. Acute and chronic hepatitis revisited: review by an international group. *Lancet* 1977;2:914-919.
20. DeGroote J, Desmet VJ, Gedigk P, et al. A classification of chronic hepatitis. *Lancet* 1968;2:626-628.
21. Tzen K-Y, Oster ZH, Wagner HN Jr, Tsan M-F. Role of iron-binding proteins and enhanced capillary permeability on the accumulation of gallium-67. *J Nucl Med* 1980;21:31-35.
22. Nishiguchi S, Kuroki T, Nakatani S, et al. Randomized trial of effects of interferon- $\alpha$  on incidence of hepatocellular carcinoma in chronic active hepatitis C with cirrhosis. *Lancet* 1995;346:1051-1055.
23. Siemsen JK, Grebe SF, Sargent EN, Wentz D. Gallium-67 scintigraphy of pulmonary diseases as a complement to radiography. *Radiology* 1976;118:371-375.
24. Kinoshita F, Ushio T, Maekawa A, Ariwa R, Kubo A. Scintiscanning of pulmonary diseases with  $^{67}\text{Ga}$ -citrate. *J Nucl Med* 1973;15:227-233.
25. Swartzendruber DC, Nelson B, Hayes RL. Gallium-67 localization in lysosomal-like granules of leukemic and nonleukemic murine tissues. *J Natl Cancer Inst* 1971;46: 941-952.
26. Line BR, Fulmer JD, Reynolds HY, et al. Gallium-67-citrate scanning in the staging of idiopathic pulmonary fibrosis: correlation with physiologic and morphologic features and bronchoalveolar lavage. *Am Rev Respir Dis* 1978;118:355-365.
27. Cooper JAD Jr, White DA, Matthey RA. Drug-induced pulmonary disease. Part 1: cytotoxic drugs. *Am Rev Respir Dis* 1986;133:321-340.
28. Cooper JAD Jr, White DA, Matthey RA. Drug-induced pulmonary disease. Part 2: noncytotoxic drugs. *Am Rev Respir Dis* 1986;133:488-505.
29. Roth JA, Frank DE. Recombinant bovine interferon- $\gamma$  as an immunomodulator in dexamethasone-treated and nontreated cattle. *J Interferon Res* 1989;9:143-151.
30. Ueda T, Ohta K, Suzuki N, et al. Idiopathic pulmonary fibrosis and high prevalence of serum antibodies to hepatitis C virus. *Am Rev Respir Dis* 1992;146:266-268.

# Detection of Postoperative Deep-Venous Thrombosis Using Technetium-99m-Labeled Tissue Plasminogen Activator

S. Patrick Butler, Tan Rahman, Samantha J. Boyd, Sharon L. Parkes and Richard J. Quinn  
*Department of Nuclear Medicine, St. George Hospital, Sydney, Australia*

The current noninvasive methods of deep-venous thrombosis (DVT) detection in the asymptomatic patient are sufficiently inaccurate so as to preclude their routine use. This present study reports the accuracy of scintigraphic scanning with  $^{99\text{mTc}}$ -rt-PA in asymptomatic postoperative patients using contrast venography as the gold standard. **Methods:** Fifty-three consecutive postarthroplasty patients (30 THR, 23 TKR) (16 women, 37 men; mean age 71 yr; range 52-85 yr) underwent scintigraphic scanning with  $^{99\text{mTc}}$ -rt-PA and contrast venography, on the operated leg, in order to assess the

accuracy of this new technique in these asymptomatic patients. **Results:** Eighty-four segments were of diagnostic quality on contrast venography. Of the 15 thrombosed segments, 14 had positive scans. In the 69 nonthrombosed segments, 63 had negative scans. Thus, scintigraphic scanning with  $^{99\text{mTc}}$ -rt-PA had a sensitivity of 93% and a specificity of 91%. **Conclusion:** This study demonstrated that scintigraphic scanning with modified  $^{99\text{mTc}}$ -rt-PA is accurate in the detection of DVT in patients undergoing total hip or total knee arthroplasty.

**Key Words:** technetium-99m; recombinant tissue plasminogen activator; deep-venous thrombosis

**J Nucl Med 1997; 38:219-223**

Received Feb. 28, 1996; revision accepted May 8, 1996.  
 For correspondence or reprints contact: S.P. Butler, MD, Dept. of Nuclear Medicine, St. George Hospital, Sydney 2217, Australia.