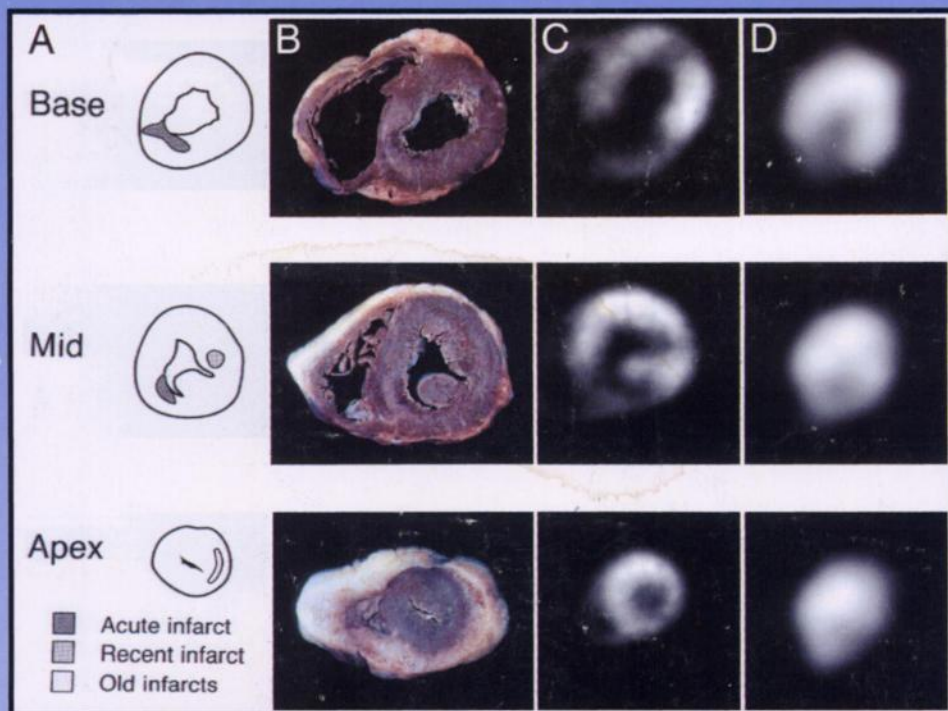


JNM

Volume 38, Number 12 • December 1997



Myocardial slices imaged postmortem in a patient who died shortly after injection of ^{99m}Tc -MIBI. See pages 1837-1840.

