levels is a common finding, actual tumor growth in the myocardium is rare. In our patient, despite the finding of a negative endocardial biopsy, the ^{111}In-pentetreotide scan, co-registered with CT, unequivocally showed high concentration of somatostatin receptors in the right ventricular mass lesion, providing strong evidence that this was indeed carcinoid tumor metastatic to the heart. These findings were subsequently confirmed at surgery.

CONCLUSION

This case illustrates the usefulness of ^{111}In-pentetreotide and fusion imaging to evaluate metastatic carcinoid tumor. This technique represents a safe and powerful tool for noninvasive in vivo tissue diagnosis and results in a more rational management plan and better care for the patient.

REFERENCES

1. Himelman RB, Schiller NB. Clinical and echocardiographic comparison of patients with the carcinoid syndrome with and without carcinoid heart disease. *Am J Cardiol* 1989;63:347–352.
2. Martensson H, Nobin A, Sundler F. Carcinoid tumors in the gastrointestinal tract: an analysis of 156 cases. *Acta Chir Scand* 1983;149:607–616.
3. Pellikka PA, Tajik JA, Khandheria BK et al. Carcinoid heart disease: clinical and echocardiographic spectrum in 74 patients. *Circulation* 1993;87:1188–1196.
4. Howard RJ, Drobac M, Rider WD, et al. Carcinoid heart disease: diagnosis by two-dimensional echocardiography. *Circulation* 1982;66:1059–1065.
5. Charms BL, Kohn P, Applebaum HI, Geller J. Hemodynamic studies in a case of carcinoid cardiovascular syndrome. *Circulation* 1959;20:208–214.
6. Tornebrandt K, Eskilsson J, Nobin A. Heart involvement in metastatic carcinoid disease. *Clin Cardiol* 1986;9:13–19.
7. Knott-Craig CJ, Schaff HV, Mullany CJ et al. Carcinoid disease of the heart: surgical management of 10 patients. *J Thorac Cardiovas Surg* 1992;104:475–481.
8. Schiller VL, Fishbein MC, Siegel RJ. Unusual cardiac involvement in carcinoid syndrome. *Am Heart J* 1986;112:1322–1323.
9. Fine SN, Gaynor ML, Isom OW, Dannenberg AJ. Carcinoid tumor metastatic to the heart. *Am J Med* 1990;89:690–692.
10. Lund JT, Ehman RL, Julsrud PR, Sinak LJ, Tajik AJ. Cardiac masses: assessment by MR imaging. *AJR* 1989;152:469–473.
11. Scott AM, Macapinlac H, Zhang JJ, et al. Clinical applications of fusion imaging in oncology. *Nucl Med Biol* 1994;21:775–784.
12. Zimmer T, Ziegler K, Liehr R, Stolzel U, Riecken E, Wiedenmann B. Endosonography of neuroendocrine tumors of the stomach, duodenum, and pancreas. *Ann NY Acad Sci* 1994;733:425–436.
13. Reubi JC, Hacki WH, Lamberts SWJ. Hormone producing gastrointestinal tumors contain a high density somatostatin receptors. *J Clin Endocrinol Metab* 1987;65:1127–1134.
14. Lamberts SWJ, Chayvialle JA, Krenning EP. The visualization of gastroenteropancreatic endocrine tumors. *Metabolism* 1992;41:9(suppl 2):111–115.
15. Krenning EP, Bakker WH, Breeman WAP, et al. Localization of endocrine related tumors with radioiodinated analogue of somatostatin. *Lancet* 1989;1:242–244.
16. Lamberts SWJ, Krenning EP, Reubi JC. The role of somatostatin and its analogs in the diagnosis and treatment of tumors. *Endocrinol Rev* 1991;12:450–482.
17. Krenning EP, Bakker WH, Kooij PPM, et al. Somatostatin receptor scintigraphy with indium-111-DTPA-d-Phe-1-octreotide in man: metabolism, dosimetry and comparison with iodine-123-Tyr-3-octreotide. *J Nucl Med* 1992;33:652–658.
18. Krenning EP, Kwekkeboom DJ, Bakker WH, et al. Somatostatin-receptor scintigraphy with ^{111}In-DTPA-D-Phe- and ^{123}I-Tyr-octreotide: the Rotterdam experience with more than 1000 patients. *Eur J Nucl Med* 1993;20:283–292.
19. Krenning EP, Kwekkeboom DJ, Oei HY, et al. Somatostatin-receptor scintigraphy in gastroenteropancreatic tumors. *Ann NY Acad Sci* 1994;733:416–424.
20. Kvols L, Reubi J, Horisberger U, Moertel C, Rubin J, Charboneau J. The presence of somatostatin receptors in malignant neuroendocrine tumor tissue predicts responsiveness to Octreotide. *Yale J Biol Med* 1992;65:505–518.
21. Carnaille B, Nocaudie M, Pattou F, et al. Scintiscans and carcinoid tumors. *Surgery* 1994;116:1118–22.

Lung and Gastric Uptake in Bone Scintigraphy of Sarcoidosis

Ayten Gezici, Elly M. van Duijnhoven, Stephan J.L. Bakker, Guido A.K. Heidendal and Marinus J.P.G. van Kroonenburgh
Departments of Nuclear Medicine and Internal Medicine, Maastricht Academic Hospital, Maastricht, The Netherlands

We report on ^{99m}Tc-MDP uptake in lungs and stomach in a patient with hypercalcaemia and renal failure due to elevated 1,25(OH)$_2$vitD$_3$ because of sarcoidosis. Presently, this typical scan pattern has only been described in patients with malignancies, parathyroid adenoma and drug-induced vitamin D intoxication. We offer possible explanations for the findings in our patient.

Key Words: sarcoidosis; lung; stomach; bone scintigraphy

J Nucl Med 1996; 37:1530–1532

Extraosseous fixation of activity in organs can sometimes be seen in bone scintigraphy. This phenomenon is usually associated with microscopic calcifications due to an abnormality of calcium metabolism and occurs most often in the lungs. Hypercalcaemia and renal failure are often present but are not necessarily prerequisites to observe this phenomenon (*1*). Sometimes multiple organs are involved (*2*). Concomitant lung and gastric uptake is rare. Published reports describe the occurence in patients with malignancy: multiple myeloma (*3–8*), breast cancer (*9*), Hodgkin's disease (*10*) and bladder carcinoma (*11*).

Of special interest are the reports that describe increased activity in the lungs and stomach not related to malignant disease. Those articles reported on patients with parathyroid adenoma (*12*), Paget's disease and vitamin D intoxication in conjunction with high calcium intake (*6,13*).

We report on a patient with sarcoidosis who had the same rare combination of lung and gastric uptake on a ^{99m}Tc-methylene diphosphonate (MDP) bone scan.

CASE REPORT

Clinical Data

A 70-yr-old man was admitted to our hospital because of slowly progressive dyspnea, orthopnea, edema and decreased diuresis. His medical history reported acute rheumatic fever in childhood and repeated cardiac surgery for aortal, mitral and tricuspidal valve replacement between 1980 and 1992. Five years before admission, a CT scan of the thorax showed massive hilar and mediastinal lymphomas. Sarcoidosis was diagnosed after lymph node biopsy.

For several years, there was stable, slightly impaired renal function: serum calcium rose gradually from a normal value to 2.89 mmol/liter 3 mo before admission. The patient did not smoke or use alcohol. His medication consisted of bumetanide, isosorbide-5-mono-nitrate and acenocoumarol. His temperature was 36.8°C, blood pressure 140/80 mmHg, pulse 70/min and respiratory rate 35/min. Elevated central venous pressure, grade 2 systolic cardiac

Received Dec. 5, 1995; revision accepted Mar. 14, 1996.

For correspondence or reprints contact: Marinus J.P.G. van Kroonenburgh, Department of Nuclear Medicine, Academic Hospital Maastricht, PO Box 5800, 6202 AZ Maastricht, The Netherlands.

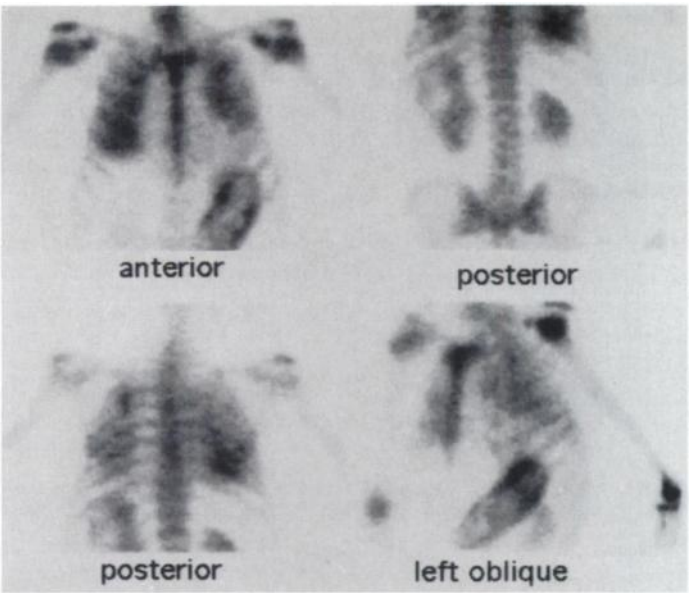

FIGURE 1. Whole-body bone scintigraphy in a 70-yr-old man. Marked ^{99m}Tc-MDP accumulation only in the lungs and fundus of the stomach is seen from the anterior and left lateral views. Kidney uptake was within the normal range.

murmur on the apex, bilateral postero-basal pulmonary rales, hepatomegaly and extensive peripheral edema were found.

Initial urine analysis was normal. The serum calcium was 3.12 mmol/liter, phosphorus 2.74 mmol/liter (normal 0.90–1.50), calcium-phosphorus ionization product 103 mg^2/dl^2 (normal < 40), albumin 31.3 g/liter (normal 35.0–55.0) and creatinine 521 μmole/liter. Liver function tests, glucose, blood gas analysis and blood cell counts were normal. A chest radiograph revealed cardiomegaly, pulmonary congestion and stable hilar abnormalities. No calcifications were seen. Ultrasonography of the kidneys was normal. Renal biopsy revealed some amorphous calcification structures in the tubuli; no granulomas or signs of glomerulonephritis were found. A diagnosis of circulatory overload due to renal failure presumably because of sarcoidosis-induced hypercalcemia was made.

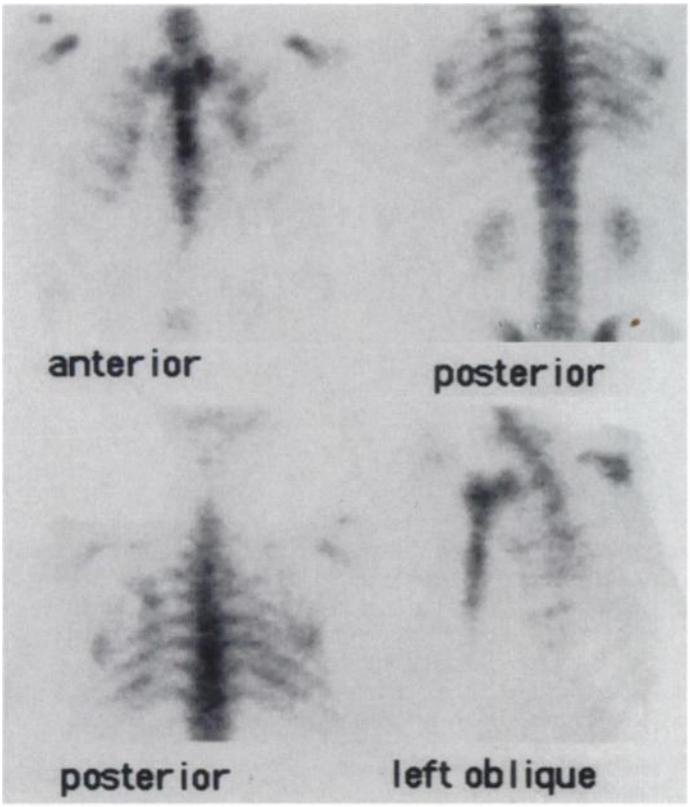

FIGURE 2. Repeat bone scan 2 mo later. No osseous or extraosseous abnormalities could be seen. The scintigram was judged as normal.

Therapy consisted of fluid restriction, diuretics, a single intravenous shot of pamidronic acid and oral prednisone 60 mg daily. The response was excellent. The heart failure resolved, serum calcium and phosphorus returned to normal levels and the creatinine returned to 150 μmole/liter. Renal failure due to hypercalcemia because of sarcoidosis could retrospectively be confirmed by very high $1,25(OH)_2vitD_3$ of 142 pmole/liter (normal 40–100) and normal $25OHvitD_3$ of 46 nmol/liter (normal 25–70). An ACE of 31 U/liter (normal 9–25) and lysozyme of 1270% (normal 55–145) also supported the diagnosis.

During therapy, alkaline phosphatase increased from normal to maximal 717 U/liter after 8 days, while gamma-GT, ASAT and ALAT remained normal. Because of these results, the patient was referred for bone scintigraphy. After several weeks, alkaline phosphatase levels slowly returned to normal.

Imaging

Routine bone scintigraphy was performed. Static images were obtained 3 hr after intravenous administration of 15 mCi (555 MBq) ^{99m}Tc-MDP. Images (preset counts of 500,000) were made in the anterior and posterior views with a gamma camera equipped with a low-energy, high-resolution collimator. Additional views of the chest were obtained in the oblique view. The images showed a normal skeleton, but marked extraosseous activity was seen in both lungs and stomach (Fig. 1). No other abnormal radioactive distribution was noticed. The heart and especially the thyroid were not visualized. Routine quality control data for ^{99m}Tc-MDP on that day showed the labeling yield to be greater than 98%.

A second bone scan was made about 2 mo later (Fig. 2). The bone scintigram was judged as normal. The high uptake in the lungs and stomach had disappeared.

DISCUSSION

Sarcoidosis is a multisystem granulomatous disease. The most frequently involved organs are the lungs. In sarcoidosis, the sarcoid lesions can enzymatically activate vitamin D_3 precursors into the active form $1,25(OH)_2vitD_3$, leading to increased calcium absorption in the small intestine. Routine laboratory evaluation reveals hypercalcemia in 10% and/or hypercalciuria in 30% of patients (*14*), which can lead to nephrocalcinosis or neprolithiasis (*15*). Other renal manifestations of sarcoidosis are granulomatous infiltration of the kidney (10%–40%) and, in rare cases, glomerulonephritis (*14*). Kidney biopsy in our patient revealed only amorphous calcification structures in the tubuli.

Prednisone is usually the drug of choice for the treatment of sarcoidosis and commonly improves the hypercalcemia (*7*), as in our patient.

The calcium levels in our patient increased gradually over the last 3 yr, but were progressive during the last 3 mo. Hyperphosphatemia was due to the combination of reduced renal excretion capacity because of a declining renal function and increased intestinal absorption because of hypervitaminosis D. Disturbances of calcium metabolism lead to calcification and become clinically apparent when the calcium-phosphorus ionization product exceeds a certain value, usually above 40–80 (*10,12*). In our patient this value has been above 100.

The intense accumulation of extraosseous activity in the lungs and stomach on the bone scan, which reflects soft-tissue calcinosis, is probably caused by prolonged states of hypercal-

cemia and hyperphosphatemia. Technetium-99m-MDP binds avidly to the tissue crystals that are present.

Extracellular fluid expansion and enhanced regional vascularity and permeability due to granulomatous inflammation may also cause this high extraosseous ^{99m}Tc-MDP uptake (*16*).

The findings in our patient are unique because his hypercalcemia is not caused by malignant disease, hyperparathyroidism or drug-induced vitamin D intoxication. Elevated soft-tissue uptake of ^{99m}Tc-MDP caused by drug-induced vitamin D intoxication has been reported (*10,13*). The patients in these reports had elevated uptake in the lungs and/or in the stomach. One patient (*13*) took roughly 2000 U of vitamin D and 3 g of calcium a day. Massive gastric uptake ^{99m}Tc-MDP without elevated lung uptake has been reported only once in a patient who had a milk-alkali syndrome (*13*). In our patient, drug-induced hypervitaminosis D could be ruled out.

Rapidly calcifying sites are frequently pure amorphous calcium phosphate accumulations with a large surface area. The reason why only the stomach and the lungs were visualized could be explained by the fact that calcification can occur in normal tissue when the acid-base balance allows precipitation of calcium and phosphate (*1*). Intracellular pH is high in the lungs because of low pCO_2 and because of acid secretion in the kidneys and stomach (*17*). These are the predominant places where calcium salt precipitates (*13*). In our patient, the fundus of the stomach showed higher activity than in the antrum, which we believe confirms the pH dependency of the calcium deposition. Gastric fixation in bone scintigraphy due to preparation failure (*18*) can occur but was ruled out in our patient.

Interestingly, during the first bone scan, the calcium-phosphorus ionization product in the blood was already normal. Probably the injected ^{99m}Tc-MDP bound avidly to the tissue crystals that were still present. After 6 wk, the gastric and lung uptake had disappeared, apparently because the tissue crystals were dissolved because of the relatively long period of a normal calcium/phosphorus ionization product. There is one other published report on this reversible phenomenon (*17*).

CONCLUSION

We expect, because organ involvement and hypercalcemia in sarcoidosis are often asymptomatic, that calcinosis occurs more often in patients then previously described. Usually bone scans are not obtained in patients with sarcoidosis, despite the fact that bone scintigraphy has been described as a sensitive modality for recognition of bony involvement by sarcoidosis (*19*).

REFERENCES

1. Heck LL. Extraosseous localization of phosphate bone agents. *Semin Nucl Med* 1980;10:311–313.
2. Padhy AK, Gopinath PG, Amini AC. Myocardial, pulmonary, diaphragmatic, gastric, splenic and renal uptake of ^{99m}Tc-MDP in a patient with severe hypercalcemia. *Clin Nucl Med* 1990;15:648–649.
3. Wynchank S, Brendel AJ, Leccia F, Lacoste D, Maire JP, Ducassou D. Transient intense gastric fixation of ^{99m}Tc-MDP. *Eur J Nucl Med* 1983;8:458–460.
4. Reitz MD, Vasinrapee P, Mishkin FS. Myocardial, pulmonary and gastric uptake of ^{99m}Tc-MDP in a patient with multiple myeloma and hypercalcemia. *Clin Nucl Med* 1986;11:730.
5. Valdez VA, Jacobstein JG, Perlmutter S, Brusman H. Metastatic calcification in the lungs and stomach demonstrated on bone scan in multiple myeloma. *Clin Nucl Med* 1979;4:120–121.
6. Rosenthal DI, Chandler HL, Azizi F, Schneider PB. Uptake of bone imaging agents by diffuse pulmonary metastatic calcification. *AJR* 1977;129:871–874.
7. Richards AG. Metastatic calcification detected through scanning with ^{99m}Tc-polyphosphate. *J Nucl Med* 1974;15:1057–1060.
8. Grames GM, Sauser DD, Jansen C, Soderblom RE, Hodgkin JE, Stilson MS. Radionuclide detection of diffuse interstitial pulmonary calcification. *JAMA* 1974;230:992–995.
9. McDevitt GR, Heironimus JD, Toney MO, Bilingsley JL. Diffuse abdominal uptake of technetium-99m-methylene diphosphonate in a patient on continuous ambulatory dialysis during bone scintigraphy. *J Nucl Med* 1992;33:2052–2054.
10. Jayabalan V, De Witt B. Gastric calcification detected in vivo by ^{99m}Tc-pyrophosphate imaging. *Clin Nucl Med* 1978;3:27–29.
11. Schlangen JT, Pauwels EKJ. Die diagnostik der calcinosis pulmonis durch szintigraphische untersuchungen. *Fortschr Geb Roentgenstr Nuclearmed* 1976;124:119–123.
12. Van Leendert FJ, Flendrig JA. A patient with primary hyperparathyroidism and an abnormal bone scan. *Clin Nucl Med* 1986;11:701–703.
13. Corstens F, Kerremans A, Claessens R. Resolution of massive technetium-99m-methylene diphosphonate uptake in the stomach in vitamin D intoxication. *J Nucl Med* 1986;27:219–222.
14. Akmal M, Sharma OP. Renal sarcoidosis: a reminder. *Chest* 1990;97:1284–1285.
15. Marinides GN, Hadju I, Gans RO. A unique association of renal carcinoma with sarcoid reaction in the kidney. *Nephron* 1994;67:477–480.
16. Peller PJ, Ho VB, Kransdorf MJ. Extraosseous ^{99m}Tc-MDP uptake: a pathophysiologic approach. *Radiographics* 1993;13:715–734.
17. Delcourt E, Baudoux M, Neve P. Technetium-99m-MDP bone scanning detection of gastric calcification. *Clin Nucl Med* 1980;5:546–547.
18. Dhawan V, Yeh DJ. Labeling efficiency and stomach concentration in methylene diphosphonate bone imaging. *J Nucl Med* 1979;20:791–793.
19. Yaghma I. Radiographic, angiographic and radionuclide manifestations of osseous sarcoidosis. *Radiographics* 1983;3:374–376.

Accelerated Thyrotoxicosis Induced by Iodinated Contrast Media in Metastatic Differentiated Thyroid Carcinoma

Mordechai Lorberboym and Jeffrey I. Mechanick

Division of Nuclear Medicine, Department of Radiology, and Division of Endocrinology, Department of Medicine, Mount Sinai School of Medicine, New York, New York

A 67-yr-old woman who underwent total thyroidectomy 32 yr ago developed accelerated hyperthyroidism after injection of iodinated contrast media to evaluate a left hemipelvis mass. The patient was managed with propylthiouracil, beta-blockers and digoxin. Whole-body ^{201}Tl and ^{131}I scans demonstrated a functioning metastasis in the left hemipelvis where biopsy revealed a well differentiated follicular thyroid carcinoma. Palliative external beam radiotherapy was administered. The patient then received radioiodine treatment with granulocyte colony-stimulating factor to minimize bone marrow toxicity. Clinically significant thyrotoxicosis occurring in metastatic thyroid carcinoma is rare and results from abnormal ectopic thyroidal tissue iodine metabolism. Iodide-containing medications and contrast media should be avoided in patients with functioning thyroid metastases to prevent abrupt increases in circulating thyroid hormone levels.

Key Words: thyroid carcinoma; thyrotoxicosis; granulocyte colony-stimulating factor

J Nucl Med 1996; 37:1532–1535

Received Dec. 5, 1995; revision accepted Mar. 6, 1996.

For correspondence or reprints contact: Mordechai Lorberboym, MD, Department of Nuclear Medicine, Mount Sinai Medical Center, One Gustave L. Levy Pl., New York, NY 10029.