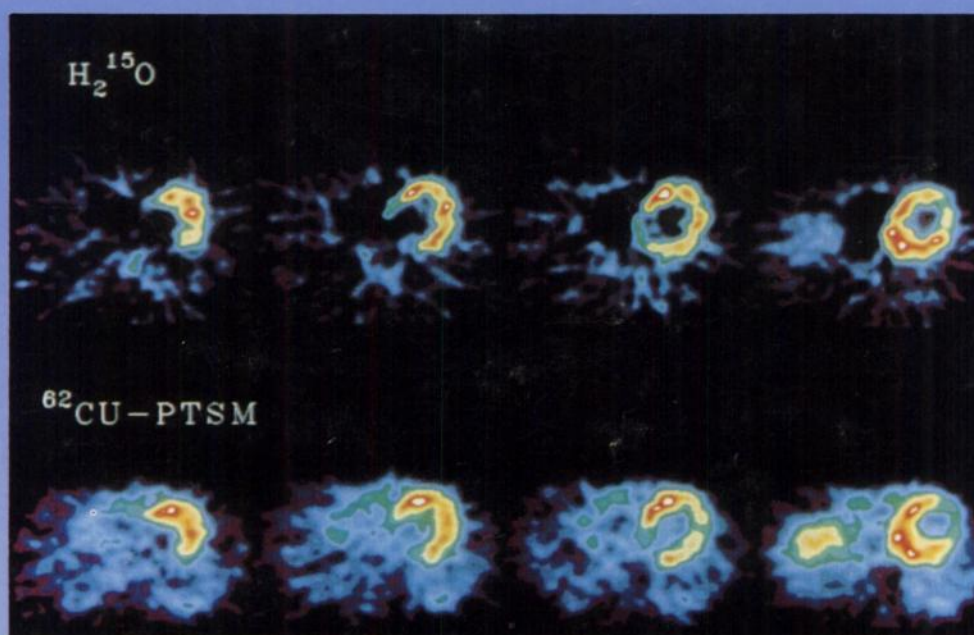

The Journal of Nuclear Medicine

JNM

Volume 37, Number 8 • August 1996



Myocardial images obtained from 20 to 100 seconds after administration of $H_2^{15}O$ (top) and corresponding images obtained from 10 to 15 minutes after administration of $^{62}Cu-PTSM$ (bottom) from a healthy human subject at rest. See pages 1294-1300.



The Official Publication of
the Society of Nuclear Medicine, Inc.
