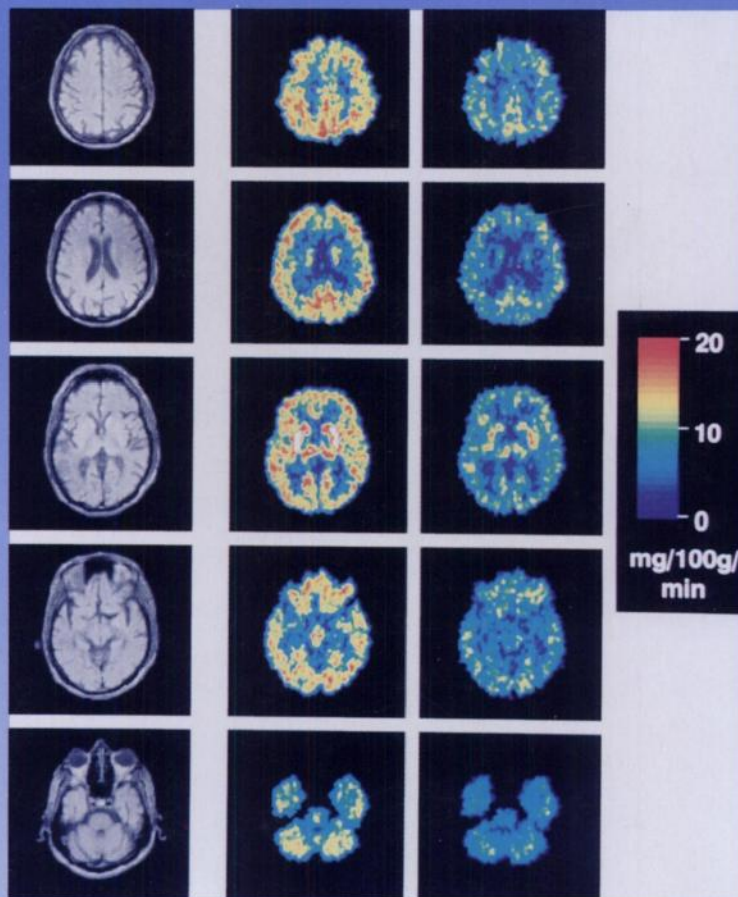

The Journal of Nuclear Medicine

JNMM

Volume 37, Number 7 • July 1996

NUCLEAR NEUROLOGY: 1996



MRI and color-coded transforms of FDG-PET scans at five different brain levels in a patient with AIDS dementia complex pre- and post-treatment with 1.2 mg/kg of intranasal peptide T for 12 wk. See pages 1177-1180.



The Official Publication of
the Society of Nuclear Medicine, Inc.
