

# Factor Analysis in Successive Hepatobiliary Imaging of Native and Transplant Livers

Slavomir Petras, André Aurengo, Delphine Le, Mireille Di Paola, Christian Jeanguillaume and Pierre Galle  
INSERM U66, CHU Pitie-Salpêtrière, Paris, France; and Nuclear Medicine and Biophysics Laboratory, CHU Henri Mondor, Créteil, France

A young male patient suffering from fulminant hepatic failure of unknown origin had an auxiliary partial orthotopic liver transplantation performed. The aim of the present study was to test the performance of factor analysis of medical image sequences (FAMIS) in the post-transplantation monitoring of the graft and native liver functions. **Methods:** Four successive hepatobiliary studies within 63 days following transplantation using  $^{99m}\text{Tc}$ -mebrofenin were performed (on days 13, 20, 34, 63). The 60 one-minute dynamic series were subjected to two successive FAMIS procedures. **Results:** For all studies, except the first, FAMIS was able to extract three factor couples (factor images and factors or curves) those of the native liver, the graft liver and the biliary region. The factors time evolution in uptake and excretion components showed the correlations between clinical status and scintigraphic results and helped in interpretation of biochemical tests. **Conclusion:** The possible utility of systematic liver transplant monitoring by radionuclide hepatobiliary imaging in identification of complications requiring medical or surgical intervention in graft livers was demonstrated. Furthermore, our study showed the functional recovery potential of the native liver in patients suffering from fulminant hepatitis.

**Key Words:** hepatobiliary imaging; radionuclide studies; transplantation

**J Nucl Med 1996; 37:847-851**

Fulminant hepatic failure is usually a fatal clinical event with a low survival rate (1). The auxiliary partial orthotopic liver transplantation, in which the native liver is left partially in place and a donor liver fragment is added (2-6), is a promising, recently developed therapy with patients suffering from fulminant hepatic failure.

Biochemical tests are of limited clinical value (7-10). This is due to a multitude of factors including the primary disease process, insults to the organs during conservation and surgery, transfusions and post-transplantation therapy (6,10). Further, biochemical monitoring has no diagnostic value in distinguishing between the functions of two different livers.

It was demonstrated that the primary usefulness of radionuclide studies using  $^{99m}\text{Tc}$ -labeled iminodiacetic acid derivate is in the postoperative monitoring of graft function (5,7-10). In auxiliary partial orthotopic liver transplantation, however, the only definitive method to assess native liver recovery and graft liver rejection still remains liver biopsy (7-9). Nevertheless, it cannot be performed very often because of repeated biopsy traumas and coagulation problems (6).

Thus, in its absence, hepatobiliary scintigraphy plays a crucial role in native liver recovery monitoring and in graft liver detransplantation timing. Some radionuclide studies were carried out for these purposes (11) using classical regions of interest (ROI) (5,7-10) or other methods (12). Factor analysis

of medical image sequences, however, has not yet been performed in such a study (FAMIS) (13-19).

The first aim of this correlative study was to test the performance of FAMIS to distinguish and monitor two different liver functions within 63 days following transplantation. We tested the advantages of FAMIS over the ROI method, routinely used in the evaluation of liver transplantation. The latter technique suffers from inadequacies such as operator dependency, cross-talk between regions, lack of accuracy and reliability (13-15). FAMIS offers at least partial solutions to some of these problems (14), however, suffers from difficulties resulting from image sequence processing (13,15,20).

The second objective was to demonstrate the possible utility of systematic monitoring of liver transplants in the post-transplantation period and its role in the interpretation of biochemical tests and in the critical decision leading to the graft liver detransplantation.

## MATERIALS AND METHODS

### Patient

A 15-yr-old boy with a 10-day history of jaundice was referred to the hospital because of acute fulminant hepatitis complicated by encephalopathy (stage I). The first biochemical analysis showed total bilirubin exceeding 100  $\mu\text{mole/liter}$  and high aspartate-aminotransferase (AST) and alanine-aminotransferase (ALT) levels (AST showed fifty- and ALT forty-fold increase). No history of hepatotoxic drugs, transfusions or other hepatitis-inducing factors was elicited. Serologic testing for hepatitis A, B and C was negative. After hospitalization fulminant hepatic failure with progressive encephalopathy (stage III) and coagulopathy (prothrombin time 8%, factor V 30%) occurred. Based on clinical and biochemical findings it was decided to urgently perform partial orthotopic liver transplantation on the 14th day after the patient's admission. The pathological native liver was reduced by left and the graft liver by right hepatic lobectomy and biliary reconstruction performed by a termino-terminal choledocho-duodenal anastomosis. The needle biopsy (21-23) performed on operation day (Day 0) showed massive hepatocyte necrosis in native liver, two other biopsies were done within 2 wk after auxiliary partial orthotopic liver transplantation (Day 6, Day 14). In the post-transplantation period the following complications occurred (Table 1).

Cerebral edema was treated by ventricular drainage and volume depletion therapy guided by intracranial pressure monitoring. The graft liver portal-vein thrombosis was surgically corrected and coagulopathy controlled by transitory heparin therapy. Management of rejection episodes consisted of conventional combination of cyclosporine, azathioprine and corticosteroids (6). Renal dysfunction was corrected by volume expanders; abdominal infection was treated by antibiotic therapy. The intrahepatic abscess led finally to graft liver detransplantation on Day 138. The native liver returned to normal and the patient became well and was discharged from the hospital.

Received Apr. 27, 1995; revision accepted Nov. 1, 1995.

For correspondence or reprints contact: Slavomir Petras, MD, INSERM U 66, CHU Pitie-Salpêtrière, 91, Bd de l'Hôpital, 75013 Paris, France.

## Scintigraphy

Following the intravenous bolus injection of 222 MBq of  $^{99m}\text{Tc}$ -mebrofenin abdominal sequential images ( $64 \times 64$  matrix) were obtained. Four dynamic studies (on days 13, 20, 34, 63) using a gamma camera equipped with a low-energy and high-resolution collimator were performed. The patient was positioned supine and the field of view of the gamma camera included the whole-heart region, both livers and a large intestinal area. Dynamic series were obtained at the rate of one frame/min during 60 min after injection. The energy spectrometer was set for 140 keV photons at 20% window.

## Data Analysis

The hepatobiliary studies were processed in the same manner (Table 2) including two successive FAMIS procedures on Sun Workstation (Sun Microsystems, Mountain View, CA).

Since FAMIS assumes that organs remain fixed during acquisition, an automatic correlation image registration method (20) was used to compensate patient's motion. The whole-heart region was masked in order to reduce the number of extracted factors using an isocontour ROI. No background subtraction was done. The first FAMIS was used to determine gallbladder and common bile duct/bowel areas, in the second FAMIS the series were submitted to total (common bile duct/bowel) and partial (gallbladder) masking.

Two or three factor couples (factor images and factors or curves), each of them representing a basic dynamic structure (Fig. 1) were extracted in the second FAMIS procedure.

To interpret the factor couples, two main criteria were considered. First, the shape and homogeneity of both livers and their possible separation in factor images (18) were visually evaluated. Second, the shape and the time evolution of the factors, as well as the distinction between hepatobiliary uptake and excretion components were studied (17).

## Biochemical Parameters and Biopsy

Intermittent "daily" evaluations of total bilirubin, alkaline phosphatase, AST, ALT and gamma-GT serum values, obtained the same day the scintigraphic study was performed, were analyzed. Two needle biopsies (on days 6, 14) were done in the post-transplantation period.

## RESULTS

The second FAMIS procedure allowed the extraction of three factor couples (on Days 20, 34, 63), while only two factor couples were extracted on Day 13 (Fig. 1). Generally, factor images showed less modifications than factors within all examinations.

Graft liver factor image showed relative stability in its shape in comparison with native liver one. Factor images separation was "contaminated" by some noncharacteristic pixels (examinations on Day 20, Day 34) on the graft upper (liver/heart), lower (liver/bowel) and lower native liver (liver/bowel) borders. Heterogeneity in native liver image was detected only on Day 13.

The graft liver factor showed less modifications in its shape and components. Furthermore, it presented a clear component separation during all examinations. The progressive increase in graft uptake and excretion reached its maximum on Day 34. The last examination on Day 63 showed deteriorating factor and its less typical time evolution.

The native liver factor showed an atypical evolution during the first two examinations (Day 13, Day 20) with a continuous decrease from the beginning of the study until its end at 60 min after injection. The Day 34 examination showed a poor separation of the uptake and excretion components. A dramatic native liver factor transformation with a clear component

**TABLE 1**  
Clinical Course and Complications after Auxiliary Partial Orthotopic Liver Transplantation

Day	Complication
2	Cerebral edema
6	Graft portal vein thrombosis
6	Acute rejection episode
7	Renal dysfunction
14	Recurrent rejection episode
18	Abdominal infection
63	Graft liver intrahepatic abscess

separation was registered on Day 63. Distinguishing between increasing and decreasing components in native liver factor was possible only on Day 63 and demonstrated a typical rapid uptake and a slower, prolonged excretion.

The biliary factor was not extracted on Day 13, otherwise it showed an increasing tendency on Day 63 in comparison with Day 20. This was demonstrated by its steeper accumulation up to the end of the study. Examination on Day 34, however, showed a less typical biliary factor.

Biochemical tests of total bilirubin, alkaline phosphatase, (Fig. 2A), transaminases (AST, ALT) and gamma-GT (Fig. 2B) are presented.

Biopsy on Day 6 documented rejection grade II and cholestasis in graft liver and initial hepatocellular recovery in the native liver. Only biopsy on Day 14 provided reliable arguments to compare the native liver (progressive hepatocellular recovery) and graft (rejection grade II and cholestasis) liver histologic findings, especially regarding the delay between biopsy and scintigraphy.

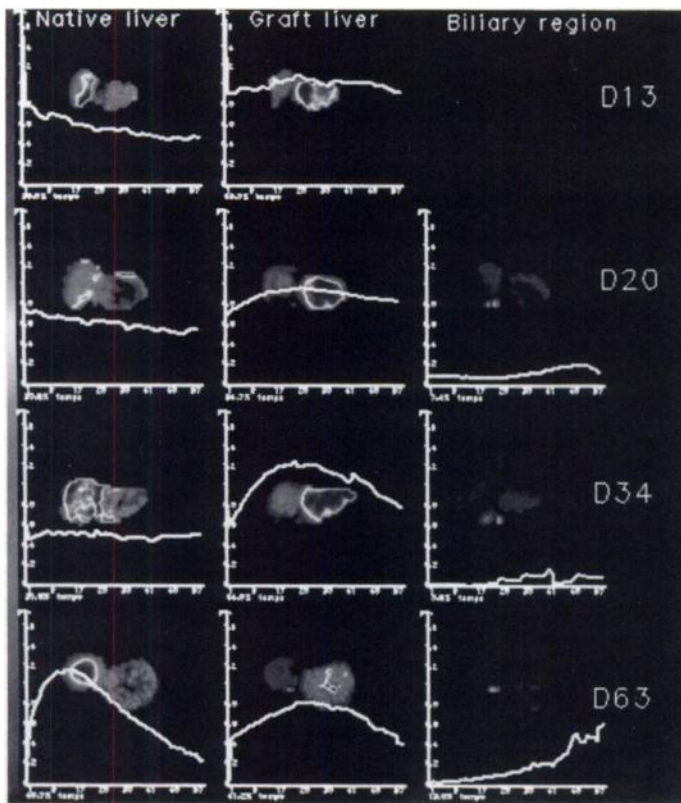
## DISCUSSION

Inspired by a robust physiological interpretation of kinetic parameters in the previously published paper (19), we have chosen FAMIS as a correlative study in partial orthotopic liver transplantation. The aim was to demonstrate its strengths in distinguishing between two different hepatobiliary kinetics (24,25) in partially superposed livers (11) and to propose a new "multiple-step" protocol (Table 2). This, however, is related to some difficulties related to image sequence handling. The most important is the time-consuming data processing including patient's motion correction and two FAMIS procedures to obtain scintigraphic results. Furthermore, there is no objective criterion in the processing strategy. The number of factors extracted, pixel aggregation and other technical parameters are operator-dependent (13,15). Finally, it is necessary to mask moving organs (17,18) because they completely invalidate the assumption of linear structures superposition on which FAMIS is based (see Appendix).

Only the intermittent "daily" biochemical values are discussed in relation to clinical course (Table 1), biopsies and

**TABLE 2**  
Data Processing Steps

Step	Procedure
1	Motion correction
2	Heart masking
3	Pixel aggregation
4	FAMIS 1
5	Gallbladder and common bile Duct/bowel masking
6	FAMIS 2



**FIGURE 1.** Factor couples and their evolution in four successive hepatobiliary studies after auxiliary partial orthotopic liver transplantation. For all the studies, except the first, FAMIS was able to extract three factor images/factors those of the native liver, the graft liver and the biliary region. FAMIS yielded only two factor couples on Day 13 and no biliary image/factor was extracted. The shapes of factor images were less or more typical in all examinations except the first on Day 13 and provided a good separation between the native and graft liver parenchymas. The intrahepatic biliary tree became visible in the graft liver factor image on Day 63 and neither native nor graft liver presented such an image in other examinations. Both native and graft liver factors showed more variations in their shapes and in uptake and excretion components.

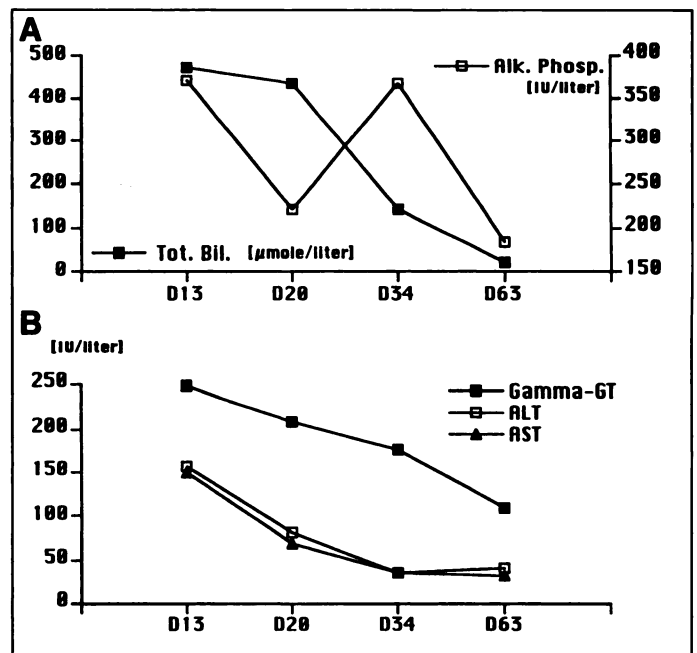
particular scintigraphies, which were dominated by graft cholestatic rejection (Day 13), infection-induced graft dysfunction (Day 20), maximal graft liver function (Day 34) and native liver recovery (Day 63).

#### First Examination: Day 13

Acute rejection, which frequency varies from 30% to 70%, is a leading cause of graft liver dysfunction and commonly appears in the second week after transplantation (Table 1) (5,7). This is often concomitant with cholestasis (9) and biochemically demonstrated by increases in serum bilirubin, transaminases, alkaline phosphatase and gamma-GT (Fig. 2A, B).

FAMIS yielded only native and graft liver factor couples (Fig. 1). The first showed an atypical heterogeneous factor image and a decreasing factor in which neither uptake nor excretion were noticed. Its time evolution could be due to the extrahepatocellular, vascular tracer activity within the native liver. Hepatocytes, being necrotized by fulminant hepatitis, did not show any function. Thus, hepatocyte damage resulted in prolonged retention of the agent in the vascular space and in decreased hepatocyte capacity to extract tracer from the blood (5,9,10) as well as in poor clearance from the native liver (7,8).

The graft liver factor image was typical in its shape, graft liver factor showed uptake and excretion components. Nevertheless both functions seemed to be altered. One recurrent rejection episode (21,22), associated with cholestasis (23), as well as the portal vein thrombosis (6) could explain depressed



**FIGURE 2.** Intermittent "daily" biochemical values and their evolution within 63 days after auxiliary partial orthotopic liver transplantation. (A) Total bilirubin (Tot.Bil.) and alkaline phosphatase (Alk. Phosp.) levels. Progressive decrease of total bilirubin was especially noted on Days 34 and 63. Increased alkaline phosphatase values persisted during all examinations, especially on Day 13 and Day 34. (B) Aspartate-aminotransferase (AST), alanine-aminotransferase (ALT) levels progressively and parallelly decreased during all examinations (except the ALT on Day 63 that showed a minimal increase in comparison to Day 34), while decrease of gamma-glutamyltransferase (gamma-GT) was less evident.

graft liver function and the absence of biliary factor. Conventional use of immunosuppressive drugs to manage the acute graft rejection (6,23) could participate in graft liver dysfunction. Our findings are in correlation with those reported by other authors (5,10). In addition, we suppose that renal dysfunction, is due to graft liver dysfunction, administration of nephrotoxic drugs (6,23) and less probably to primary native liver disease. On the other hand, renal dysfunction could also participate in intrahepatic cholestasis (6).

#### Second Examination: Day 20

Infection remains the second most common problem in the post-transplantation period (Table 1) (6,23) and participates on biochemical abnormalities. Their analysis showed AST and ALT decrease (Fig. 2B) signaling possible progressive native liver recovery and/or effect of corticosteroid treatment (23). Total bilirubin (Fig. 2A) and gamma-GT (Fig. 2B) values remained elevated. Initial excretion was detected (presence of biliary factor extracted by FAMIS), however, we suppose that intrahepatic cholestasis in graft liver (elevated alkaline phosphatase levels) was still present. No biopsy was performed in view of graft liver function stabilization; thus our hypothesis could not be confirmed.

The native liver factor did not present either uptake or excretion. This could be interpreted as poor native liver recovery. In the graft liver factor, there was a tendency to increased uptake and excretion in comparison with Day 13, but no shortening of  $T_{\text{max}}$  was noticed.

Further, compared with the first examination, FAMIS extracted a biliary factor (17,18) which was attributed to the graft liver due to the absence of native liver function (Fig. 1). Thus graft liver excretion, as documented by biliary factor, confirmed its improved function and we supposed that this was notably due to the facts that rejection episodes were therapeutically

under control and graft liver portal vein thrombosis was surgically corrected (6,10,23).

### Third Examination: Day 34

The transaminases reached normal values, bilirubin levels were significantly lower than on Day 20. In contrast, there was an increase of alkaline phosphatase and persistence of elevated gamma-GT levels (Fig. 2A,B).

The native liver factor presented a poor separation of the increasing and decreasing components and showed a relatively horizontal time evolution in excretion after reaching  $T_{\max}$ . This was probably due to insufficient functional native liver recovery, unfortunately, no biopsy specimens were obtained to confront scintigraphic results with histologic findings.

The graft liver factor showed an impressive improvement and a clear component separation (18) with a rapid and steep uptake followed by a relatively prolonged excretion (Fig. 1).

The biliary factor was less typical in comparison with the second examination on Day 20. This could be due to the abdominal infection, that caused abnormalities in graft excretion and could correspond to increase of alkaline phosphatase (9).

### Fourth Examination: Day 63

We suggest that the stabilization of biochemical parameters, except the gamma-GT (Fig. 2A,B), which remains raised for many months after fulminant hepatic failure (23), is due to functional native liver recovery, while graft liver showed infection-induced dysfunction. No histologic findings, however, were available to confirm our hypothesis.

A typical native liver factor was extracted (16-18). We observed a rapid tracer accumulation in the uptake component and  $T_{\max}$  reached its peak (24,25) between 10 and 15 min after injection (Fig. 1).

In the graft liver, there was a minimal factor decrease in both components, mostly in the uptake. Furthermore, the intrahepatic biliary tree became visible and this scintigraphic finding let us assume the excretion abnormality in graft liver. It was shown that excretion is nonspecific and correlates with the severity of disease irrespective of its etiology (5,7,9,10). Infection, as a frequent finding in liver transplantation, especially when biliary obstruction and immuno-suppression are present, may cause abnormalities in excretion (8).

## CONCLUSION

This study demonstrates FAMIS advantages in four successive hepatobiliary studies within 63 days after auxiliary partial orthotopic liver transplantation by increasing the specificity and sensitivity of hepatobiliary imaging. Furthermore, FAMIS helps in interpretation of biochemical tests. If FAMIS is used, all scintigraphic information can be concentrated into three factor couples, which permits better characterization of the different hepatic parenchymas. This is of primary clinical interest, because the biochemical tests cannot separate them and other concurrent imaging methods lack sensitivity to monitor post-transplantation complications like graft liver rejection and infection.

Our study shows the native liver functional recovery potential in the patient suffering from fulminant hepatitis as well as graft liver function alterations due to complications requiring medical or surgical interventions.

## APPENDIX

### Basic Principles of FAMIS

FAMIS is a mathematical method which enables the representation of a dynamic series (sequences) of P images as a linear

function of a reduced set of images and related curves referred to as factor couples (factor images and factors or curves) (26).

From a factor image, I and a related curve with P values,  $C_1, C_2 \dots C_P$  we define the external product  $E = I \otimes C$  as a series of P images  $E_1, E_2 \dots E_P$ . The image  $E_k$  is obtained by multiplying the value of each pixel of the image I by the scalar value  $C_k$ .

Let  $S = S_1, S_2 \dots S_P$  be the original series of images. Its factor decomposition is based on the estimation of R factor images  $I^1 \dots I^R$  and R-related curves  $C^1 \dots C^R$ , which minimizes the Euclidian distance between the series:

$$S \text{ and } \sum_{r=1}^R I^r \otimes C^r. \quad \text{Eq. 1}$$

For obvious physiological reasons, the factor images and curves are bound to satisfy positivity constraints:

$\forall r = 1 \dots R$  each pixel of  $I^r$  has non-negative values,

$\forall r = 1 \dots R$  each values of  $C^r$  has non-negative values.

The estimation of the factor images and curves is a four-step method:

1. Pixel aggregation reduces the amount of data, statistical fluctuations and discard insignificant pixels. The pixels are aggregated in square regions ( $4 \times 4$ ) and for each region we compute the sum of the pixels in each image in the series. This yields a p-value vector referred to as "trixel". All trixels with a sum value lower than a predefined threshold are discarded.

2. R-dimensional linear subspace determination. Each pixel can be represented as a point in a P-dimensional space. If the original series is actually the combination of R factor images and related curves, the trixel points lie in a R-dimensional linear subspace as well as in the normalized R-1 dimensional subspace obtained after division of each trixel by its sum. The trixels are normalized and their variance-covariance matrix is computed. The R-1 dimensional factor subspace is referenced by the R-1 first eigenvectors of this matrix.

3. Factor estimation. The kinetics of curves or factors are searched as R particular points (apex points) of the factor subspace. The apex points must be inside the positivity area (due to the curve positivity constraints) and the original trixel series projected in the factor subspace must be inside the polyhedron of the apex points (image positivity constraints). The apex points estimation is performed by an iterative algorithm described by Barber et al. (14) and improved by Bazin et al. (15,26).

4. Factor image constitution. The kinetics of the original series are projected on the oblique frame of reference formed by the kinetics of the apex points. The projection values on apex k constitute the factor image k.

## ACKNOWLEDGMENT

We thank Christophe Jacquelin from INSERM U66 for technical assistance.

## REFERENCES

- Schafer DF, Byers WS. Fulminant hepatic failure and orthotopic liver transplantation. *Semin Liver Dis* 1989;9:189-194.
- Houssin D, Soubrane O, Boillot O, et al. Orthotopic liver transplantation with a reduced-size graft: an ideal compromise in pediatrics? *Surgery* 1992;111:532-542.
- Gubernatis G, Pichlmayr R, Kemnitz J, Gratz K. Auxiliary partial orthotopic liver transplantation for fulminant hepatic failure: first successful case report. *World J Surg* 1991;5:660-666.
- Brolsch CE, Stevens LH, Whittington PF. The use of reduced-size liver transplants in children, including split livers and living related liver transplants. *Eur J Pediatr Surg* 1991;1:166-171.
- Hawkins RA, Hall T, Gambhir SS, et al. Radionuclide evaluation of liver transplants. *Semin Nucl Med* 1988;18:199-212.
- Cosimi AB. Update of liver transplantation. *Transplant Proc* 1991;23:2083-2090.

7. Engeler CM, Kuni CC, Nakhleh RE, Engeler CE, duCret RP, Boudreau RJ. Liver transplant rejection and cholestasis: comparison of technetium-99m-diisopropyl iminodiacetic acid hepatobiliary imaging with liver biopsy. *Eur J Nucl Med* 1992;19:865-870.
8. Kuni CC, Engeler CM, Nakhleh RE, duCret RP, Boudreau RJ. Correlation of technetium-99m-DISIDA hepatobiliary studies with biopsies in liver transplant patients. *J Nucl Med* 1991;32:1545-1547.
9. Brunot B, Petras S, Germain P, Vinee P, Constantinesco A. Biopsy and quantitative hepatobiliary scintigraphy in the evaluation of liver transplantation. *J Nucl Med* 1994;35:1321-1327.
10. Loken MK, Ascher NL, Boudreau RJ, Najarian JS. Scintigraphic evaluation of liver transplant function. *J Nucl Med* 1986;27:451-459.
11. Buyck D, Bonnin F, Véra P, et al. Interest of hepatobiliary scintigraphy in follow-up of the auxiliary heterotopic liver transplantations [Abstract in french]. *J Med Nucl Biophys* 1994;18:259.
12. Victor G, Lloveras JJ, Nicolau A, et al. Mebrofenin quantitative hepatobiliary scintigraphy in liver transplant patients [Abstract]. *Eur J Nucl Med* 1992;19:690.
13. Aurengo A. Factor analysis of image sequences in nuclear medicine [Thesis in french]. Orsay, France: Université de Paris-Sud, 1989. 457.
14. Barber D, Martel A. Factor analysis revisited. *Eur J Nucl Med* 1992;19:467-468.
15. Di Paola R, Bazin JP, Aubry F, et al. Handling of dynamic sequences in nuclear medicine. *IEEE Trans Nucl Sci* 1982;29:1310-1321.
16. Darcourt J, Lapalus F. Performances of factorial analysis in hepatobiliary imaging: assessment of the pharmacological effect of somatostatin in normal subjects. *IUG Newsletter* 1987;4:11-14.
17. Herry JY, Bazin JP, Bourguet P, Di Paola M, et al. Factor analysis of dynamic scintigraphic structures. Applications to kinetics of hepatobiliary tracers. Raynauld C, ed. In: *Nuclear Medicine and Biology*. Pergamon Press, Paris; 1980:2240-2243.
18. Herry JY. Compartmental analysis and functional analysis of dynamic structures in scintigraphy; application to the hepatobiliary system [Thesis in french]. Orsay, France: Université de Paris-Sud, 1982. 257.
19. Billotey C, Aurengo A, Najean Y, Sarfati E, Moretti JL, Toubert ME, Rain JD. Identifying abnormal parathyroid glands in the thyroid uptake area using technetium-99m-sestamibi and factor analysis of dynamic structures. *J Nucl Med* 1994;35:1631-1636.
20. Le D, Frouin F, Kotzev G, Di Paola R. Motion correction for the automated analysis of functional MR studies. In: Hoffman EA, ed. *Physiology and function from multidimensional images*. 1995;248-259.
21. Brunt EM, Peters MG, Flye MW, Hanto DW. Day 5 protocol liver allograft biopsies document early rejection episodes and are predictive of recurrent rejection. *Surgery* 1992;111:511-517.
22. Cuervas-Mons V, Menéndez J, Barrios C, et al. Value of histologic findings in predicting the response to treatment of acute graft rejection after liver transplantation. *Transplant Proc* 1991;23:1972.
23. Houssin D, Soubrane O, Ozier Y. La transplantation hépatique. Lang P, Houssin D, eds. In: *La transplantation d'organes*. Masson, Paris; 1991:105-128.
24. Boyd R, Stadalnik R, Barnett C, Hines H. Quantitative hepatic scintigraphy. *Clin Nucl Med* 1978;3:478-484.
25. Gilbert SA, Brown PH, Krishnamurthy GT. Quantitative nuclear hepatology. *J Nucl Med Technol* 1987;15:38-43.
26. Frouin F, Bazin JP, Di Paola M, Jolivet O, Di Paola R. FAMIS: a software package for functional feature extraction from biomedical multidimensional images. *Comp Med Imaging Graph* 1992;16:81-91.

### CORRECTION

In the December 1995 issue of *JNM* (pp. 2248-2251), the author listing for the article, "Technetium-99m-Tetrofosmin Imaging in a Patient with Differentiated Mixed Thyroid Cancer," by Klain et al. was printed incorrectly. The correct listing is: M. Klain, S. Maurea, S. Lastoria, A. Cuocolo, A. Colao, G. Lombardi and M. Salvatore.