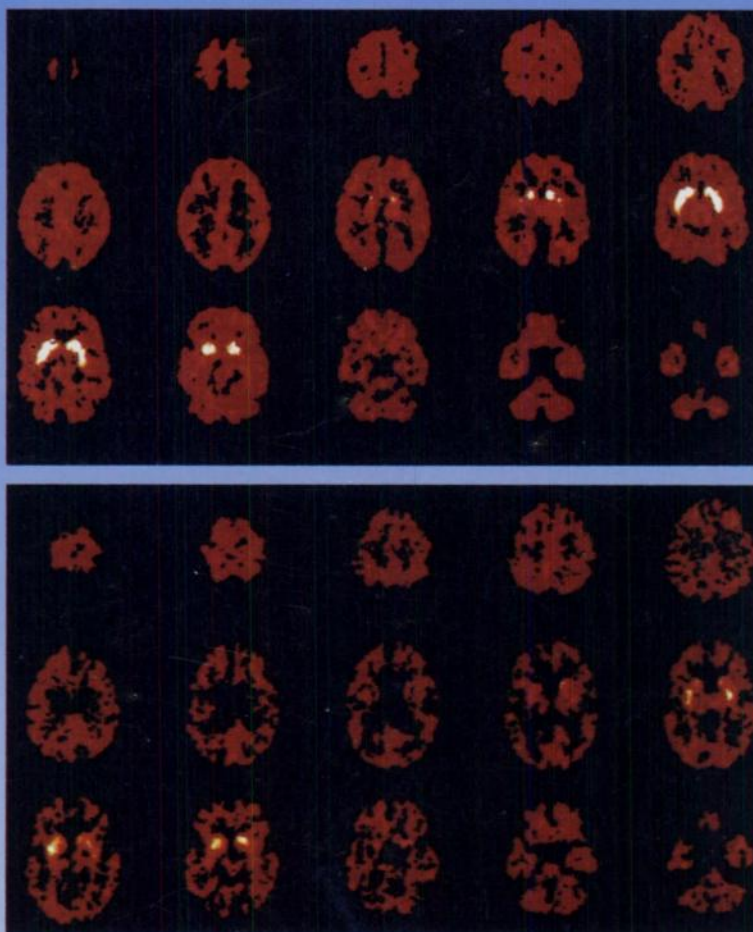

The Journal of Nuclear Medicine

JNM

Volume 37, Number 4 • April 1996



Distribution volume (DV) maps of [^{11}C]d-threo-methylphenidate in the brains of a 34-yr-old (top) and a 68-yr-old (bottom) subject. Significant decreases in the DV in the striatal regions of the older subject are observed compared to the younger one. Images from these subjects are normalized with respect to each other. See pages 554-559.



The Official Publication of
the Society of Nuclear Medicine, Inc.
