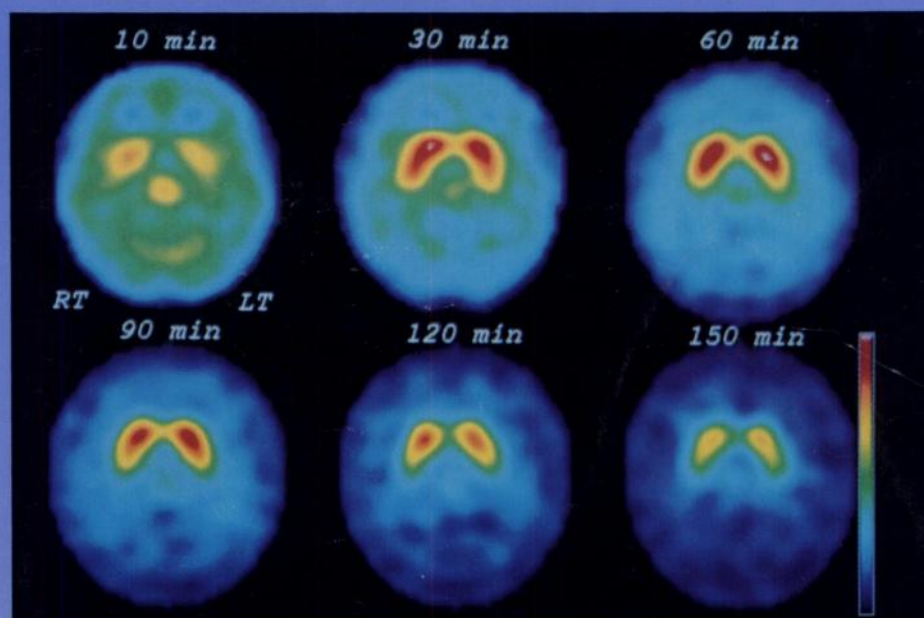

The Journal of Nuclear Medicine

JNM

Volume 37, Number 3 • March 1996



Serial transaxial ^{123}I -iodobenzofuran (IBF) SPECT images (10-150 min postinjection) in the striatum of a 19-yr-old woman. The basal ganglia IBF peaked at 48 min just prior to the 60-min image, followed by a specific binding peak during the 90-min scan. See pages 513-520.



The Official Publication of
the Society of Nuclear Medicine, Inc.
