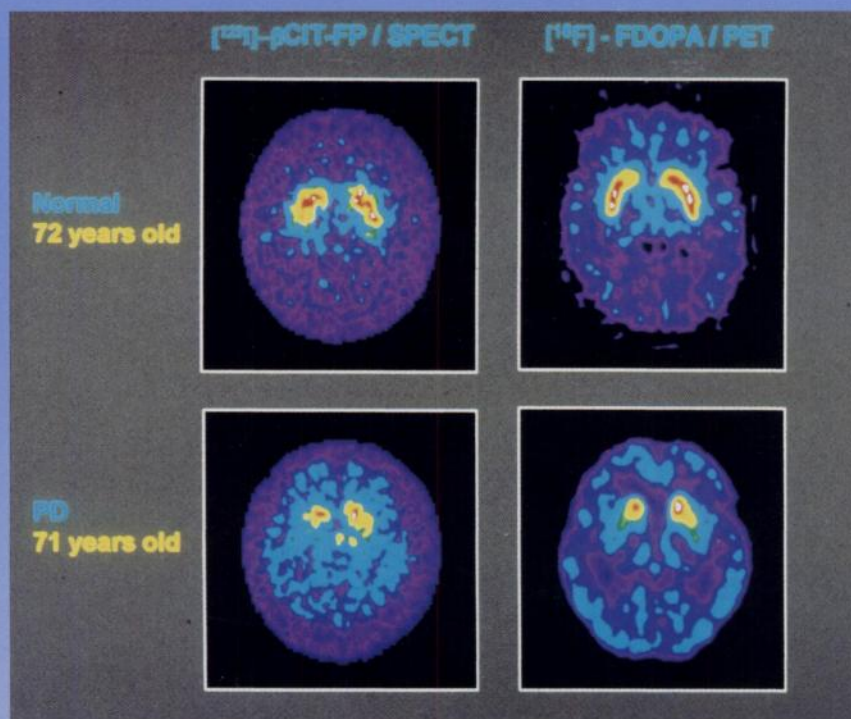

The Journal of Nuclear Medicine

JNM

Volume 37, Number 11 • November 1996



Iodine-123- $\beta\text{CIT-FP}$ and $[^{18}\text{F}]\text{FDOPA}$ transverse tomographic images in an age-matched normal volunteer and a patient with Parkinson's disease. See pages 1760-1765.



The Official Publication of
the Society of Nuclear Medicine, Inc.
