ACKNOWLEDGMENT

This work was supported in part by a syndicated research and development project grant to Tetley Research Pty Ltd.

REFERENCES

1. Scalzetti EM, Gagne GM. The transition from technegas to pertechnegas. *J Nucl Med* 1995;36:267–269.
2. Monaghan P, Murray IPC, Mackey DWJ, et al. An improved radionuclide technique for the detection of altered pulmonary permeability. *J Nucl Med* 1991;32:1945–1949.

W.M. Burch
R.J. Browitt
Australian National University
Canberra, Australia

Normal Glucose Uptake by Tongue and Pharyngeal Muscles in FDG-PET Imaging

TO THE EDITOR: In the article by Lauenbacher et al. (*1*), Figure 2 shows a PET scan of the head and neck in a patient with squamous-cell cancer of the oropharynx. The sagittal image is similar to an image we recently obtained in a patient without malignancy (Fig. 1). The study showed intense glucose uptake in the tongue, salivary glands and facial muscles. The patient, unknown to us at the time, chewed gum while waiting to be scanned. There can be considerable normal glucose uptake in the tongue, pharyngeal muscles and larynx when patients continue to talk after an injection of FDG. This physiologic activity can be problematic when looking for signs of malignancy. Since that time, we have not only restricted gum but have also requested patients to refrain from talking, drinking water or coughing for 30 min after the FDG injection. The result is a marked decrease in glucose uptake by the tongue and other structures (Fig. 2).

Lauenbacher et al. do not mention whether the patients in their study were instructed not to talk, chew, drink or cough. It would be interesting to know the authors' observations in patients who continue to talk after injection of FDG. I suspect most patients are not advised that "silence is golden."

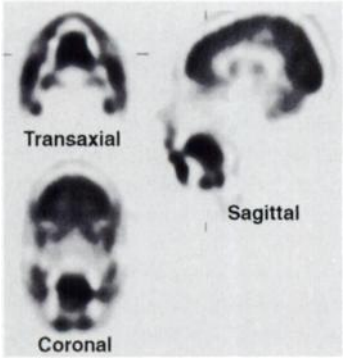

FIGURE 1. FDG-PET scan in a 38-yr-old man with a benign pulmonary nodule. There is high glucose uptake in the tongue, salivary glands and facial muscles due to chewing gum after the FDG injection.

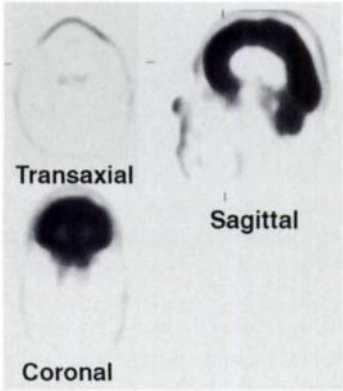

FIGURE 2. FDG-PET scan in a 66-yr-old man with persistent hoarseness and edematous larynx but negative biopsies for malignancy. The patient was instructed to remain silent for 30 min after FDG injection. Little glucose activity is seen in the tongue or other organs.

REFERENCE

1. Laubenbacher C, Saumweber D, Wagner-Manslau C, et al. Comparison of fluorine-18-fluorodeoxyglucose PET, MRI and endoscopy for staging head and neck squamous-cell carcinomas. *J Nucl Med* 1995;36:1747–1757.

George M. Segall
Department of Veterans Affairs Medical Center
Palo Alto, California

REPLY: As demonstrated by Jabour and colleagues (*1*) and in our article (*2*), FDG accumulation in normal mucosa, the tongue, salivary glands and facial muscles is a common finding. The intensity of this accumulation may be influenced by chewing gum, coughing or drinking water, as stated by Segall in his letter. Segall emphasizes that we did not mention whether our patients were instructed not to talk, chew, drink or cough. Since we performed dynamic imaging with prior transmission scanning, our patients were requested to minimize head motion, including no talking, drinking or chewing. Nevertheless, we noticed relatively high ^{18}F activity in various structures of the naso- and oropharynx.

Since T-staging of head and neck tumors and, therefore, the choice of therapy are based on morphological information, the nonspecific ^{18}F activity, which blurred the borders of the tumor, was responsible for the overstaging in our patient population. Thus, T-staging of head and neck tumors will remain in the realm of morphologic techniques, including endoscopy, x-ray computed tomography and magnetic resonance tomography.

However, the main diagnostic problem in these patients is the accurate detection of involved lymph nodes or neck sides. For this indication, the nonspecific FDG accumulation in the naso- and oropharynx did not affect the diagnostic accuracy, resulting in a negative predictive value (NPV) of 98% for individual lymph nodes and an NPV of 89% for involved neck sides.

Christian Laubenbacher
Markus Schwaiger
Technical University of Munich
Munich, Germany

REFERENCES

1. Jabour BA, Choi Y, Hoh CK, et al. Extracranial head and neck: PET imaging with 2-[^{18}F]fluoro-2-deoxy-D-glucose and MR imaging correlation. *Radiology* 1993;186:27–35.
2. Laubenbacher C, Saumweber D, Wagner-Manslau C, et al. Comparison of fluorine-18-fluorodeoxyglucose PET, MRI and endoscopy for staging head and neck squamous-cell carcinomas. *J Nucl Med* 1995;36:1747–1757.

Septal Metabolic Mismatch in LBBB

TO THE EDITOR: I was very interested to read the report of metabolic mismatch of septal beta-oxidation and glucose utilization in left bundle branch block assessed with PET by Altehoefer et al. (*1*). Their finding is entirely consistent with results of the cited experimental study of Ono et al. (*2*). Fluorine-18-FDG uptake is a widely held standard of myocardial viability. If left bundle branch block poses an exception to its application, then the mechanism underlying this mismatch is essential to our understanding (and acceptance of this use) of FDG.

Altehoefer et al. commented that "the impaired septal [^{18}F]FDG uptake observed in our patient does not appear to have been caused by reduced substrate demand." Lack of evidence is not proof. In our study of patients with left bundle branch block using ^{201}Tl, we hypothesized that decreased perfusion of the interventricular septum occurs during exercise due to asynchrony of left ventricular contraction, so that (at least) in early systole, the septum generates sufficient tension to overcome only right ventricular

outflow resistance, resulting in decreased interventricular septal oxygen demand (*3*).

A similar hypothesis was considered by Ono et al. (*2*) who wrote "...there is the possibility that oxygen demand in the septum is decreased because of reduced thickening..." but they dismissed this on the basis of increased intramyocardial pressure during the phase of the cardiac cycle incorporating the major component of left anterior descending flow ("...suggesting that an asynchronous but reserved myocardial contraction was occurring). In their Figure 5, simultaneous coronary flow and intramyocardial pressure tracings are displayed without registration to the electrocardiogram. During pacing-induced left bundle branch block, two phenomena are illustrated. First, mean intramyocardial pressure rises, consistent with tachycardia-induced decrease in left ventricular dimensions and increase in myocardial thickness and compression (*4*). Second, phasic increase in intramyocardial pressure in the septum is more synchronous with the major component of left anterior descending coronary flow. It is consistent with measured thallium uptake that this component of coronary flow is predominantly to nonseptal left ventricular segments. That septal intramyocardial pressure is dramatically "out of phase" with this flow is explicable if the QRS complex duration is long (e.g., 150 msec.) in relation to the paced R-R interval (e.g., 300 msec.). This would result in sufficient ventricular asynchrony to cause a large "phase shift" in intramyocardial pressure of the septum. In this way, left anterior descending flow is maximal during relaxation of the left ventricular free wall and contraction of the septum. That the septum may in effect function more as a wall of the right rather than the left ventricle and have a lower metabolic demand is thereby well illustrated by this work.

I accept the important findings that coronary flow to and metabolic activity of the intraventricular septum are reduced in left bundle branch block without evidence of ischemia. Perhaps diminished glucose uptake does in fact reflect decreased septal metabolic demand as the proximate cause of its diminished perfusion in left bundle branch block. How this might affect the utility of glucose uptake to evaluate the viability of hibernating and other myocardial segments with asynchronous activation is an intriguing subject for conjecture and further investigation.

REFERENCES

1. Altehoefer C, vom Dahl J, Bares R, Stocklin GL, Bull U. Metabolic mismatch of septal beta-oxidation and glucose utilization in left bundle branch block assessed with PET. *J Nucl Med* 1995;36:2056–2059.
2. Ono S, Nohara R, Kambara H, Okuda K, Kawai C. Regional myocardial perfusion and glucose metabolism in experimental left bundle branch block. *Circulation* 1992;85: 1125–1131.
3. Burns RJ, Galligan L, Wright LM, Lawand S, Burke R, Gladstone PJ. Improved specificity of myocardial thallium-201 single-photon emission computed tomography in patients with left bundle branch block by dipyridamole. *Am J Cardiol* 1991;68: 504–508.
4. Wigger CL. The interplay of coronary vascular resistance and myocardial compression in regulating coronary flow. *Circ Res* 1954;2:271–278.

R.J. Burns
University of Toronto
Toronto, Ontario, Canada

Double-Phase Technetium-99m-Sestamibi Scanning to Evaluate Nodular Thyroid Malignancy

TO THE EDITOR: In a recent article, Vattimo et al. (*1*) reported on double-phase thyroid scintigraphy with ^{99m}Tc-MIBI in patients with cold solitary nodules (*1*). They found that the technique could identify patients with Hürthle cell tumors showing persistent uptake on the late image (3–4 hr postinjection). In contrast, papillary and folliculary malignant nodules showed complete washout. Moreover, they concluded that persistent MIBI uptake seems to be characteristic of the Hürthle cell tumors.

In our own experience, double-phase scanning of the thyroid gland with ^{99m}Tc-MIBI at 2 hr is a useful test to evaluate single thyroid nodules. The nodular retention of the radiotracer on delayed images at 2 hr postinjection is an indicator of malignancy regardless the histological type of the lesion (Fig. 1).

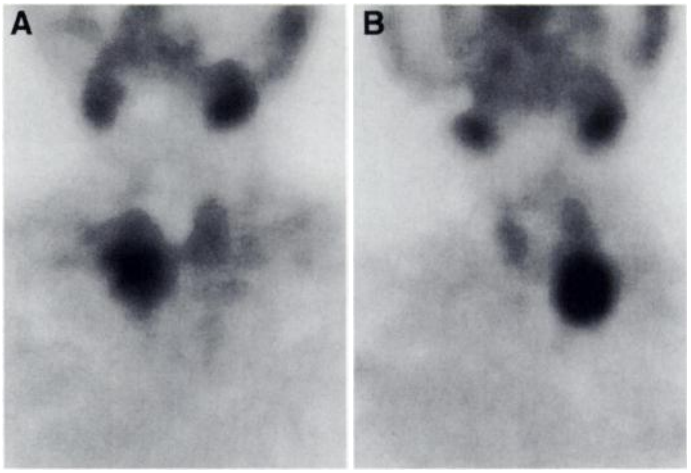

FIGURE 1. Two-hour delayed MIBI image reveals nodular retention of the radiotracer in malignant papillary (A) and follicular lesions (B).

Vattimo et al. also stated that Földes et al. (*2*) performed the double-phase technique with results similar to theirs. These authors, however, acquired delayed images at 1 hr postinjection in 10 of 58 patients, including many with multinodular goiter.

Although more experience is needed to evaluate the diagnostic accuracy of the test, we believe that nodular washout of radiotracer in malignant papillary and folliculary nodules is not observed if late images are acquired at 2 hr postinjection.

REFERENCES

1. Vattimo A, Bertelli P, Cintorino M, Burroni L, Volterrani D, Vella A. Identification of Hürthle cell tumor by single-injection, double-phase scintigraphy with technetium-99m-sestamibi. *J Nucl Med* 1995;36:778–782.
2. Földes I, Lévay A, Stotz G. Comparative scanning of thyroid nodules with technetium-99m-pertechnetate and technetium-99m-methoxyisobutylisonitrile. *Eur J Nucl Med* 1993;20:330–333.

Omar Alonso
Fernando Mut
Graciela Lago
Clinical Hospital of the University of Uruguay
Montevideo, Uruguay

REPLY: We thank Alonso et al. for their interest in our article (*1*). We observed that Hürthle cell tumors (HCT) take up and retain ^{99m}Tc-sestamibi (MIBI), in contrast with other thyroid tumors that take up and release the tracer. Therefore, we believe that single-injection, double-phase (15–30 min and 3–4 hr p.i.) scintigraphy with MIBI can detect cold thyroid nodules bearing HCT. MIBI uptake by thyroid nodules is related to vascularity and cellularity (*2*), but its retention is mainly related to mitochondrial concentration (*3*) and secondarily to the initial uptake: As a result, visual interpretation could be misleading since the retention could be either true or apparent according to the washout rate. For this reason, we calculated the washout rate and the nodule-to-thyroid uptake ratio (N/T). We observed HCTs that exhibited a slow washout rate (<20% h^{-1} and increased N/T in comparison with other thyroid tumors presenting high washout rates (>20% h^{-1}) and decreased N/T. This scintigraphic pattern is related to a hystopathological feature of such tumors (high density of oxyphilic cells due to crowded mitochondria).

We are not surprised by the observations of Alonso et al., since a similar case has already been reported by Taillefer et al. (*4*). We also observed cases of non-HCTs exhibiting delayed retention of MIBI (adenoma and follicular carcinoma). In such patients, the N/T decreased and the washout rate was high (>20% h^{-1}) so that their retention was quite apparent (Fig. 1). However, we are indebted to Alonso et al. for their observation, which we will consider in the evaluation of future patients.