

ACKNOWLEDGMENT

This work was supported in part by a syndicated research and development project grant to Tetley Research Pty Ltd.

REFERENCES

1. Scalzetti EM, Gagne GM. The transition from technegas to pertechnegas. *J Nucl Med* 1995;36:267-269.
2. Monaghan P, Murray IPC, Mackey DWJ, et al. An improved radionuclide technique for the detection of altered pulmonary permeability. *J Nucl Med* 1991;32:1945-1949.

W.M. Burch

R.J. Browitt

Australian National University
Canberra, Australia

Normal Glucose Uptake by Tongue and Pharyngeal Muscles in FDG-PET Imaging

TO THE EDITOR: In the article by Lauenbacher et al. (1), Figure 2 shows a PET scan of the head and neck in a patient with squamous-cell cancer of the oropharynx. The sagittal image is similar to an image we recently obtained in a patient without malignancy (Fig. 1). The study showed intense glucose uptake in the tongue, salivary glands and facial muscles. The patient, unknown to us at the time, chewed gum while waiting to be scanned. There can be considerable normal glucose uptake in the tongue, pharyngeal muscles and larynx when patients continue to talk after an injection of FDG. This physiologic activity can be problematic when looking for signs of malignancy. Since that time, we have not only restricted gum but have also requested patients to refrain from talking, drinking water or coughing for 30 min after the FDG injection. The result is a marked decrease in glucose uptake by the tongue and other structures (Fig. 2).

Lauenbacher et al. do not mention whether the patients in their study were instructed not to talk, chew, drink or cough. It would be interesting to know the authors' observations in patients who continue to talk after

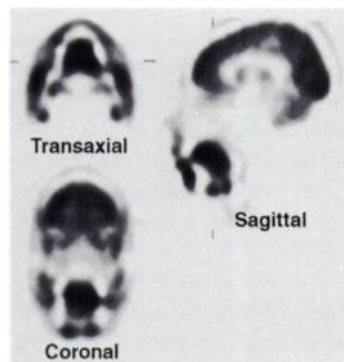


FIGURE 1. FDG-PET scan in a 38-yr-old man with a benign pulmonary nodule. There is high glucose uptake in the tongue, salivary glands and facial muscles due to chewing gum after the FDG injection.

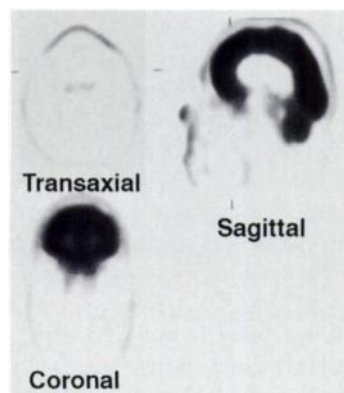


FIGURE 2. FDG-PET scan in a 66-yr-old man with persistent hoarseness and edematous larynx but negative biopsies for malignancy. The patient was instructed to remain silent for 30 min after FDG injection. Little glucose activity is seen in the tongue or other organs.

injection of FDG. I suspect most patients are not advised that "silence is golden."

REFERENCE

1. Laubenbacher C, Saumweber D, Wagner-Manslau C, et al. Comparison of fluorine-18-fluorodeoxyglucose PET, MRI and endoscopy for staging head and neck squamous-cell carcinomas. *J Nucl Med* 1995;36:1747-1757.

George M. Segall

Department of Veterans
Affairs Medical Center
Palo Alto, California

REPLY: As demonstrated by Jabour and colleagues (1) and in our article (2), FDG accumulation in normal mucosa, the tongue, salivary glands and facial muscles is a common finding. The intensity of this accumulation may be influenced by chewing gum, coughing or drinking water, as stated by Segall in his letter. Segall emphasizes that we did not mention whether our patients were instructed not to talk, chew, drink or cough. Since we performed dynamic imaging with prior transmission scanning, our patients were requested to minimize head motion, including no talking, drinking or chewing. Nevertheless, we noticed relatively high ^{18}F activity in various structures of the naso- and oropharynx.

Since T-staging of head and neck tumors and, therefore, the choice of therapy are based on morphological information, the nonspecific ^{18}F activity, which blurred the borders of the tumor, was responsible for the overstaging in our patient population. Thus, T-staging of head and neck tumors will remain in the realm of morphologic techniques, including endoscopy, x-ray computed tomography and magnetic resonance tomography.

However, the main diagnostic problem in these patients is the accurate detection of involved lymph nodes or neck sides. For this indication, the nonspecific FDG accumulation in the naso- and oropharynx did not affect the diagnostic accuracy, resulting in a negative predictive value (NPV) of 98% for individual lymph nodes and an NPV of 89% for involved neck sides.

Christian Laubenbacher

Markus Schwaiger

Technical University of Munich
Munich, Germany

REFERENCES

1. Jabour BA, Choi Y, Hoh CK, et al. Extracranial head and neck: PET imaging with 2- ^{18}F fluoro-2-deoxy-D-glucose and MR imaging correlation. *Radiology* 1993;186:27-35.
2. Laubenbacher C, Saumweber D, Wagner-Manslau C, et al. Comparison of fluorine-18-fluorodeoxyglucose PET, MRI and endoscopy for staging head and neck squamous-cell carcinomas. *J Nucl Med* 1995;36:1747-1757.

Septal Metabolic Mismatch in LBBB

TO THE EDITOR: I was very interested to read the report of metabolic mismatch of septal beta-oxidation and glucose utilization in left bundle branch block assessed with PET by Althoefer et al. (1). Their finding is entirely consistent with results of the cited experimental study of Ono et al. (2). Fluorine-18-FDG uptake is a widely held standard of myocardial viability. If left bundle branch block poses an exception to its application, then the mechanism underlying this mismatch is essential to our understanding (and acceptance of this use) of FDG.

Althoefer et al. commented that "the impaired septal [^{18}F]FDG uptake observed in our patient does not appear to have been caused by reduced substrate demand." Lack of evidence is not proof. In our study of patients with left bundle branch block using ^{201}Tl , we hypothesized that decreased perfusion of the interventricular septum occurs during exercise due to asynchrony of left ventricular contraction, so that (at least) in early systole, the septum generates sufficient tension to overcome only right ventricular