
The VEX-Test for Myocardial Scintigraphy with Thallium-201 and Sestamibi: Effect on Abdominal Background Activity

Gilbert A. Hurwitz, Shehab Saddy, J. Paul O'Donoghue, Soraya A. Ali, John E. Powe, Mariwan Husni and Denis R. Gravelle

Departments of Diagnostic Radiology/Nuclear Medicine and Medicine, University of Western Ontario and Victoria Hospital, London, Ontario, Canada

High abdominal background activity of ^{99m}Tc -sestamibi may interfere with the diagnosis in studies in which a coronary vasodilator is used; supplemental dynamic exercise might reduce this problem. **Methods:** Clinical and angiographic determinants of subdiaphragmatic-to-myocardial activity ratios were measured on immediate poststress left anterior oblique images and on corresponding tomographic studies 1 hr after injection in 600 sestamibi studies. Similar measurements were made in 550 historic controls with planar ^{201}Tl imaging. Patients performed symptom-limited ergometry when there were no limiting factors, dipyridamole-handgrip in which ergometry was not possible and VEX (vasodilator followed by symptom-limited ergometry) in which exercise capacity was reduced. **Results:** Abdominal activity was higher with sestamibi than with ^{201}Tl , in women versus men, and with dipyridamole-based tests compared to exercise alone. Compared to the dipyridamole-handgrip, 3 min of ergometry as part of VEX decreased abdominal background ($p \leq 0.02$) by 18% on immediate ^{201}Tl images, by 13% on immediate sestamibi images and by 12% on 1-hr delayed sestamibi tomographic acquisitions. **Conclusion:** Poststress abdominal background activity is influenced by similar factors with both agents. Supplemental exercise following dipyridamole reduces potentially interfering abdominal activity but perhaps not as efficiently with sestamibi as with ^{201}Tl .

Key Words: technetium-99m-sestamibi; thallium-201; dipyridamole; exercise supplementation; stress test; myocardial perfusion

J Nucl Med 1995; 36:914-920

Developments in stress testing have resulted in a spectrum of procedures which are available for the scintigraphic assessment of myocardial perfusion (1). A significant proportion of patients referred for scintigraphic procedures is unable to exercise optimally. For evaluation of these patients, pharmacologic vasodilation with intrave-

nous dipyridamole was developed in the 1970s (2); it has subsequently been shown to be a safe and effective tool in the diagnosis of coronary artery disease (3-6).

Although the sensitivity and specificity of dipyridamole-thallium scintigraphy have been shown to be acceptable (4-7), there are several limitations to vasodilator studies from both the clinical and imaging standpoints. Washout analysis may be less helpful following dipyridamole than following exercise stress (8). Abdominal background activity may be high enough (9) to interfere with interpretation of inferior wall activity. Testing with a vasodilator alone or with supplemental handgrip (10) also limits the assessment of physiologic indicators, e.g., chest pain and ST depression which can be discerned more readily with dynamic exercise testing (11); such exercise-derived variables may be synergistic with imaging parameters in the determination of diagnosis or prognosis (12).

A stress-modality combining dynamic exercise with vasodilator (VEX) has several potential advantages, suggesting its more widespread employment in conjunction with scintigraphy (13,14). These include a higher incidence of induced scintigraphic defects and a higher incidence of ST depression when compared to dipyridamole alone (14-16), or when compared to dynamic exercise alone (17-19). When combined with the assessment of segmental motion, as with echocardiography (19), or with gated myocardial scintigraphy (20), the VEX procedure may have an advantage over either exercise or dipyridamole alone in showing stress-induced ischemic dysfunction. The addition of exercise to dipyridamole improves the pharmacologically-based tests performed with ^{201}Tl imaging and has a beneficial effect with respect to washout characteristics (21) and abdominal background activity (9,14-17,22). With ^{99m}Tc -sestamibi, abdominal background activity, at least immediately after injection, is higher than with ^{201}Tl (23), thus attempts to decrease interfering abdominal activity with sestamibi (24) may be even more pertinent with sestamibi than with ^{201}Tl .

In this study, we evaluated factors contributing to abdominal background activity on immediate poststress images with sestamibi as well as with ^{201}Tl . Our aim was to

Received May 6, 1994; revision accepted Jan. 3, 1995.

For correspondence or reprints contact: Dr. Gilbert A. Hurwitz, Department of Nuclear Medicine, Victoria Hospital, 375 South St., London, Ontario, Canada N6A 4G5.

TABLE 1
Scheme to Assign Patients to a Stress-Testing Modality

Pretest evaluation (Capacity for ergometry)	Test selection	
	Dipyridamole	Exercise
Optimal	No	Symptom-limited ergometry
Limited—physical	Yes	Ergometry
Limited—pharmacological	Yes	Ergometry
Not possible	Yes	Isometric exercise

quantitate the level of dynamic exercise necessary for improved image quality and to determine other factors that might contribute to abdominal background activity.

METHODS

Patients

Patients were referred for stress myocardial perfusion imaging May 1985 to October 1993. This report focuses on studies performed with two different imaging modalities: planar ^{201}Tl imaging (performed routinely until March 1990) and tomographic sestamibi imaging. After April 1992, all sestamibi studies had an ancillary poststress ECG-gated planar image acquired for 2 min in the left anterior oblique projection (LAO) (25), facilitating assessment of image quality with sestamibi. Studies were divided into three series based on clinical use of the test by referring physicians.

Angiographically correlated cases included all patients who had coronary angiography, including contrast ventriculography, at Victoria Hospital within 4 mo of scintigraphy, unless they met specific exclusion criteria. Diagnostic assessments in these patients (including stress electrocardiography, thallium scintigraphy and coronary angiography) were performed based on the usual clinical indications, i.e., investigation of chest pain. Patients were excluded if: (1) invasive studies suggested valvular disease or nonischemic cardiomyopathy or (2) any test was performed within 1 wk of myocardial infarction. A second series of patients had previously undergone revascularization with either coronary bypass grafting or angioplasty. Patients who did not fall into either of the first two series were considered as having "routine" indications for scintigraphy. Patients were excluded from this latter category if angiography had been performed within the previous 2 yr at Victoria Hospital or at another institution.

Selection and Performance of Stress Techniques

Patients were assigned to a testing procedure based on clinical indications (Table 1) according to the protocol described in previous studies (14,26). Briefly, the selection system was designed to optimize the stress test for all patients whether or not they could perform bicycle exercise. If exercise alone was adequate, supine ergometry was performed to a symptomatic endpoint. If it was estimated that the patient could not exercise optimally, intravenous dipyridamole was administered followed by handgrip exercise (if no ergometry could be performed) or by ergometry to the point of symptoms. Intravenous dipyridamole administration and "VEX", the combined testing mode (Fig. 1), were performed according to previous description (14). Exercise was continued for at least 1 min (27) after tracer injection (a longer wind-down period was used for sestamibi than for ^{201}Tl), and the LAO 40° image was acquired 4 min later.

Scintigraphic Protocol

This study focuses on the LAO 40° view which was begun at 4 min after peak exercise. Immediate poststress and delayed images with ^{201}Tl were obtained in three projections for 6–8 min each as previously described (14). For sestamibi, a dose of 12 MBq/kg body weight was injected at peak stress, and immediate poststress images were acquired for 2 min (Fig. 2). Poststress tomographic sestamibi images were acquired with thirty-two 30-sec stops in a 180° acquisition starting at 1 hr postinjection. Corresponding rest images with sestamibi were preferentially performed on a subsequent day, or, if required, on the same day as the stress procedures with 25% of the stress dose (3 MBq/kg). High-fat feedings after sestamibi injection were not used in this study (24).

Cardiac Catheterization

Coronary artery stenoses were assessed by a cardiovascular radiologist blinded to the perfusion imaging results. Any of the three main coronary arteries were considered diseased if a 50% stenosis was present; a left mainstem stenosis was considered comparable to two diseased arteries. Ventricular function was graded on contrast ventriculography from 1 to 5 as previously described (14,26).

Quantitation of Abdominal Uptake

Quantitation of abdominal uptake with ^{201}Tl was performed for all patients with angiographic correlation ($n = 550$). For sestamibi, a comparable number of cases ($n = 600$) was accumulated by including both angiographically correlated and postrevascularization cases (Table 2). For a few of the patients studied with sestamibi, the stress tomographic acquisition data file was not archived, thus the results for the delayed images were available in only 272 angiographically correlated cases. Regions of interest were outlined by the operator over the segment of myocardium and in a crescentic region below the heart were the segment of myocardium with the most intense uptake and a crescentic region below the myocardium (14), similar to regions used by other groups (16). On tomographic sestamibi reconstructions, myocardial activity was measured on midventricular short-axis slices; a rectangular region separated by 2 pixels from the inferior wall of the myocardium was used to represent abdominal activity. Results are given as the ratio (A/M) of mean count density in the abdominal region to mean count density in the myocardial region. Correlation coefficients for replication of A/M measurements were 0.98 for immediate thallium images, 0.91 for immediate sestamibi images, 0.98 for delayed planar acquisitions with sestamibi and 0.93 for short-axis slices with sestamibi.

Calculation of A/M for sestamibi is shown for two patients in Figure 2. Patient A performed ergometry alone to a workload of 900 kpm and heart rate of 160. High uptake of sestamibi (25) is evident on the immediate image. Both patients were men with a history of angioplasty following myocardial infarction. Sestamibi procedures were performed to assess recurrent symptoms.

Statistical Methods

Multiple regression methods were used to analyze determinants of abdominal uptake. The contribution evaluated (28) dipyridamole administration, exercise level, gender, number of diseased coronary arteries, ventricular function, history of infarction and hypertension. The clinical variables were categorized as in previous studies (26). To evaluate the principal determinants of abdominal background by analysis of variance, patients were categorized by testing modality and gender. Specific means were then compared by the Newman-Keuls procedure (28).

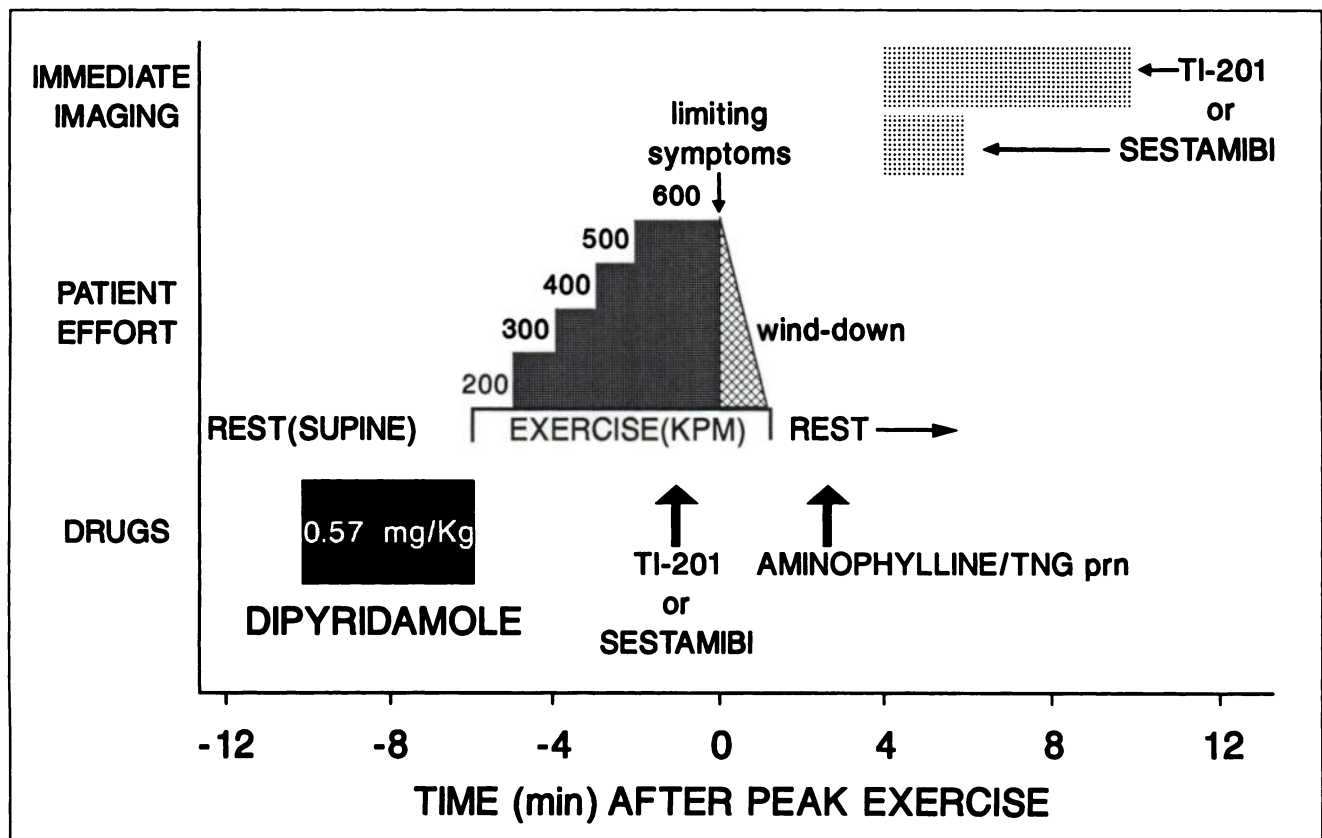


FIGURE 1. Protocol for performing stress scintigraphy with the VEX test. Following the standard intravenous dose of dipyridamole, supine ergometry was commenced immediately with progressive increases in workload every minute. When limiting symptoms occurred, as arbitrarily shown here at a workload of 600 kpm, the perfusion tracer (^{201}Tl or sestamibi) was injected rapidly, exercise continued for at least another minute (27) and the exercise level was then decreased for a wind-down period. Imaging was begun in the LAO projection at 4 min after the end of peak exercise.

RESULTS

In our laboratory, frequent use is made of intravenous dipyridamole in conjunction with myocardial scintigraphy

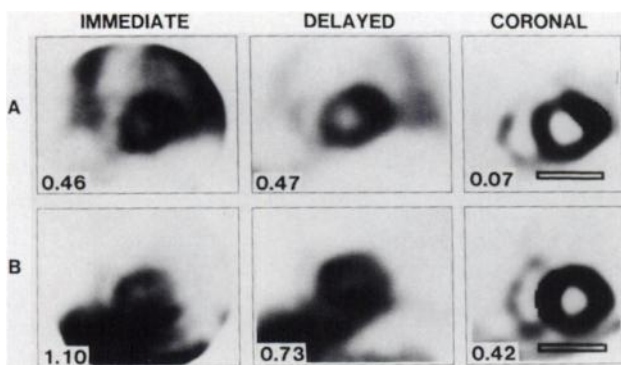


FIGURE 2. Abdominal background with sestamibi for immediate poststress images (left column), corresponding LAO tomographic slices (middle column) and for reconstructed midventricular short-axis slices (right column). In each case, mean count density in a subdiaphragmatic crescent is compared to the mean count density in a myocardial segment; regions of interest are shown here only for the tomographic slices. Abdominal-to-myocardial ratios for each of these images is shown in the lower left corner.

because referred patients are often unable to exercise to an adequate endpoint (Table 2). The addition of at least some ergometry could be performed in over 85% of patients requiring dipyridamole (Table 3). Of the 3700 studies reviewed (Table 2), the combination of intravenous dipyridamole and ergometry accounted for almost 50% of the total stress procedures.

A/M showed wide variation among subjects for each radiotracer/imaging protocol, but was greater for sestamibi than ^{201}Tl (Fig. 3). A/M was generally dependent on the level of exercise performed. In comparison to studies using dipyridamole and isometric handgrip exercise, a significant decrease in A/M was seen when more than 400 kpm (3 min of progressive ergometry) was added to the procedure; the decrement reached a high level of statistical significance on immediate images with both thallium (Fig. 4) and sestamibi (Fig. 5) and could still be discerned on 1-hr delayed sestamibi images. With higher levels of exercise after dipyridamole, abdominal background activity was similar to that seen with ergometry alone (Figs. 4, 5). For most categories of stress, A/M was higher in women than in men for imaging with ^{201}Tl (Fig. 4); a similar gender difference was observed with sestamibi.

By regression analysis (Table 4), a number of factors

TABLE 2
Review of Myocardial Perfusion Studies: Use of Dipyridamole

	Angiographic correlation	Revascularization	Routine diagnostic	Total
	No	Yes	No	
Prior CABG or angioplasty	Within 4 mo	Possible	None in previous 2 yr	
Correlating angiogram				
Planar Thallium Series				
Dates	Apr '85–Mar '90	Apr '85–Apr '90	Apr '85–Apr '90	
Total tests—number	550*	425	1525	2500
Dipyridamole—number	359	245	785	1389
Percentage	65%	58%	51%	56%
Tomographic Sestamibi Series				
Dates	May '92–Nov '93	May '92–Aug '93	May '92–Apr '93	
Total tests—number	275*	325*	600	1200
Dipyridamole—number	183	168	293	644
Percentage	67%	52%	48%	54%

*Patients used for quantification of abdominal-to-myocardial ratios.

could be shown to relate significantly to measurements of A/M. For each factor, the direction of change in A/M on immediate images was identical with ^{201}Tl and sestamibi. Moreover, these influences on A/M could be still be ascertained on sestamibi images acquired 1 hr after stress injection. Exercise workload produced the most significant effect on abdominal activity. The use of dipyridamole as part of the testing procedure was also associated with higher abdominal background for each imaging situation. Gender was a highly significant determinant of background activity with both agents. Factors relating to the presence of disease, including a history of infarction and angiographic findings, showed a small but significant tendency to increase A/M on univariate analysis.

With multivariate regression analysis, factors specifically contributing to abdominal uptake of perfusion tracers on the planar images could be pinpointed (Table 5). Thus, exercise workload was the principal determinant of abdominal background on planar images with ^{201}Tl , on immediate planar images with sestamibi and on acquisitions with sestamibi performed after a 1-hr delay. The use of dipyridamole, independent of the attained workload, appeared to be a determinant of abdominal background only for immediate sestamibi images. Gender was also a significant deter-

minant for abdominal background in each of the planar imaging situations. Moreover, workload remained the major determinant of sestamibi image quality even after tomographic reconstruction.

DISCUSSION AND CONCLUSION

In a number of ways, the VEX test (the combination of intravenous dipyridamole and exercise) represents an important tool in the nuclear physician's stress testing armamentarium. The incremental diagnostic value of scintigraphy is most apparent, and is easiest to justify, in those cases where optimal exercise cannot be performed and a standard ECG exercise test has provided inconclusive results (29). Yet standard vasodilator testing (as with dipyridamole-handgrip) precludes the observation of physiologic responses to dynamic exercise (12) and may not provide adequate image quality (16). VEX can optimize the diagnostic yield from the clinical, electrocardiographic and scintigraphic components of the test (18). Although the benefit of adding exercise to dipyridamole had been quantitated for ^{201}Tl (16,22), the requirement to produce a beneficial effect on image quality had not been previously evaluated for sestamibi.

TABLE 3
Exercise Performed after Intravenous Dipyridamole

Exercise level	Patient series—number (%)					
	Angiographic correlation		Revascularization		Routine diagnostic	
	^{201}Tl	Sestamibi	^{201}Tl	Sestamibi	^{201}Tl	Sestamibi
Isometric	34 (9%)	15 (8%)	15 (6%)	20 (12%)	126 (16%)	50 (17%)
Ergometry						
200–300 kpm	89 (25%)	48 (26%)	43 (18%)	39 (23%)	166 (21%)	72 (25%)
400–500 kpm	142 (40%)	61 (33%)	114 (47%)	48 (29%)	283 (36%)	114 (39%)
≥600 kpm	94 (26%)	59 (32%)	73 (30%)	61 (36%)	210 (27%)	57 (19%)
Total	359	183	245	168	785	293

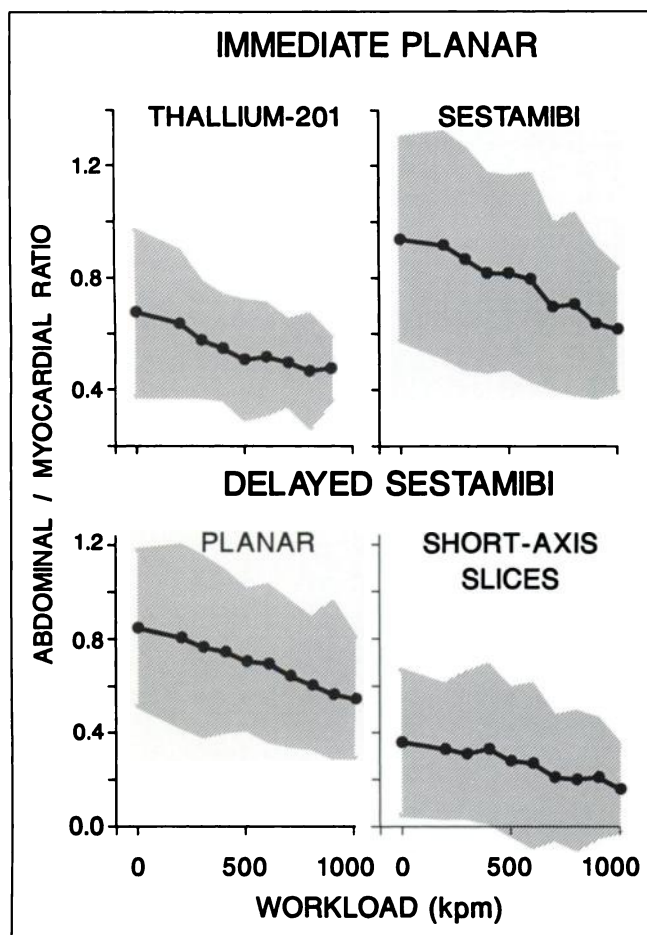


FIGURE 3. Means and variation (95% confidence intervals) for abdominal background ratios on dipyridamole-based tests according to the level of dynamic exercise attained after drug administration (Fig. 1). Patients unable to perform bicycle ergometry after dipyridamole performed repetitive isometric exercise (workload = 0).

In this study, we confirmed that relatively high abdominal background was present on planar images obtained immediately after dipyridamole-handgrip stress with either ²⁰¹Tl or sestamibi, but that this potential problem could be progressively reduced by use of bicycle exercise as part of the VEX procedure; a peak workload of 400 kpm (60 watts) appeared adequate to achieve some beneficial effect with either ²⁰¹Tl or sestamibi. With sestamibi, the benefit of supplemental exercise is maintained for at least 1 hr after injection and is relevant to the unprocessed data acquired for tomographic analysis. The effect of ergometry documented with planar imaging also translates to improved filtered and reconstructed tomographic images with sestamibi.

In the present large series, gender could be shown to be a determinant of abdominal background activity with both perfusion agents (Table 5). This knowledge may be important in comparisons of stress modalities carried out in a smaller number of patients with ²⁰¹Tl (16, 22). The results of such studies could be distorted by patient selection even though randomization of subjects had been performed. In

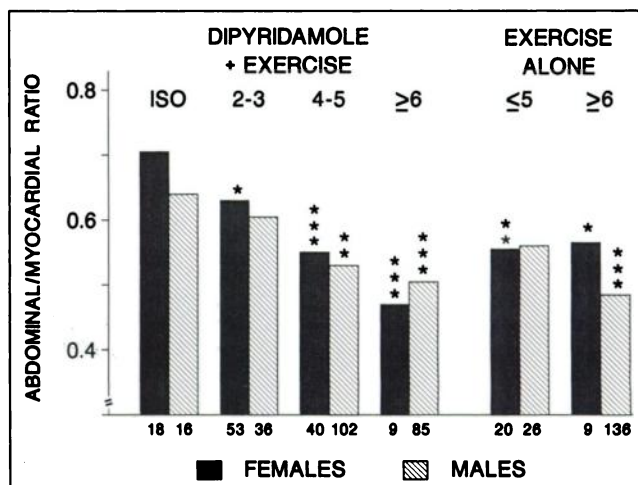


FIGURE 4. Abdominal background on immediate ²⁰¹Tl images as quantitated by subdiaphragmatic-to-myocardial ratios. The level of exercise following dipyridamole is indicated: ISO denotes isometric (handgrip) exercise; 2-3 denotes 200-300 kpm of ergometry; 4-5 denotes 400-500 kpm of ergometry; ≥6 denotes at least 600 kpm of ergometry according to the scheme shown in Figure 1. The bars on the right show similar data for comparable cases stressed with exercise alone. Numbers under each bar indicate the relevant number of patient studies. Probability values relate to differences from the dipyridamole-isometric group. * p < 0.05, ** p < 0.005, *** p < 0.0005.

the present study, a beneficial effect of supplemental dynamic exercise on dipyridamole images was demonstrated independently for both genders with ²⁰¹Tl. This was more difficult to demonstrate with sestamibi, possibly because of wider variation among individuals in abdominal background with sestamibi or to a lesser "efficiency" of supplemental exercise in the context of dipyridamole-sestamibi studies. Thus, the net benefit of supplemental exercise

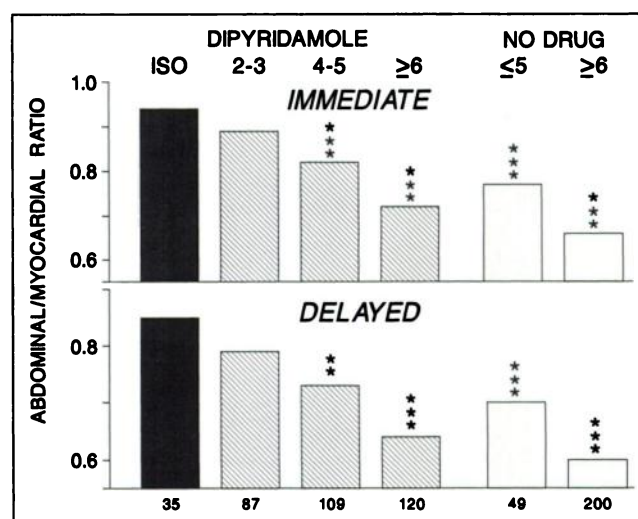


FIGURE 5. Abdominal background on immediate and delayed planar images with sestamibi in the LAO projection. Characterization of exercise workloads and statistical significance are as shown in Figure 4.

TABLE 4
Clinical, Angiographic and Stress-Procedure Factors Correlating with Abdominal-to-Myocardial Ratios on Planar Stress Images: Univariate Regression Analysis

Factor	Effect [‡]	Associated correlation coefficient*		
		Thallium immediate (n = 550)	Sestamibi immediate (n = 275)	Sestamibi delayed (n = 272)
Clinical				
Gender (male)	↓	0.30	0.32	0.29
Infarct	↑	0.10	0.12	0.17
Hypertension	↓	0.08 (ns)	0.02 (ns)	0.02 (ns)
Angiographic				
Coronary disease	↑	0.08 (ns)	0.12	0.12 (ns)
Ventricular dysfunction	↑	0.14	0.15	0.17
Stress mode				
Workload (kpm)	↓	0.51	0.52	0.51
Dipyridamole	↑	0.24	0.37	0.34
Peak heart rate	↓	0.37	0.27	0.25
Chest pain	↑	0.20	0.23	0.23

*Statistically significant relationship, $p < 0.05$, unless otherwise indicated.

[‡]Direction of change for each factor was identical for the three radiotracer/imaging protocols.

ns = not significant, $p \geq 0.05$; ↑ = increasing abdominal-to-myocardial ratio, i.e., higher background activity.

may be somewhat less with sestamibi than with ²⁰¹Tl, but this determination may require further study.

Certain limitations of the present study need to be addressed. Because the scheme for stress-test selection was implemented in a clinical setting, stress modalities were not randomly assigned; however, the selection of dipyridamole-based tests rather than exercise alone was usually predicated on factors unrelated to the probability of myocardial ischemia (e.g., knee arthritis). Measurements of A/M were performed in batch-mode, but were not coded and blinded, and thus could have been subject to observer bias. As there are wide variations in tracer uptake in abdominal regions adjacent to the myocardium, sampling error may have played a role, and even resulted in a non-normal distribution of results, particularly with sestamibi tomograms (Fig.

3). In comparing sestamibi to ²⁰¹Tl, however, the measurements suggest relatively higher abdominal background with sestamibi, even on 1-hr delayed images (Figs. 4 and 5) and highlight efforts (24) to reduce this problem.

Other recent studies suggest analogous benefits of the VEX procedure in a wider context. Pennell and Ell (30) found that the combination of exercise and intravenous adenosine increases myocardial uptake and decreases abdominal uptake of ²⁰¹Tl when compared to adenosine alone. Ignaszewski et al. (31) recently reported their experience confirming the safety and efficacy of routine testing with combined dipyridamole and treadmill exercise in conjunction with planar thallium imaging. Improved washout characteristics on ²⁰¹Tl images (21) as a result of adding dynamic exercise to dipyridamole may represent another

TABLE 5
Factors Affecting Abdominal-to-Myocardial Ratios: Multivariate Analyses for Each Radiotracer/Imaging Protocol

Factors* and statistical significance			
Thallium immediate planar	Sestamibi immediate planar	Sestamibi delayed planar	Sestamibi short-axis slices
Workload $p < 0.00001$	Workload $p = 0.00003$	Workload $p < 0.00001$	Workload $p = 0.003$
Gender $p < 0.00001$	Gender $p = 0.006$	Gender $p = 0.03$	Coronary disease $p = 0.02$
Peak heart rate $p = 0.0001$	Dipyridamole $p = 0.04$		Hypokinesia $p = 0.02$
Hypertension $p = 0.001$	Hypertension $p = 0.05$		
Infarct $p = 0.005$			

*In order of statistical significance.

advantage of the VEX procedure. The current study suggests that at least some of the benefit (13, 32) of the VEX procedure (32) will be applicable during the era of tomographic imaging and ^{99m}Tc-based perfusion agents.

ACKNOWLEDGMENTS

The technologists of the Department of Nuclear Medicine in Victoria Hospital made this work possible by meticulous performance of protocols. The Visual Services Department of Victoria Hospital provided invaluable assistance with artwork.

REFERENCES

1. Segall GM. Cardiac stress testing without the use of exercise [Editorial]. *Nucl Med Commun* 1990;11:663-666.
2. Albro PC, Gould KL, Westcott RJ, Hamilton GW, Ritchie JL, Williams DL. Noninvasive assessment of coronary stenoses by myocardial imaging during pharmacologic coronary vasodilation. III. Clinical trial. *Am J Cardiol* 1978;42:751-760.
3. Homma S, Gilliland Y, Guiney THE, Strauss HW, Boucher CA. Safety of intravenous dipyridamole for stress testing with thallium imaging. *Am J Cardiol* 1987;59:152-154.
4. Lam JYT, Chaitman BR, Glaenger M, et al. Safety and diagnostic accuracy of dipyridamole-thallium imaging in the elderly. *J Am Coll Cardiol* 1988;11:585-589.
5. Botvinick EH, Dae MW. Dipyridamole perfusion scintigraphy. *Semin Nucl Med* 1991;21:242-265.
6. Beer SG, Heo J, Iskandrian AS. Dipyridamole thallium imaging. *Am J Cardiol* 1991;67:18D-26D.
7. Josephson MA, Brown BG, Hecht HS, Hopkins J, Pierce CD, Petersen RB. Noninvasive detection and localization of coronary stenoses in patients: comparison of resting dipyridamole and exercise thallium-201 myocardial perfusion imaging. *Am Heart J* 1982;103:1008-1018.
8. Varma SK, Watson DD, Beller GA. Quantitative comparison of thallium-201 scintigraphy after exercise and dipyridamole in coronary artery disease. *Am J Cardiol* 1989;64:871-877.
9. Martin W, Tweddel AC, Main G, Hutton I. A comparison of maximal exercise and dipyridamole thallium-201 planar gated scintigraphy. *Eur J Nucl Med* 1992;19:258-264.
10. Brown BG, Josephson MA, Pierce CD, et al. Intravenous dipyridamole combined with isometric handgrip for near maximal acute increase in coronary flow in patient with coronary artery disease. *Am J Cardiol* 1981;48:1077-1085.
11. Zhu HY, Lie W, Botvinick E, et al. The clinical and pathophysiological implications of pain, ST abnormalities and scintigraphic changes induced during dipyridamole infusion: their relationships to the hemodynamic response. *Am Heart J* 1988;116:1071-1080.
12. Wackers J. Pharmacologic stress with dipyridamole: how lazy can one be? *J Nucl Med* 1990;30:1024-1027.
13. DePuey EG. Exercise supplementation of dipyridamole for myocardial perfusion imaging. *J Nucl Med* 1991;32:1564-1568.
14. Hurwitz GA, Powe JE, Driedger AA, Finnie KJC, Laurin NR, MacDonald AC. Dipyridamole combined with symptom-limited exercise for myocardial perfusion scintigraphy: image characteristics and clinical role. *Eur J Nucl Med* 1990;17:61-68.
15. Casale PN, Guiney THE, Strauss W, Boucher CA. Simultaneous low-level treadmill exercise and intravenous dipyridamole stress thallium imaging. *Am J Cardiol* 1988;62:799-802.
16. Stern S, Greenberg ID, Corne RA. Quantification of walking exercise required for improvement of dipyridamole thallium-201 image quality. *J Nucl Med* 1992;33:2061-2066.
17. Walker PR, James MA, Wilde RPH, Wood CH, Russell RJ. Dipyridamole combined with exercise for thallium-201 myocardial imaging. *Br Heart J* 1986;55:321-329.
18. Verzijlbergen JF, Vermeersch PHMJ, Laarman G-J, Ascoop CAPL. Inadequate exercise leads to suboptimal imaging. Thallium-201 myocardial perfusion imaging after dipyridamole combined with low-level exercise unmasks ischemia in symptomatic patients with non-diagnostic thallium-201 scans who exercise submaximally. *J Nucl Med* 1991;32:2071-2078.
19. Picano E, Lattanzi F, Massini M, Distante A, L'Abbate A. Usefulness of the dipyridamole-exercise echocardiography test for diagnosis of coronary artery disease. *Am J Cardiol* 1988;62:67-70.
20. Hurwitz GA, O'Donoghue JP, MacDonald AC, Laurin NR, Powe JE. Markers of left ventricular dysfunction induced by exercise, dipyridamole or combined stress modes on ECG-gated myocardial perfusion scans. *Nucl Med Commun* 1993;14:318-327.
21. Fridrich L. Myocardial Tl-201 wash-out after combined dipyridamole submaximal exercise stress: reference values from different patient groups. *Eur J Nucl Med* 1989;15:81-86.
22. Pennell DJ, Mavrogeni S, Anagnostopoulos C, Ell PJ, Underwood SR. Thallium myocardial perfusion tomography using intravenous dipyridamole combined with maximal dynamic exercise. *Nucl Med Commun* 1993;14:939-945.
23. Wackers FJT, Berman DS, Maddahi J et al. Technetium-99m hexakis 2-methoxyisobutylisonitrile: human biodistribution, dosimetry, safety and preliminary comparison to thallium-201 for myocardial perfusion imaging. *J Nucl Med* 1989;30:301-311.
24. Hurwitz GA, Clark EM, Slomka P, Siddiq SK. Investigation of measures to reduce interfering abdominal activity on rest myocardial images with technetium-99m sestamibi. *Clin Nucl Med* 1993;18:735-741.
25. Hurwitz GA, Fox SP, Driedger AA, Willems CA, Powe JE. Pulmonary uptake of sestamibi on early post-stress images: angiographic relationships, incidence, and kinetics. *Nucl Med Commun* 1993;14:15-22.
26. Hurwitz GA, O'Donoghue JP, Powe JE, Gravelle DR, MacDonald AC, Finnie KJC. Pulmonary thallium-201 uptake following dipyridamole-exercise combination compared with single modality stress-testing. *Am J Cardiol* 1992;69:320-326.
27. Hurwitz GA, Champagne CL, Powe JE. Kinetics of technetium-99m sestamibi following exercise, dipyridamole or combined stress: comparison with thallium-201 and implications for stress/injection protocols [Abstract]. *Clin Res* 1993;41:340A.
28. Rosner B. *Fundamentals of biostatistics*. 2nd edition. Boston: Duxbury Press; 1986.
29. Ladenheim ML, Kotler TS, Pollock BH, Berman DS, Diamond GA. Incremental prognostic power of clinical history, exercise electrocardiography and myocardial perfusion scintigraphy in suspected coronary artery disease. *Am J Cardiol* 1987;59:270-277.
30. Pennell DJ, Ell PJ. Whole-body imaging of thallium-201 after six different stress regimens. *J Nucl Med* 1994;35:425-428.
31. Ignaszewski AP, McCormick LX, Heslip PG, McEwan AJ, Humen DP. Safety and clinical utility of combined intravenous dipyridamole-symptom limited exercise stress test with thallium-201 imaging in patients with known or suspected coronary artery disease. *J Nucl Med* 1993;34:2053-2061.
32. Brown KA. Exercise-dipyridamole myocardial perfusion imaging: the circle is now complete [Editorial]. *J Nucl Med* 1993;34:2061-2063.