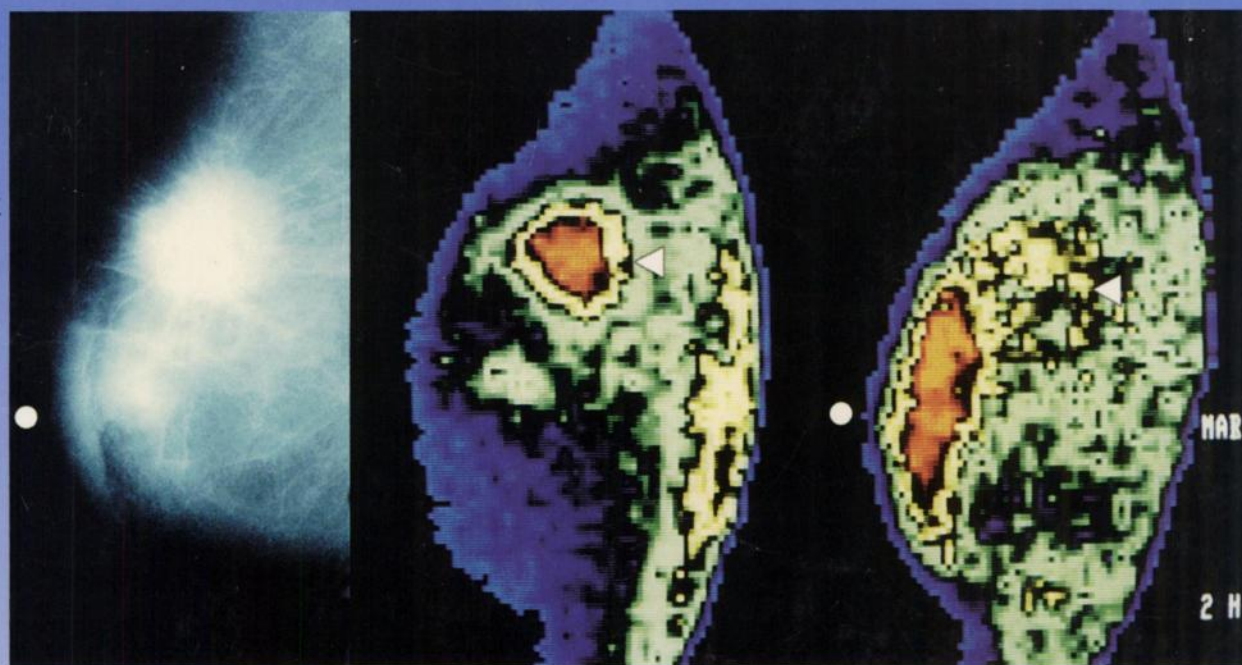

The Journal of Nuclear Medicine

JNM

Volume 36, Number 5 • May 1995

Nuclear Oncology: A Growth Industry



Inflammatory cancer of the left breast in a 65-yr-old woman. Left to right: mammogram and early and late ^{99m}Tc-MDP images. See pages 718-724.



The Official Publication of
the Society of Nuclear Medicine, Inc.
