

---

The Journal of Nuclear Medicine

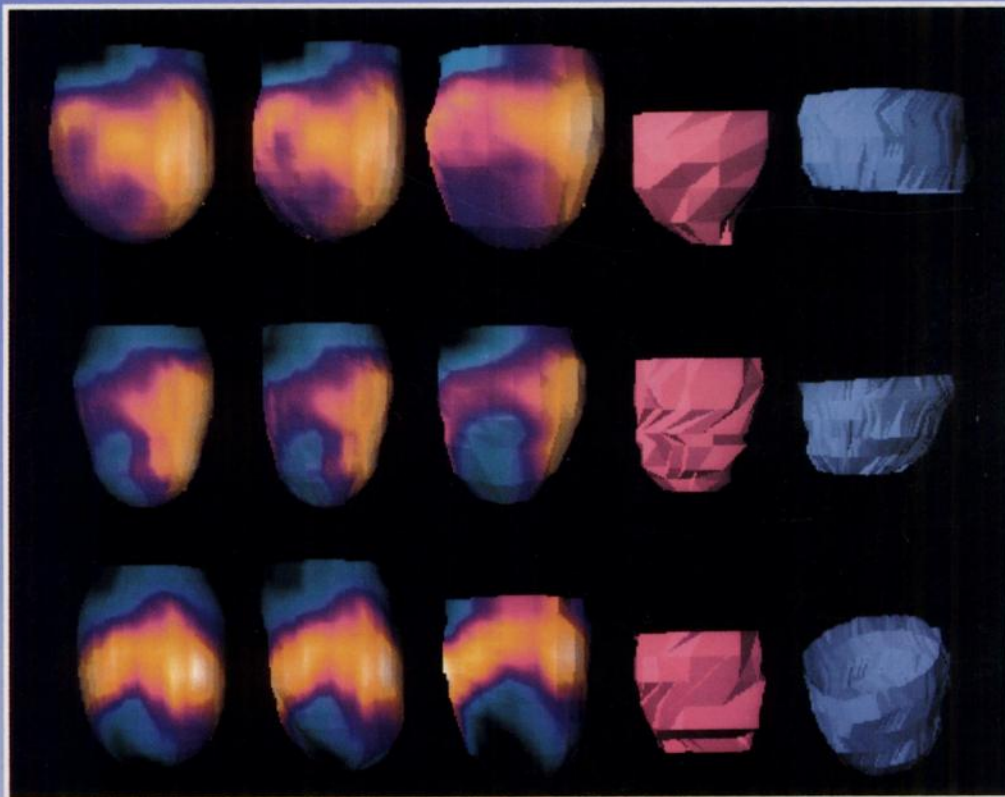
---

# JNM

---

Volume 36, Number 4 • April 1995

---



Three-dimensional displays of left ventricular epicardial surface from SPECT perfusion tomograms from three patients with known or suspected ischemic heart disease. Shown are two models and three standards for patients whose model errors were worst on average (top) and least (middle). The bottom panel represents the one patient for whom two of the angles required SPECT registration. MR left ventricular epicardial surfaces were  $>20^\circ$ . See pages 697-702.



---

The Official Publication of  
the Society of Nuclear Medicine, Inc.

---