

---

The Journal of Nuclear Medicine

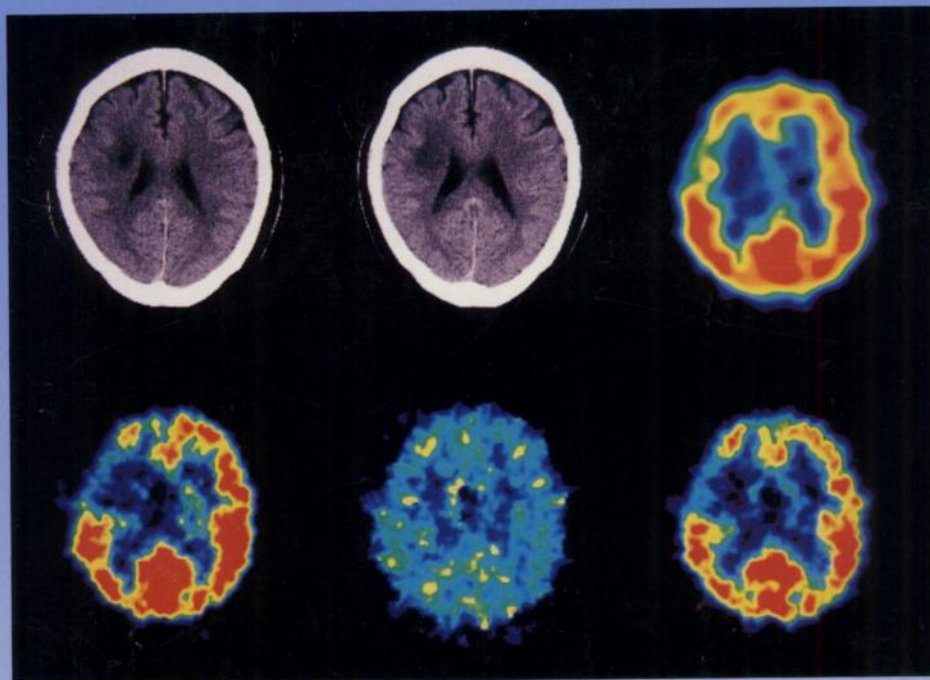
---

# JNM

---

Volume 36, Number 12 • December 1995

---



Positive  $^{18}\text{F}$ FDG and negative  $^{64}\text{Cu}$ -MAB 1A3 images of a woman with a history of rectal carcinoma who subsequently developed lymphadenopathy. See pages 2154-2161.



---

The Official Publication of  
the Society of Nuclear Medicine, Inc.

---