Prediction of Improvement in Left Ventricular Function with Iodine-123-IPPA after Coronary Revascularization

Christopher L. Hansen, Jaekyeong Heo, Craig Oliner, William Van Decker and Abdulmassih S. Iskandrian

Temple University Hospital, Philadelphia, Pennsylvania; Philadelphia Heart Institute, Philadelphia, Pennsylvania, Albert Einstein Medical Center, Philadelphia, Pennsylvania; and Medical College Hospitals, Philadelphia, Pennsylvania

Iodine-123-phenylpentadecanoic acid (IPPA) is a synthetic fatty acid suitable for myocardial imaging. This study is the result of a Phase I/II trial to evaluate IPPA's ability to predict functional recovery in patients undergoing coronary revascularization. **Methods:** Twenty-three patients with documented coronary disease underwent sequential SPECT imaging with IPPA before and radionuclide ventriculography both before and 8 wk after revascularization. Software was developed to evaluate myocardial IPPA metabolism and to determine the fraction of the left ventricle with intermediate metabolism. **Results:** There was a significant correlation between initial IPPA uptake and final LVEF. The fractional area of the left ventricle demonstrating IPPA metabolism in the intermediate metabolic range was significantly higher in patients who demonstrated a 5% or greater increase in EF after revascularization (0.90 ± 0.08 versus 0.78 ± 0.17, p = 0.04). When only the patients who received complete revascularization were evaluated, there was a more significant difference (improved 0.92 ± 0.05 versus 0.74 ± 0.17, p = 0.011). Taking a lower limit of 1 s.d. from the mean, (87%) the six patients who had ≥5% increase in LVEF after revascularization had more than 87% of the left ventricle in the intermediate metabolic range, whereas seven of ten patients whose change in LVEF was <5% had less than 87% in the intermediate metabolic range (p = 0.011). **Conclusion:** In this initial experience, the amount of myocardium in the intermediate metabolic range is associated with improvement in LVEF after revascularization, especially in patients receiving complete revascularization.

J Nucl Med 1995; 36:1987–1993

The clinical demands placed upon practitioners of nuclear cardiology have evolved with the growth of technologies for myocardial revascularization. Where once the main clinical questions regarded the diagnosis and assessment of prognosis of patients with suspected coronary artery disease (CAD), there are now greater demands to evaluate myocardial viability and identify those patients most likely to benefit from revascularization.

The clinical experience with the technologies available for assessing myocardial viability is growing rapidly. Many practitioners favor the positron-emitter [^{18}F]fluorodeoxyglucose (FDG) as the gold standard for assessing viability (*1*). Cost and ease of use, however, favor single-photon technology. Consequently, there has been renewed interest in evaluating agents such as ^{201}Tl (*2–4*). As yet, no definite consensus has emerged as to which radiopharmaceutical or technique is best.

Iodine-123-phenylpentadecanoic acid (IPPA) is a synthetic long-chain fatty acid that has been demonstrated to have kinetics similar to palmitate (*5,6*). It has been shown to provide excellent myocardial images and to be comparable to thallium perfusion imaging for the diagnosis of CAD (*7*). Previous studies have demonstrated altered metabolism of IPPA in patients with exercise-induced ischemia and myocardial infarction (*7,8*).

The current study is the result of a Phase I/II dose ranging and preliminary efficacy study into the feasibility of using IPPA as a marker of myocardial viability and to test its ability to predict functional recovery after revascularization. Preliminary data on the first few patients to complete the study have been reported previously (*9*). Conventional analysis and comparison to ^{201}Tl in patients from one center have been reported (*10*). This paper includes all patients studied under this protocol and extends the analytic techniques.

METHODS

Four centers in Philadelphia were invited to participate. The protocol was approved by the Institutional Review Board at each center and all patients gave written informed consent. Entry criteria for the study included patients between the ages of 25 and 75 with angiographically documented CAD who were being referred for coronary revascularization and had at least one dysfunctional myocardial segment or left ventricular ejection fraction (LVEF) less than 50%. Candidates for both coronary artery bypass grafting (CABG) and percutaneous transluminal coronary angioplasty (PTCA) were accepted.

Patients with potentially confounding cardiac events or procedures, such as myocardial infarction (MI), PTCA or CABG within

Received Mar. 15, 1995; revision accepted Jul. 14, 1995.

For correspondence or reprints contact: Christopher L. Hansen, MD, Section of Cardiology, Temple University Hospital, 3401 N. Broad St., Philadelphia, PA 19140.

the previous 8 wk, were excluded. Since it has been demonstrated that fatty acid metabolism is significantly altered in nonischemic cardiomyopathy (*11*), these patients were also excluded. Patients with untreated metabolic disorders such as diabetes mellitus or thyroid disease were not considered as candidates. The preparation of IPPA involves the use of human serum albumin, and Lugol's solution is given prior to injection to block thyroid uptake of free iodine; patients with an allergy to either were not included. Subjects with significant hepatic or renal dysfunction were excluded, as were pregnant or lactating females.

The endpoint in the study was recovery of left ventricular function. Therefore, the patients had resting radionuclide ventriculography before and after revascularization. Patients who were scheduled to undergo aneurysmectomy were not considered as candidates due to the confounding effects this procedure would have on the interpretation of changes in LVEF.

Imaging Protocol

The patients were studied while fasting. Eight to 10 drops of Lugol's solution were given orally. Next, the patient was randomized to receive either 2, 4 or 6 mCi IPPA (74, 148 or 232 MBq). The patients were injected while at rest. Five sequential SPECT image sets were obtained with a single-head camera starting 4 min after injection and repeated at 12, 20, 28 and 36 min. The image sets consisted of 32 images obtained for 15 sec each over 180° orbits starting from the 45° right anterior oblique to the 135° left posterior oblique.

Resting radionuclide ventriculography was performed using 20 mCi ^{99m}Tc-labeled red blood cells. Standard anterior, left anterior oblique (best septal) and left lateral views were obtained. Radionuclide ventriculography was repeated using the same technique 8 wk after revascularization.

The images were downloaded to a Macintosh platform for processing. Image processing and analysis software was written in C. This software is fully scriptable and capable of displaying floating point images. The images were prefiltered with a Butterworth filter with a cutoff of 0.30 of the Nyquist and an alpha of 2.5 using an adaptation of a Chebyshev algorithm described by Miller et al. (*12*). The filtered images were convolved with a ramp filter and backprojected to produce transaxial slices (*13,14*). Short-axis sections were generated, after which a volume-weighted bulls-eye image was constructed from each short-axis image set. Volume weighting was achieved by adjusting the width of each ring on the bulls-eye so that the ring had the same fractional area of the entire bulls-eye plot that the corresponding short-axis slice had to the entire left ventricular mass (*15*).

Parametric Bulls-eye Images

We have previously demonstrated that regional metabolism of IPPA can be modeled as monoexponential decay (*9*). For the current study, this analysis was advanced to create a parametric bulls-eye image which would reflect metabolism of IPPA throughout the myocardium. This was done by taking the natural logarithm of five bulls-eye images and then fitting corresponding pixels to a linear least squares regression line (Fig. 1). The slope of this line (λ) represents the metabolic decay constant of IPPA in the pixel over time. The time of acquisition for each image was incorporated into the model. The gamma values were used to create a parametric bulls-eye image which reflected IPPA metabolism throughout the myocardium.

IPPA metabolism is reduced in regions of ischemia but markedly reduced in regions of infarction (*7,8*). We hypothesized that

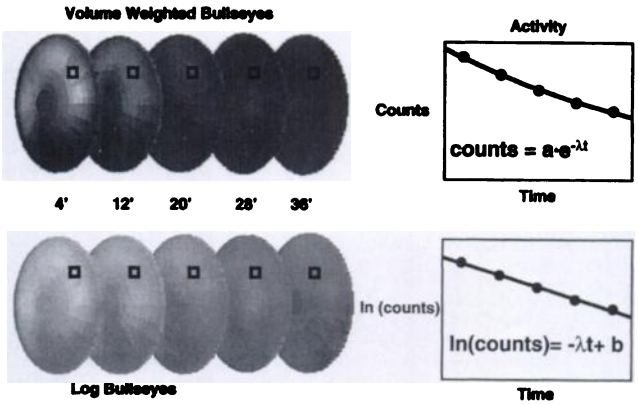

FIGURE 1. Myocardial IPPA metabolism was modeled as monoexponential decay by taking the natural logarithm of the bulls-eyes and then fitting corresponding pixels to a regression line. The slope of this line, λ, represents the rate of IPPA metabolism for that pixel. A parametric bulls-eye image showing the slope of this line for each pixel was generated.

myocardial regions most likely to improve with revascularization would demonstrate IPPA metabolism in an intermediate range, slower than normals but faster than infarcted regions. The analysis software was scripted to enable repetitive calculations of plot area sequentially thresholded to different upper and lower limits. The fractional areas of the parametric images corresponding to gammas between lower limits of 0–0.005 and upper limits 0.006–0.015 ln(cts)/min were calculated. The contributory effects of initial IPPA uptake were investigated by calculating the area of the 4-min image that was between lower limits of 20%–50% maximal uptake and upper limits of 70%–100% that was also in the intermediate metabolic range. The implications of initial IPPA uptake were also studied by analyzing the fractional area of normalized myocardial uptake thresholded to maximal counts.

Statistical Analysis

The data are expressed as mean ± 1 s.d.. Continuous variables were compared with a Student's t-test; a paired t-test was used when appropriate. Discrete variables were compared using Fisher's exact test. Linear regression was performed using commercially available software (Minitab, State College, PA). A two-tailed p value less than 0.05 was considered significant.

RESULTS

A total of 35 patients underwent IPPA imaging. There were no adverse reactions reported. Image quality was consistently good with the 4- and 6-mCi doses but were frequently unacceptable with the 2-mCi dose.

Twenty-seven patients were able to complete the study. Three patients who received 2 mCi IPPA had to be excluded due to unacceptable image quality. One patient who underwent unscheduled aneurysmectomy during CABG was also rejected. The results for the remaining 23 patients (20 men, 3 women; mean age 64 ± 9 yr) are reported here. Ten patients were being treated for diabetes mellitus. Thirteen patients had a history of prior MI, 10 had pathologic Q-waves on their EKG; and two patients had previously undergone CABG. Five patients had one-vessel disease, ten

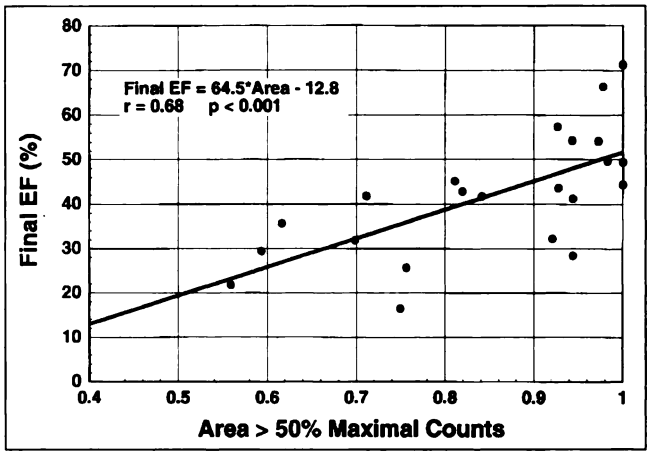

FIGURE 2. Ejection fraction (EF) after revascularization plotted as a function of the amount of myocardium greater than 50% of the maximal counts on initial uptake. Initial IPPA uptake is predictive of the final EF.

had two-vessel and eight had three-vessel disease. Ten patients were referred for PTCA and 13 underwent CABG. Sixteen patients had complete revascularization with bypass grafts to, or angioplasty of, all diseased vessels and seven had incomplete revascularization.

The slope of the regression line (λ) varied from -0.01 to 0.02. The EF increased from 39% ± 14% before revascularization to 42% ± 14%. Although this change is within the error of measurement of EF, the difference was statistically significant by paired Student's t-test ($p = 0.047$).

The area of activity in the 4-min image greater than 50% maximal counts was best able to predict final EF (Fig. 2). Initial IPPA uptake is a good predictor ($r = 0.68$) of final EF; we found a highly significant ($p < 0.001$) correlation. Initial uptake, however, was not able to predict a change in ejection fraction with revascularization.

Analysis of intermediate metabolism revealed that the range of 0.001 to 0.012 ln(cts)/min correlated best with the change in EF after revascularization (Fig. 3A). The patients who improved after revascularization had a significantly higher amount of myocardium in the intermediate metabolic range (0.90 ± 0.08 versus 0.78 ± 0.17, $p = 0.04$). It can be seen from Figure 3A that there is a significant amount of scatter in the data, suggesting that other factors influence improvement in ventricular function. When only those patients who received complete revascularization were examined, the predictive power improved (0.92 ± 0.05 versus 0.74 ± 0.17, $p = 0.011$; Fig. 3B). We used a cutoff of 1 s.d. from the mean of the patients with improved (87%) and found that all six patients with ≥5% increase in EF after revascularization had >87% of the left ventricle in the intermediate metabolic range, whereas 7/10 patients with an increase <5% had <87% of the left ventricle in that area (sensitivity 100%, specificity 70%, Fisher's exact $p = 0.011$). Combining intermediate IPPA metabolism with initial uptake did not improve the predictive ability.

Figure 4 shows representative short-axis sections from the 4- and 36-min datasets of a 73-yr-old man with no prior history or EKG evidence of infarction who presented with dyspnea on exertion. The patient had a 95% stenosis of the left anterior descending coronary artery as well as disease in the ramus intermedius and circumflex arteries. Delayed clearance was demonstrated in the anteroseptal walls of the apical and mid short-axis slices. A large portion of the left ventricle (88%) fell within the intermediate metabolic range. His EF improved from 19% to 28% after CABG.

Figure 5 shows the results of a 66-yr-old man who had an inferior wall MI 3 yr previously and was diagnosed as having three-vessel CAD. The left ventricle is enlarged. There is a large inferior wall defect that did not improve significantly over time. A smaller portion (46%) of the left ventricle fell within the intermediate metabolic range. After CABG, there was no improvement in EF (16% pre- and postrevascularization).

DISCUSSION

Free fatty acids (FFAs) are the predominant source of myocardial energy under most conditions (*16–18*). Free fatty acids circulate in the plasma bound to albumin and cross the cell membrane by passive diffusion. Once in the

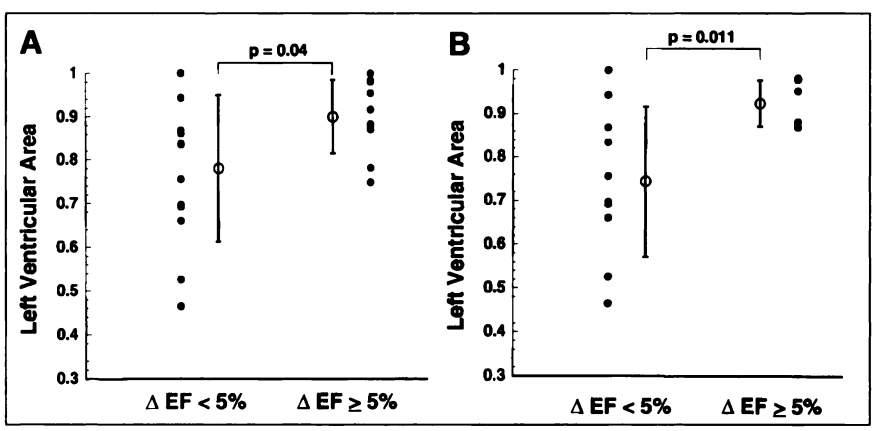

FIGURE 3. (A) Fractional area of the left ventricle in the intermediate range is compared between those patients who had 5% or greater increase in EF after revascularization versus those who did not. All 23 patients are represented. The means are significantly different, despite a large amount of scatter in the data. (B) The 16 patients who received complete revascularization are shown. The difference in the means is greater with a lower p value. There is less scatter in the group that improved.

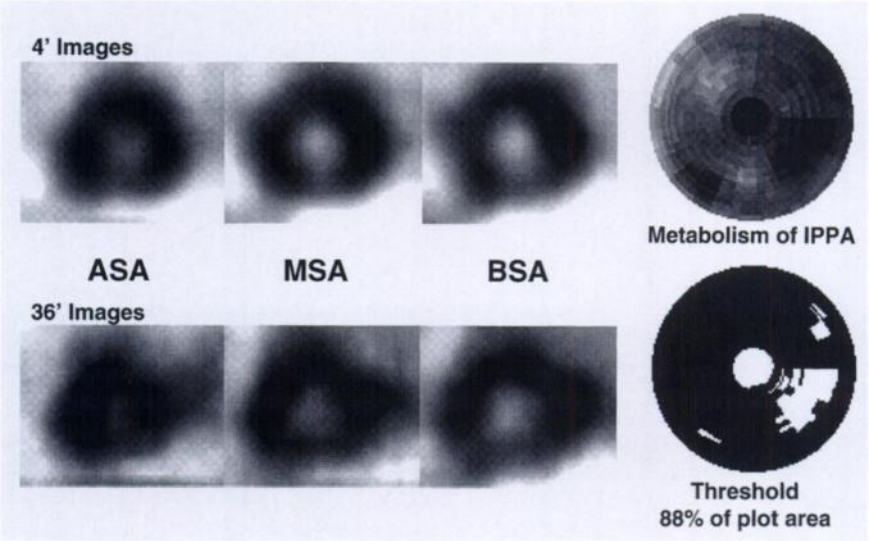

FIGURE 4. A 73-yr-old man with two-vessel disease. Delayed IPPA metabolism is shown in the anteroseptal wall. The regions within the intermediate metabolic range are below the metabolic image. A large portion of the ventricle (88%) is in the intermediate metabolic range. The patient's EF increased from 19% to 28% after CABG. ASA = apical short-axis; MSA = mid short-axis; BSA = basal short-axis.

cell, they can either backdiffuse or become activated by acyl-CoA synthetase. Once the latter step occurs, FFAs become polar and are trapped inside the cell where one of two fates awaits them. The first is transportation to the mitochondria through a complex carnitine-dependent process in which they undergo beta-oxidation. The second is incorporation into intracellular lipid pools.

Previous investigations have shown that myocardial metabolism of palmitate is biexponential with an early rapid phase due to beta-oxidation and slower phase from turnover of the triglyceride pools (*19*). The single-head SPECT cameras used in this study did not have the temporal resolution to capture the early rapid phase of beta-oxidation and thus could only demonstrate the monoexponential decay from turnover in the triglyceride pools. Vyska et al. reported that IPPA metabolism was different from other labeled fatty acids, with an early plateau phase of constant activity for the first 25 min after injection (*20*). Our results confirmed our earlier findings; we saw no plateau and there was a good fit to monoexponential decay (*9*). This discrepancy is most likely due to Vyska's use of planar imaging and errors introduced by background correction.

The effects of ischemia on FFA metabolism have been extensively investigated (*21,22*). Initial FFA uptake is largely a function of myocardial perfusion, with some researchers reporting that the extraction fraction increases with ischemia and others reporting that it does not (*23,24*). There is a decrease in beta-oxidation and an increase in the percentage of FFAs in the triglyceride pool and delayed FFA metabolism. Simultaneously, a higher proportion of energy is derived from glycolysis. These changes in metabolism can be detected noninvasively by demonstrating either reduced fatty acid or increased glucose metabolism. Previous studies using IPPA

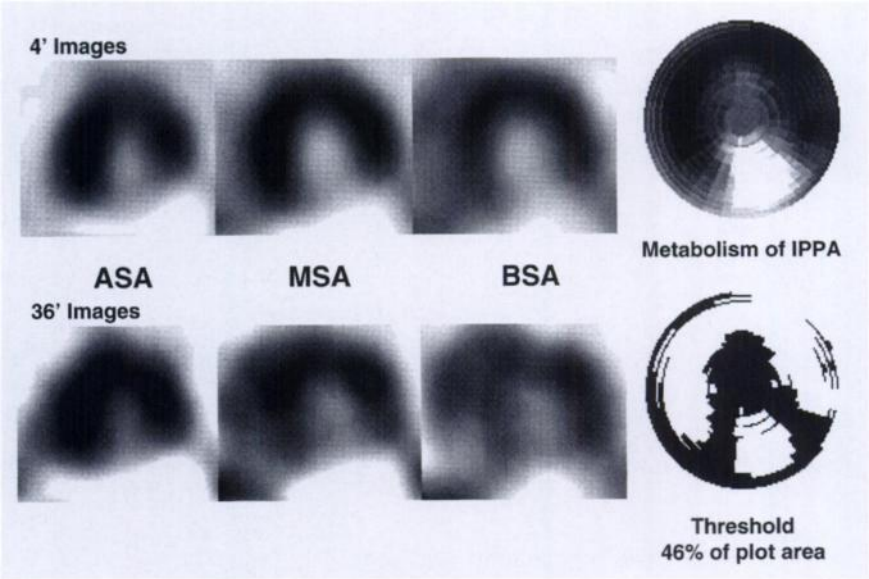

FIGURE 5. A 66-yr-old man with history of an inferior wall MI and three-vessel coronary artery disease. There is a large inferior wall defect that did not improve significantly over time. The metabolic image shows a smaller percentage of the LV within the intermediate range and thus predicts no improvement after revascularization. ASA = apical short-axis; MSA = mid short-axis; BSA = basal short-axis.

in patients with CAD have demonstrated that exercise-induced ischemia resulted in reduced uptake and IPPA clearance when compared to normal controls (*7*).

FFA Metabolism in Viable Myocardium

Prolonged myocardial dysfunction after severe ischemia can be either permanent (necrosis) or reversible due to either stunning or hibernation (viable myocardium). The latter are differentiated by the duration of the ischemic insult. Stunning refers to prolonged derangement of myocardial systolic and diastolic function after transient ischemia (*25*). Hibernating myocardium refers to a compensatory downregulation of contractile function as an adaptive response to chronic ischemia (*26*). Although it is easy to differentiate these processes conceptually, it can be difficult to do so in the clinical setting. Frequently a patient who has severe CAD will present with a mixture of necrotic and hibernating myocardium and then suffer another ischemic insult, causing either further necrosis or stunning. All of the patients in this study had significant CAD. Most subjects had stable symptoms; patients with recent infarctions were excluded. Therefore, the patients who improved probably had hibernating myocardium, although the few patients who demonstrated evidence of recent ischemia might also have had some stunning.

There have been numerous studies investigating the metabolic effects of myocardial stunning. Chatelain et al. investigated alterations in the metabolism of (1-^{14}C)-palmitate after myocardial stunning produced by 40 min of ischemia in an isolated rat heart model (*27*). They found that after ischemic attack, myocardial uptake of palmitate was not significantly different from control subjects but that oxidation was depressed and recovered by 30 to 60 min. Myocardial contractility was also reduced and its improvement paralleled the recovery of palmitate oxidation. In two separate studies with ischemia of different durations, Schwaiger et al. also showed delayed recovery of palmitate metabolism after ischemic stunning in a canine model (*28,29*). The length of time it took for recovery of normal metabolism increased with the duration of the insult and paralleled the recovery of mechanical function. They demonstrated a simultaneous increase in glucose metabolism with [^{18}F]-FDG.

It is easier to create an animal model of myocardial stunning than of hibernation. Although one group has recently proposed such a model (*30*), less is known about the metabolic effects of hibernation. During hibernation, blood flow remains depressed and, hence, the ischemic insult is sustained. Clinical studies of patients who appear to have had hibernating myocardium suggest that the metabolic effects may be similar to stunning. Myocardial regions with relatively decreased perfusion and increased metabolism of glucose—so called flow-metabolism mismatch—have correlated with improvements in wall motion following revascularization in patients with stable CAD (*1*).

From previous studies and current understanding of FFA metabolism, we expected to see decreased uptake and delayed FFA metabolism in hibernating myocardium; the analysis of the current study was designed to exploit this possibility. Initial FFA uptake will reflect coronary perfusion and thus be reduced in areas of hibernation, but it will also be reduced in areas of nontransmural infarction supplied by an open artery. If the region in question is also ischemic, then it would be expected that a higher fraction of FFAs would enter the triglyceride pool, thereby causing delayed clearance. Delayed clearance should therefore be able to differentiate hibernating myocardium from a nonischemic region that had undergone nontransmural infarction. This property may make metabolic agents such as IPPA superior to perfusion agents in predicting functional recovery after revascularization.

We chose to use changes in ejection fraction instead of wall motion in this analysis because ejection fraction is more objective and less likely to be confounded by the emergence of paradoxical septal motion, as is often seen after CABG. Other research has shown that evidence of myocardial viability resulted in improved EF after revascularization which translates into a better prognosis (*31*).

In our analysis, we focused on the amount of myocardium in the intermediate metabolic range. We believe that areas of markedly reduced metabolism are predominantly necrotic and areas with metabolism close to normal are not sufficiently ischemic to improve with revascularization. The boundaries as to what constitutes intermediate metabolism cannot be derived from first principles, they must be determined empirically from the data. Our ability to predict the change in LVEF after revascularization decreased when either the upper or lower limits of the intermediate metabolic range were altered. It is likely that the optimal range for intermediate metabolism will change depending upon imaging parameters and as greater experience is obtained.

In the data presented here, relatively large amounts of myocardium in the intermediate range predicted small increases in EF; we found that a threshold of 87% differentiated patients who did and did not improve after complete revascularization. We do not believe that all myocardium in the intermediate range was necessarily hibernating. Because of the shorter imaging times in this study, we had to use relatively heavy filtering to obtain interpretable images 36 min postinjection. This degree of filtering will cause substantial blurring of the abnormal regions in the normal adjacent regions and result in larger volumes of myocardium in the intermediate range. For clinical use, it should not be necessary to obtain multiple sequential images. Obtaining an immediate and one later image about 30 min postinjection would enable longer imaging times, improve count statistics and allow identification of abnormal IPPA metabolism.

In the clinical setting, most patients will present with a combination of necrosis and stunning or hibernation. Previous work by Schwaiger et al. has demonstrated that myo-

cardial uptake of ^{11}C-palmitate had a better correlation with the extent of necrosis than [^{18}F]FDG (*28*). Also, experience with [^{18}F]FDG suggests that it needs to be combined with a perfusion agent to predict functional recovery (*1*). Decreased initial uptake of IPPA could be used to identify areas of resting hypoperfusion but did not increase the predictive ability in our study. Any comparisons between IPPA and [^{18}F]FDG would require an investigation that compared both techniques in the same patient group.

Limitations

In this type of study, one can only measure the potential for improvement after revascularization, and, clearly, not all patients will realize this potential. There are multiple confounding factors that could affect a given patient's response: incomplete revascularization, periprocedure infarction, graft stenosis, restenosis after angioplasty, changes in medication and mitral regurgitation will all affect the change in EF. Differences in substrate availability could affect IPPA metabolism. These factors most likely explain the variation in response that we observed, especially in the group that did not improve. We were able to control for some of the variation by examining the subgroup of patients who received complete revascularization; there was a corresponding improvement in the results.

It should be emphasized that all imaging performed in this investigation was done at rest. It is possible that increasing myocardial oxygen demand, either with exercise or pharmacologic stress, would further assist in differentiating ischemic viable myocardium from normal and irreversibly damaged myocardium.

All patients studied had documented CAD. The creation of a normal database may help to further define what range of metabolism should be considered normal and provide further insight into the abnormalities of fatty acid metabolism in hibernating myocardium.

CONCLUSION

Abnormalities detected with myocardial metabolic IPPA imaging are associated with improved left ventricular function after coronary revascularization. This association is strongest in patients receiving complete revascularization. This study encompasses only a small group of patients. As such, these findings will need to be confirmed in a larger study.

REFERENCES

1. Tillisch J, Brunken R, Marshall R, et al. Reversibility of cardiac wall-motion abnormalities predicted by positron tomography. *N Engl J Med* 1986;314:884–888.
2. Dilsizian V, Rocco TP, Freedman NMT, Leo MB, Bonow RO. Enhanced detection of ischemic but viable myocarium by the reinjection of thallium after stress-redistribution imaging. *N Engl J Med* 1990;313:141–146.
3. Bonow RO, Dilsizian V. Thallium-201 for assessment of myocardial viability. *Semin Nucl Med* 1991;21:230–241.
4. Ragosta M, Beller GA, Watson DD, Kaul S, Gimple LW. Quantitative planar rest-redistribution ^{201}Tl imaging in detection of myocardial viability and prediction of improvement in left ventricular function after coronary bypass surgery in patients with severely depressed left ventricular function. *Circulation* 1993;87:1630–1641.
5. Chien KR, Han A, White J, Kulkarni P. In vivo esterification of a synthetic ^{125}I-labeled fatty acid into cardiac glycerolipids. *Am J Phys* 1983;245:H693–H697.
6. Reske SN, Knapp FF, Winkler C. Experimental basis of metabolic imaging of the myocardium with radioiodinated aromatic free fatty acids. *Am J Phys Imaging* 1986;1:214–229.
7. Hansen CL, Corbett JR, Pippin JJ, et al. Iodine-123 phenylpentadecanoic acid and single-photon emission computed tomography in identifying left ventricular regional metabolic abnormalities in patients with coronary heart disease: comparison with thallium-201 myocardial tomography. *J Am Coll Cardiol* 1988;12:78–87.
8. Hansen CL, Kulkarni PV, Ugolini V, Corbett JR. The noninvasive detection of alterations in left ventricular fatty acid metabolism in patients with acute myocardial infarction using 15-(p-^{123}I-phenyl)-pentadecanoic acid and tomographic imaging. *Am Heart J* 1995;129:476–481.
9. Hansen CL. Preliminary report of an ongoing phase I/II dose range, safety and efficacy study of iodine-123-phenylpentadecanoic acid for the identification of viable myocardium. *J Nucl Med* 1994;35:38S–42S.
10. Iskandrian AS, Powers J, Cave V, Wasserleben V, Cassell D, Heo J. Assessment of myocardial viability by dynamic tomographic ^{123}I-iodophenylpentadecanoic acid imaging: comparison to rest-redistribution thallium-201 imaging. *J Nucl Cardiol* 1995; 2:101–109.
11. Ugolini V, Hansen CL, Kulkarni PV, Jansen DE, Akers MS, Corbett JR. Abnormal myocardial fatty acid metabolism in dilated cardiomyopathy detected by iodine-123 phenylpentadecanoic acid and tomographic imaging. *Am J Cardiol* 1988;62:923–928.
12. Miller TR, Sampathkumaran KS, King MA. Rapid digital filtering. *J Nucl Med* 1983;24:625–628.
13. Shepp LA. The fourier reconstruction of a head section. *IEEE Trans Nucl Sci* 1974;NS-21:21–43.
14. Kak AC, Slaney M. *Principles of computerized tomographic imaging*. New York:IEEE Press; 1987.
15. Garcia EV, Cooke CD, Van Train KF, et al. Technical aspects of myocardial SPECT imaging with technetium-99m sestamibi. *Am J Cardiol* 1990;66:22E–31E.
16. Opie LH. Metabolism of the heart in health and disease: I. *Am Heart J* 1968;76:685–698.
17. Opie LH. Metabolism of the heart in health and disease: II. *Am Heart J* 1969;77:100–122.
18. Neely JR, Rovetto MJ, Oram JF. Myocardial utilization of carbohydrate and lipids. *Prog Cardiovasc Dis* 1972;25:289–329.
19. Schön HR, Schelbert HR, Robinson G, et al. Carbon-11-labeled palmitic acid for the noninvasive evaluation of regional myocardial fatty acid metabolism with positron-computed tomography. I. Kinetics of ^{11}C-palmitic acid in normal myocardium. *Am Heart J* 1982;103:532–547.
20. Vyska K, Machulla HJ, Stremmel W, et al. Regional myocardial free fatty acid extraction in normal and ischemic myocardium. *Circulation* 1988;78:1218–1233.
21. Opie LH. Effects of regional ischemia on metabolism of glucose and fatty acids. *Circ Res* 1976;38(suppl 1):I52–I68.
22. Liedtke AJ. Alterations of carbohydrate and lipid metabolism in the acutely ischemic heart. *Prog Cardiovasc Dis* 1981;23:321–336.
23. Scheuer J, Brachfeld N. Myocardial uptake and fractional distribution of palmitate-1-^{14}C by the ischemic dog heart. *Metabolism* 1966;15:945–954.
24. Schön HR, Schelbert HR, Najafi A, et al. Carbon-11 labeled palmitic acid for the noninvasive evaluation of regional myocardial fatty acid metabolism with positron-computed tomography. II. Kinetics of ^{11}C plamitic acid in acutely ischemic myocardium. *Am Heart J* 1982;103:548–561.
25. Braunwald E, Kloner RA. The stunned myocardium: prolonged, postischemic ventricular dysfunction. *Circulation* 1982;66:1146–1149.
26. Rahimtoola SH. The hibernating myocardium. *Am Heart J* 1989;117:211–221.
27. Chatelain P, Papageorgiou I, Luthy P, Melchior JP, Rutishauser W, Lerch R. Free fatty acid metabolism in "stunned" myocardium. *Basic Res Cardiol* 1987;82(suppl 1):169–176.
28. Schwaiger M, Schelbert HR, Ellison D, et al. Sustained regional abnormalities in cardiac metabolism after transient ischemia in the chronic dog model. *J Am Coll Cardiol* 1985;6:336–347.
29. Schwaiger M, Schelbert HR, Keen R, et al. Retention and clearance of C-11

palmitic acid in ischemic and reperfused canine myocardium. *J Am Coll Cardiol* 1985;6:311–320.
30. Bolukoglu H, Liedtke AJ, Nellis SH, Eggleston AM, Subramanian R, Renstrom B. An animal model of chronic coronary stenosis resulting in hibernating myocardium. *Am J Phys* 1992;263:H20–H29.
31. Nesto RW, Cohn LH, Collins JJ Jr, Wynne J, Holman L, Cohn PF. Inotropic contractile reserve: a useful predictor of increased 5 year survival and improved postoperative left ventricular function in patients with coronary artery disease and reduced ejection fraction. *Am J Cardiol* 1982;50: 39–44.