

# Utility of Iodine-123-BMIPP in the Diagnosis and Follow-up of Vasospastic Angina

Kenichi Nakajima, Kuniyoshi Shimizu, Junichi Taki, Yoshihisa Uetani, Shota Konishi, Norihisa Tonami and Kinichi Hisada

Department of Nuclear Medicine, Kanazawa University Hospital, Kanazawa, Japan; and Department of Internal Medicine, Kaga Chuo Hospital, Kaga, Japan

Myocardial damage caused by vasospastic angina (VSA) may be detected by [ $^{123}\text{I}$ ]BMIPP, a beta-methyl-branched fatty acid. We investigated whether BMIPP could be used in the diagnosis and follow-up of patients with VSA. **Methods:** Thirty-two patients with VSA were studied with resting BMIPP-SPECT in comparison to stress perfusion imaging with either  $^{201}\text{Tl}$  or  $^{99\text{m}}\text{Tc}$ -MIBI. During coronary arteriography, spasm was induced by provocative testing with acetylcholine or ergonovine, and only total or subtotal occlusion was considered positive. Decreased BMIPP uptake was semiquantitatively evaluated segmentally aided by polar map display. **Results:** Reduced BMIPP uptake was observed in 25 of 32 patients (78%), with complete or partial agreement between the BMIPP abnormality and coronary territory seen in 23 patients (72%). In contrast, a perfusion abnormality was seen in only 10 patients (31%). In the repeat BMIPP study ( $n = 23$ ) during the follow-up period (average 206 days), 11 of 14 patients who showed BMIPP improvement also had improved angina attacks. Conversely, two of nine patients with nonimproved BMIPP showed improved symptoms ( $p < 0.05$ ). **Conclusion:** BMIPP can detect myocardial injury associated with VSA and may be useful in monitoring response to treatment.

**Key Words:** vasospastic angina; iodine-123-BMIPP; technetium-99m-MIBI; fatty acid metabolism; single-photon emission computed tomography

J Nucl Med 1995; 36:1934-1940

Coronary spasm has been considered to be a cause of variant angina associated with slight or even no coronary atherosclerosis (1). This variant type of angina has been investigated regarding provocation test (2-4) and clinical characteristics (5-12). Although typical symptoms such as resting angina attack, particularly in the morning, and ST elevation on EKG suggest vasospastic angina (VSA), provocative testing by intracoronary injection of acetylcholine or ergonovine is required to confirm coronary spasm (2-4).

Additionally, a  $^{201}\text{Tl}$  exercise study to induce myocardial ischemia is not as sensitive because coronary spasm usually occurs when patients are at rest and spasm is not always induced by exercise (5,6). Although vigorous hyperventilation or systemic alkalosis has been used to provoke coronary artery spasm (9-11), these approaches have not been routinely applied to cardiac nuclear medicine studies.

Fatty acid imaging is considered to be a sensitive method to detect evidence of ischemic attack or injured myocardium by cardiomyopathy (13-23). Therefore, we hypothesized that  $^{123}\text{I}$ -15-(p-iodo-phenyl)-3,R,S-methylpentadecanoic acid (BMIPP) can identify myocardial injury caused by repeated ischemic attacks. If this is true, improved BMIPP findings may be observed in patients who respond to medical treatment. Thus, we compared BMIPP imaging with an exercise perfusion study using  $^{99\text{m}}\text{Tc}$ -hexakis (2-methoxy isobutyl isonitrile) (MIBI) (24-26) or  $^{201}\text{Tl}$  and SPECT. Moreover, BMIPP-SPECT was repeated to evaluate its effectiveness in monitoring response to treatment.

## MATERIALS AND METHODS

### Patients

The study group consisted of 32 patients (24 men, 8 women; mean age  $63 \pm 9$  yr (s.d.), range 44 to 88 yr) who were suspected of having VSA because of resting angina attack. All patients underwent coronary arteriography with provocative test. Resting [ $^{123}\text{I}$ ]BMIPP SPECT and stress and resting perfusion SPECT with either  $^{99\text{m}}\text{Tc}$ -MIBI or  $^{201}\text{Tl}$  were performed within 1 wk. Patients with  $>70\%$  coronary stenosis were excluded and those with a history of myocardial infarction were also excluded. Hypertension was present in 16 patients; the average hypertensive period was  $10 \pm 9$  yr, ranging from 4 mo to 29 yr. Six patients had a history of  $>10$  yr. One patient had slight glucose intolerance. No medication affecting the cardiovascular system was given throughout the coronary arteriography and nuclear studies. The radionuclide study was performed before coronary arteriography.

### Cardiac Catheterization and Provocative Test

Coronary arteriography was performed in the fasting state. A temporary pacing catheter was inserted into the right ventricle, and a connected pulse generator was set to a demand-driven rate of 40 bpm. Both left and right anterior oblique projections were obtained. After a control arteriogram was obtained, acetylcholine chloride or ergonovine maleate was selectively injected into the coronary arteries. Acetylcholine was administered as an incremen-

Received Jan. 23, 1995; revision accepted Jul. 5, 1995.

For correspondence or reprints contact: Kenichi Nakajima, MD, Department of Nuclear Medicine, Kanazawa University Hospital, 13-1 Takara-machi, Kanazawa, 920 Japan.

tal dose of 20 and 100  $\mu\text{g}$ , and ergonovine as a dose of 8 and 40  $\mu\text{g}$ . Contrast medium (Iopamidole) was injected when patients had chest pain associated with ST-segment changes. When patients did not have symptoms, it was started 2 min after intracoronary injection of acetylcholine or 4 min after ergonovine injection. When coronary spasm was induced and did not resolve spontaneously, 2.5 mg isosorbide dinitrate were infused in the coronary artery. Significant coronary spasm was induced in all 32 patients. In 25 patients, coronary spasm was induced in either the right or left coronary artery, whereas an additional provocative test was performed in seven patients since the spasm disappeared spontaneously. Provocative testing was judged as positive only when the following three criteria were satisfied: (a) total or subtotal (99%) coronary occlusion, (b) significant ST-T changes on electrocardiogram and (c) chest pain suggestive of ischemia.

Wall motion analysis was performed by left ventriculography with contrast media ( $n = 31$ ). Left ventriculography was performed before coronary arteriography to avoid the effect of coronary spasm on wall motion. The left ventricular segment was divided into seven segments, i.e., anterobasal, anterolateral, apical, diaphragmatic and posterobasal segments in the right anterior oblique projection, and septal and posterolateral segments in the left anterior oblique projection. The wall motion abnormality was classified into normokinesis (score 0), slight hypokinesis (score 1), severe hypokinesis (score 2), akinesis (score 3) and dyskinesis (score 4) and evaluated by consensus of at least two cardiologists.

### Scintillation Camera and SPECT Study

The SPECT system consisted of a single-head, large-field rectangular (field size  $51.2 \times 37$  cm) gamma camera (3.5 mm FWHM) equipped with a low-energy, high-resolution collimator, which was interfaced to a nuclear medicine computer system.

A total of 45 projection images were obtained with  $180^\circ$  data acquisition with the camera rotating anteriorly from the right anterior oblique  $45^\circ$  to the left posterior oblique  $45^\circ$ . Continuous rotation mode was used with a  $4^\circ$  sampling angle. Total acquisition time was 15 min for the initial  $^{99\text{m}}\text{Tc}$ -MIBI study and 10 min for the second MIBI study, 20 min for  $^{201}\text{Tl}$  stress and reinjection images and 20 min for  $^{123}\text{I}$ BMIPP images. Two  $128 \times 128$  matrix planar images were added in the anterior and left anterior oblique views. Peak energy was centered on 70 keV with a 25% window for  $^{201}\text{Tl}$ , 140 keV with a 20% window for  $^{99\text{m}}\text{Tc}$  and 159 keV with a 20% window for  $^{123}\text{I}$ . Transaxial slices were reconstructed with Butterworth (order 8, cutoff frequency 0.43 cycle/cm) and ramp filters. Vertical long-axis and short-axis slices were also generated. Neither attenuation correction nor scatter correction was performed.

### Iodine-123-BMIPP and Perfusion Studies

Patients were injected with 111 MBq [ $^{123}\text{I}$ ]BMIPP at rest in the fasting state. SPECT imaging was started 20 min later. For perfusion images obtained before September 1993 ( $n = 6$ ), we used  $^{201}\text{Tl}$ . After October 1993,  $^{99\text{m}}\text{Tc}$ -MIBI was used ( $n = 26$ ) because our department began using  $^{99\text{m}}\text{Tc}$ -MIBI as the routine radiopharmaceutical for perfusion studies. In the  $^{201}\text{Tl}$  exercise study, 74 MBq  $^{201}\text{Tl}$  were injected at peak exercise and SPECT data were acquired. Approximately 3 hr later, another 37 MBq were injected and a reinjection SPECT image was obtained. In the  $^{99\text{m}}\text{Tc}$ -MIBI study, we used the 1-day exercise-rest sequence protocol. For the initial injection, 220–300 MBq  $^{99\text{m}}\text{Tc}$ -MIBI were used and SPECT imaging was started 45–60 min later. The second injection used 600 to 740 MBq  $^{99\text{m}}\text{Tc}$ -MIBI and data acquisition was started 45–75 min later. The interval between exercise and rest studies was

2–4 hr. The exercise study was based on multistage exercise, starting at 25 watts, and increased by 25 watts at 2-min intervals. Exercise was terminated when patients reached submaximum stress, fatigue, chest pain or significant EKG changes indicating ischemia. The interval between the  $^{99\text{m}}\text{Tc}$ -MIBI and [ $^{123}\text{I}$ ]BMIPP studies was at least 3 days to avoid crosstalk from the remaining activity of the preceding study.

### Follow-up Study with Iodine-123-BMIPP

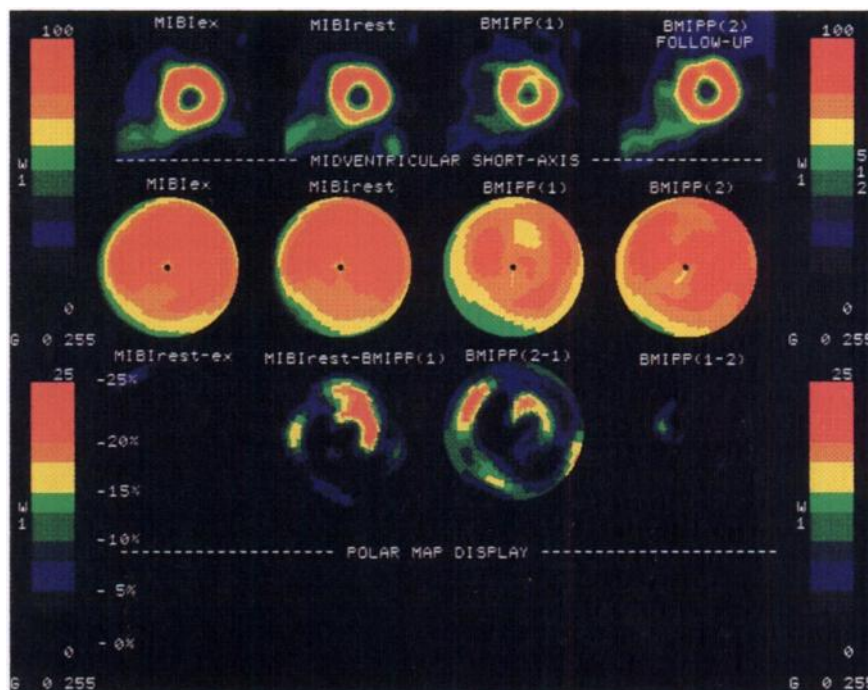
After the diagnosis of VSA, medical treatment was continued in the outpatient clinic, usually with nitrates and calcium antagonists. The cardiologist who was unaware of the results of the second BMIPP study asked patients about the frequency and degree of chest symptoms. BMIPP imaging was repeated during this follow-up period. The average follow-up period between the two BMIPP studies was  $206 \pm 39$  days. Patients who had no chest pain in the follow-up period were classified in the “improvement” group. Two patients who had chest pain only once when they failed to take medication were included in the “improvement” group. Patients who experienced one or more episodes of chest pain during the follow-up period were placed in the “no improvement” group. The intervals between the last angina attack to the BMIPP imaging were studied during the first BMIPP imaging study, as well as in the follow-up study. In the second BMIPP study, if patients did not have chest pain during the follow-up period, the pain-free interval was defined from the start of medical treatment to the second BMIPP study. The interval from the last attack was compared with the BMIPP abnormality.

### Data Analysis

**Visual Analysis.** Abnormality of  $^{99\text{m}}\text{Tc}$ -MIBI was judged by comparing a set of stress and rest images classified into normal, stress-induced ischemia and hypoperfusion without ischemia. On  $^{201}\text{Tl}$  study, exercise and reinjection images were compared. The degree of hypoperfusion was classified into five grades: normal, slight decrease, moderate decrease, severe decrease and defect. Myocardial segments were divided into five regions: anterior, septal, inferoposterior, lateral and apical regions. Correspondence between coronary artery territory and regions were anterior and septal to the left anterior descending artery (LAD), lateral to left circumflex artery (LCx), inferoposterior to right coronary artery (RCA) and the apex in principle artery corresponding to the LAD. The decrease in BMIPP uptake was also classified into five grades using the same regions. If the BMIPP grade was smaller than the MIBI grade, we judged BMIPP uptake to be relatively lower than perfusion uptake. This comparison was useful for excluding possible artifacts, i.e., apparent changes in uptake, such as a hot area of papillary muscle or breast attenuation. In the follow-up BMIPP-SPECT study, improvement by more than one grade was considered significant.

**Quantification.** Although we initially used visual grading, polar map display was used as an adjunctive method to evaluate abnormalities. This quantification was particularly used when the abnormality was borderline. Moreover, visual grading results were accepted only when it was supported by quantitative criteria. When the polar map was abnormal but visually within normal limits, it was considered to represent an artifact, such as attenuation or papillary muscle, and judged as essentially normal. The polar map was the standard program supplied by the manufacturer. The base and apex of short-axis slices were selected using a reference of the vertical long-axis image. The processing area was surrounded by a circular region of interest to exclude hepatic and diaphragmatic activity, and the center of the short-axis myocardium was deter-

**FIGURE 1.** Acetylcholine induced 100% spasm in left anterior descending artery segment 6 of a 51-yr-old man. Technetium-99m-MIBI scan is normal but the [ $^{123}\text{I}$ ]BMIPP image shows anterolateral decrease. Polar map display clearly demonstrates the anterolateral abnormality, and MIBI minus BMIPP subtraction map shows >25% abnormality corresponding to LAD. Upper panel shows mid-ventricular short-axis slices of exercise MIBI, rest MIBI, initial BMIPP and follow-up BMIPP studies. Middle panel represents polar map display of each study. Lower panel shows polar maps of rest MIBI minus exercise MIBI, rest MIBI minus the first BMIPP, second BMIPP minus the first BMIPP and the first BMIPP minus the second BMIPP maps.



mined manually. After circumferential profile analysis was performed in each short-axis slice, it was arranged as a polar map display. In the  $^{201}\text{Tl}$  study, standard patient files were gender-matched (eight men, seven women, respectively) from patients with a low-likelihood of cardiac disease. In the MIBI study, similar gender-matched standard files (seven men, eight women, respectively) were used. A mean of  $-2$  s.d. was used as borderline for abnormality. Visual grading of defects and ischemia was aided by these polar maps. Ischemia was defined as more than 15% count changes from stress to rest or reduction of defect size by more than 20% of the defect area.

The [ $^{123}\text{I}$ ]BMIPP polar map was compared with the  $^{99\text{m}}\text{Tc}$ -MIBI (or  $^{201}\text{Tl}$ ) map. We made subtraction maps between BMIPP and MIBI maps, i.e., both BMIPP minus MIBI and MIBI minus BMIPP as shown in Figure 1. In this map, a difference of 15% was judged as abnormal. Because the regional BMIPP count was usually less than the resting MIBI count on the polar map when myocardial damage was seen, a BMIPP count subtracted from the resting MIBI count  $>0.15$  was considered abnormal. When BMIPP was compared with  $^{201}\text{Tl}$  ( $n = 6$ ), attenuation of  $^{201}\text{Tl}$  activity in the inferoposterior region was considered. The subtraction map was judged in conjunction with the  $^{201}\text{Tl}$  standard map. In the BMIPP follow-up study, a similar subtraction map was generated using pre- and post-treatment polar maps. A change of more than 15% was considered indicative of significant improvement or worsening. The analysis was performed by two nuclear medicine specialists without knowledge of the patient's clinical course.

## Statistics

The values were shown as mean  $\pm$  s.d. Differences between groups were based on contingency table analysis with chi square testing and Fisher's exact probability calculation. The difference in mean values was analyzed using the Student's  $t$ -test. A  $p$  value  $<0.05$  was considered significant.

## RESULTS

### Location of Coronary Spasm

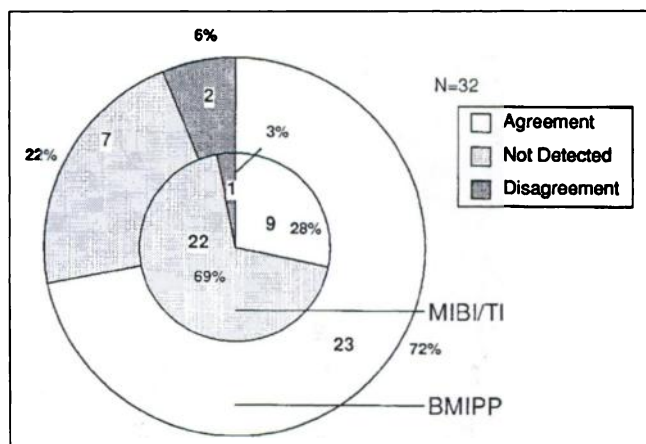
Significant coronary spasm with EKG changes and chest pain was seen in seven patients with RCA, ten with LAD and four with LCx involvement. Total left coronary spasm or both LAD and LCx spasm were observed in 11 patients. Contralateral provocation was performed in seven patients, one of whom showed 95% contralateral RCA stenosis (not significant by our criterion of  $\geq 99\%$ ).

### MIBI or Thallium Study

Ischemia was induced in 8 of 32 (25%) patients. The ischemic finding was slight to moderate, i.e., three with slight ischemia and five with moderate ischemia. Since two patients with hypoperfusion did not show filling at rest, they were suspected of having myocardial injury. As for agreement between regional coronary territory and the SPECT segment, two showed complete agreement, seven showed partial agreement and one showed disagreement. Overall sensitivity for detecting the abnormality was 10 of 32 (31%); MIBI or thallium results agree with coronary arteriography in 9 of 32 patients (28%), as shown in Fig. 2.

### Iodine-123 BMIPP Study

According to visual analysis, 27 patients had wall motion abnormalities. Quantitative criteria with polar mapping, however, demonstrated decreased accumulation in 25. The degree of BMIPP abnormality was 9 patients with a slight decrease, 12 with a moderate decrease, 4 with a severe decrease and no case with defect. Overall, a BMIPP abnormality was seen in 25 of 32 (78%) patients. When the abnormal region was compared to a coronary territory, complete agreement was observed in 10 patients, partial



**FIGURE 2.** Detectability of VSA abnormality in relation to coronary artery spasm. "Agreement" means complete or partial concordance of abnormality between SPECT and coronary arteriography. The inner chart represents MIBI stress-rest or  $^{201}\text{Tl}$  stress-reinjection study; the outer chart is the resting BMIPP study.

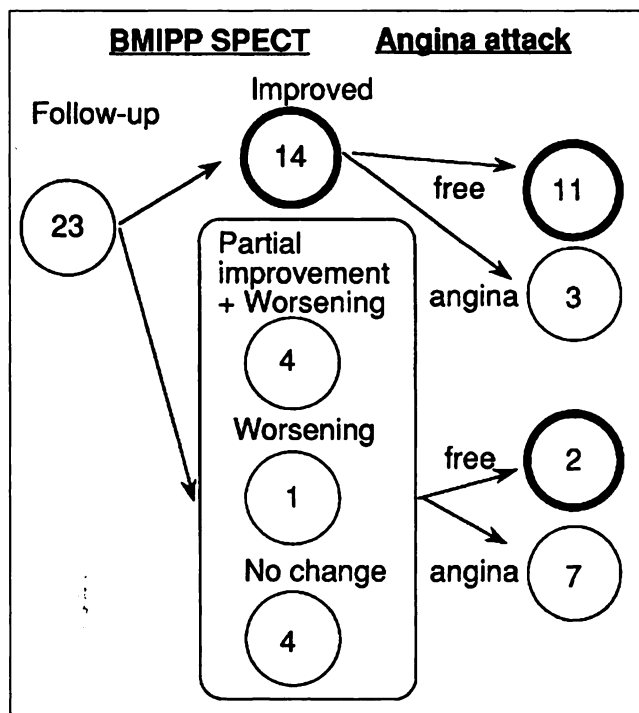
agreement in 13 and disagreement in 2. No decrease in activity was seen in seven patients. Thus, lax agreement between BMIPP and the coronary region was documented in 23 of 32 (72%) patients (Fig. 2).

We also evaluated the relationship between left ventriculography and BMIPP abnormality. In a total of 217 ventricular segments, slight hypokinesis was observed in 114 segments (53%). No patient demonstrated severe hypokinesis, akinesis or dyskinesis. Twenty-six of 31 (84%) patients had at least one hypokinetic segment. Abnormal wall motion with abnormal BMIPP finding was seen in 22 patients (71%). Abnormal wall motion with a normal BMIPP finding was seen in four patients (13%), normal wall motion with abnormal BMIPP findings in three patients (10%) and normal wall motion with a normal BMIPP finding in two patients (6%).

The intervals from the last angina attack to the first BMIPP study were compared between the BMIPP-positive and BMIPP-negative groups. In patients with normal BMIPP findings ( $n = 7$ ), the interval was  $28 \pm 11$  days (range 15–42 days) and  $99 \pm 161$  days (range 5 hr to 450 days) in patients with abnormal BMIPP findings ( $n = 25$ ). Because of the large standard deviation, statistical analysis of the difference of the mean was considered inappropriate.

#### Follow-up BMIPP Study

Repeat BMIPP imaging was performed in 23 patients who had an initial BMIPP abnormality. The results of BMIPP follow-up and changes of angina symptoms are shown in Figure 3. Of 23 patients, 14 showed improvement and 9 had at least partial worsening or no change. Eleven of 14 patients with improved BMIPP findings had no chest pain during follow-up. In contrast, of those with no BMIPP improvement, seven of nine patients still had chest pain. The difference between the two groups was statistically significant ( $p < 0.05$ ). On the other hand, of 13 patients



**FIGURE 3.** Follow-up BMIPP study and clinical course of chest pain.

who had no chest pain during follow-up, 11 had improved BMIPP findings, whereas 7 of 10 patients with chest pain had at least partial worsening or no change on the BMIPP-SPECT study ( $p < 0.05$ ).

The intervals from the last angina attack to the second BMIPP study, which was performed during the follow-up period, were compared between the improved and non-improved groups. In the BMIPP improvement group ( $n = 14$ ), the pain-free interval was  $197 \pm 34$  days (range 140–266 days) after the start of medical treatment and  $76 \pm 106$  days (range 7–295 days) in the nonimprovement group ( $n = 9$ ). Although the standard deviations were large, the improvement group had a longer pain-free interval ( $p = 0.009$ ).

During follow-up, 13/23 patients had no perfusion abnormality and 9 (69%) showed BMIPP improvement. On the other hand, 5 of 10 patients (50%) with a perfusion abnormality showed BMIPP improvement, but the difference was not statistically significant.

## DISCUSSION

### Diagnosis of Coronary Spasm

A variant form of angina pectoris occurring repeatedly at rest with ST-segment elevation was first described by Prinzmetal et al. (1). The symptom occurs even without detectable severe coronary obstruction. Coronary spasm has been known to play a major role in this type of angina (2–12), and attacks with ST-elevation are more readily induced in the early morning (5,8). The diagnosis of VSA essentially depends on the demonstration of coronary spasm by intracoronary injection of ergonovine maleate or



acetylcholine chloride (2–4). Since ischemia is not usually induced by exercise or dipyridamole, routine stress methods with a perfusion imaging agent are not sufficient to induce ischemia. Hence, the role of nuclear perfusion imaging in detecting VSA has been limited. In this respect, we found that [ $^{123}\text{I}$ ]BMIPP is a sensitive method for detecting abnormalities in VSA.

#### **Iodine-123-BMIPP Imaging May Detect Myocardial Injury**

BMIPP is a beta-methyl fatty acid analog in which methyl-branching is introduced to inhibit beta-oxidation (13,14). In contrast to rapid oxidation of the straight-chain iodo-phenyl pentadecanoic acid, BMIPP undergoes slower oxidation and clearance by incorporation in triglycerides, resulting in prolonged residence time. By analyzing the metabolites, [ $^{123}\text{I}$ ]BMIPP seems to be metabolized to *p*- $^{123}\text{I}$ -iodophenyl acetic acid by alpha-oxidation as the first step followed by a beta-oxidation process (15). The early 20-min image, however, is considered to reflect BMIPP uptake rather than fatty acid oxidation. Close correlation between BMIPP uptake and adenosine-5'-triphosphate content also has been described (17). Although BMIPP may not directly reflect energy production as a fatty acid tracer, this unique metabolic trapping is favorable for SPECT imaging. Clinical studies in ischemic heart disease and cardiomyopathy are in progress (20–23,27–30).

It has been postulated that BMIPP detects not only present ischemia but also past ischemic attacks. Disagreement between perfusion abnormality and fatty acid metabolism has often been noted in ischemic heart disease. The application of [ $^{123}\text{I}$ ]BMIPP in acute myocardial infarction and the subacute phase of infarction has been reported previously (16,19,21,27–29). In patients with ischemic heart disease, the BMIPP abnormality is generally more extensive than that of  $^{201}\text{Tl}$ , probably because metabolic activity shows relatively more severe derangement than perfusion. Franken et al. have suggested that mismatching of BMIPP and MIBI, in which fatty acid metabolism was more severely depressed, was indicative of jeopardized but viable myocardium (28), whereas matched defects were considered to be associated with scar. Other studies also showed higher accumulation of  $^{99\text{m}}\text{Tc}$ -MIBI or  $^{201}\text{Tl}$  than that of BMIPP after thrombolysis and/or percutaneous transluminal coronary angioplasty (20,27,29). Tamaki et al. (31), in a PET study, found that [ $^{18}\text{F}$ ]fluorodeoxyglucose uptake was increased in the BMIPP-Tl discordant areas. Whether similar metabolic changes occur in patients with VSA should be investigated.

Moreover, repeated ischemic attacks not suspected as chest pain occur in VSA. Araki et al. (8) reported that 287 of 364 (79%) ST-segment elevations were without chest pain during recording of ambulatory EKG monitoring. Thus, BMIPP may more objectively represent subtle myocardial abnormalities caused by ischemia.

In patients with both exercise-induced ischemia and BMIPP abnormality, the perfusion abnormality may be

caused by myocardial injury at the cellular level or a micro-circulation abnormality because no significant stenosis is found on coronary arteriography. Another possibility is that spasm might be induced by exercise.

#### **BMIPP Uptake and Wall Motion**

In patients with myocardial infarction, wall motion abnormality was often associated with decreased BMIPP uptake (20,28). In this study, patients with VSA had decreased BMIPP activity associated with asynergy. All patients, however, had only slight hypokinesis and no severe asynergy, as in myocardial infarction, was observed. In a few patients, BMIPP uptake was normal despite slight asynergy on ventriculography, possibly because of the frequency and degree of ischemia and the interval after the ischemic attack. In addition, although the frequency of asynergy was relatively high in this study group, it may depend on the patient population and disease severity. Because BMIPP or stress perfusion studies were performed before coronary arteriography with provocation testing, the BMIPP abnormality was not affected by induction of spasm. Moreover, asynergy was not considered to be the effect of induced spasm by the provocation test because left ventriculography was performed before coronary arteriography.

#### **Discrepancy between BMIPP and Coronary Territory**

The findings of abnormal BMIPP region and coronary territory agreed in 72% of the patients, indicating that fatty acid metabolic abnormality is caused by coronary spasm. Two patients, however, showed disagreement in abnormal regions, and partial agreement was observed in about one-half (13/23) of patients. The following explanations can be considered. First, the patient may have multiple coronary spasm. Moreover, coronary artery spasm can occur simultaneously in multiple vessels, with asynergy exhibited in more than one coronary artery region (11). If coronary spasm is induced in one coronary artery by provocative testing and relieved by coronary dilator drugs, the induction of spasm at the contralateral artery becomes difficult. An advantage of BMIPP, however, is that it can detect abnormalities in multiple territories. Second, the active spasm site of a coronary artery may change with time. In addition to repeat ischemia in a specific vascular territory, new active sites of coronary artery spasm could occur. Reduced BMIPP uptake may persist in the inactive region, resulting in overlapping or new abnormal BMIPP regions. Third, repeated ischemic attacks may result in irreversible injury. In this situation, a fixed perfusion defect may be observed. Provocative testing may be negative in this region if it has become inactive.

#### **Scintigraphic Improvement and Course of Chest Pain**

The clinical course of symptoms and changes in BMIPP findings generally agreed. The degree of abnormality is sometimes difficult to estimate by subjective complaints alone, with the extent and severity of BMIPP abnormalities becoming more objective markers for monitoring the effect

of therapy. Some patients, however, showed BMIPP improvement despite persistent symptoms, while others showed improved symptoms without improved BMIPP findings. This discrepancy depended in part on the criteria of subjective improvement. In this study, patients who had a slight degree of chest pain during follow-up were in the nonimprovement group. This included one episode per 169 days (15 days before the second BMIPP study) to several episodes per week of chest pain. The degree of chest pain and frequency during daily life were difficult to quantify based on the subjective criteria. Additionally, possible silent ischemia could be the cause of the discrepancy (8,32,33). If myocardial injury due to silent episodes could be detected by BMIPP imaging, then metabolic imaging would be a better indicator of ischemia than a perfusion study. We could not, however, directly support this hypothesis. Therefore, although some discrepancy was noted in our series, it could not be interpreted as suggesting that BMIPP is useless, but BMIPP may indicate significant pathophysiologic changes in myocardium.

If decreased BMIPP uptake is caused by recent or repeat ischemic attacks, a positive relationship between the pain-free interval and BMIPP finding may be observed. We found, however, that the interval from the last episode of chest pain to the BMIPP study differed considerably among patients; partly because subjective chest pain was difficult to quantify, and partly because frequent silent ischemia might be a factor. Larger series of patients as well as systematic descriptions of patient symptoms are required for statistical analysis.

### Clinical Applications

Our results indicate application of BMIPP imaging in the following situations:

1. Screening tests to determine the necessity of coronary arteriography accompanied by provocation testing. Although sensitivity of 78% may not be perfect in a screening test, noninvasive and reliable methods for diagnosing VSA are not currently available. Given that BMIPP has relatively good sensitivity for detecting ischemia, we believe that patients with typical chest pain at rest and a BMIPP abnormality are good candidates for coronary arteriography. However, decreased BMIPP uptake is not specific for VSA and may be associated with other types of myocardial disease.
2. Coronary artery selection when performing provocative testing. Induction of spasm during the initial test was more important because the second test in the contralateral artery may not be possible after relief of spasm by coronary dilator drugs.
3. Estimating present and past history of myocardial injury caused by spasm. BMIPP could evaluate the current active region of spasm. Since coronary arteriography could not always show more than subtotal (99%) occlusion after provocation, BMIPP can be an

adjunctive method to evaluate the spasm artery territory.

4. Monitoring medical treatment. Success or failure of treatment is usually monitored by the patient's complaints or long-term EKG monitoring. Since chest symptoms are frequently silent (8,32,33) and EKG monitoring for days or weeks is impractical, BMIPP may be a good objective method to estimate recent ischemic history. Although potential utility in such follow-up was indicated, whether BMIPP improvement directly relates to the frequency and degree of ischemia should be investigated.

### Limitations

Although perfusion imaging was performed with  $^{99m}\text{Tc}$  MIBI in most patients, six  $^{201}\text{Tl}$  studies were included. Whereas physical and pharmacological characteristics may differ, we used a gender-matched standard map for comparison. Therefore, the results of this study were not influenced by radiopharmaceutical choice. In assessing BMIPP abnormalities, we compared BMIPP and perfusion study findings. Although a standard map for BMIPP was not available, the criteria of abnormal BMIPP uptake compared to the perfusion study; i.e., MIBI subtracted by BMIPP  $\geq 15\%$ , would be readily applicable in any hospital.

Hypertension should be considered. Because abnormal BMIPP uptake in hypertrophic cardiomyopathy has been reported (22,23), hypertensive heart disease may also influence fatty acid uptake (18). In this series, six patients had a 10-yr or greater history of hypertension. Although the hypertrophic pattern was concentric, decreased BMIPP uptake corresponded to arterial spasm. Hence, abnormal BMIPP uptake was mainly caused by myocardial ischemia and not by secondary hypertensive cardiomyopathy. This observation was also supported by reversible BMIPP findings after treatment. Moreover, better methods to quantify patient symptoms will improve the follow-up results previously mentioned.

### CONCLUSION

In 32 patients with VSA, [ $^{123}\text{I}$ ]BMIPP demonstrated abnormalities in 25 (78%) patients, with complete or partial agreement in the coronary artery territory in 23 (72%) patients. In contrast, perfusion abnormalities, either ischemic or defect, were seen in only 10 (31%) patients. Since those who showed improved BMIPP activity also tended to have improved chest pain ( $p < 0.05$ ), BMIPP-SPECT may be used as a monitor of response to treatment. It may also be useful for screening and selecting arteries for provocation testing.

### ACKNOWLEDGMENTS

The authors thank Ms. Keiko Kawabata, Mr. Katsuya Araie and Mr. Masato Okamura for their technical assistance in quantification. We also thank Mr. John Gelblum for his comments during manuscript editing.

## REFERENCES

- Prinzmetal M, Kenamer R, Meliss R, Wada T, Bor T. Angina pectoris. I. A variant form of angina pectoris. *Am J Med* 1959;27:357-388.
- Heupler FA, Proudfit WL, Razavi M, Shirey EK, Greenstreet R, Sheldon WC. Ergonovine maleate provocative test for coronary artery spasm. *Am J Cardiol* 1978;41:631-640.
- Yasue H, Horio Y, Nakamura N, et al. Induction of coronary artery spasm by acetylcholine in patients with variant angina: possible role of the parasympathetic nervous system in the pathogenesis of coronary artery spasm. *Circulation* 1986;74:955-963.
- Okumura K, Yasue H, Matsuyama K, et al. Sensitivity and specificity of intracoronary injection of acetylcholine for the induction of coronary artery spasm. *J Am Coll Cardiol* 1988;12:883-888.
- Yasue H, Omote S, Takizawa A, Nagao M, Miwa K, Tanaka S. Circadian variation of exercise capacity in patients with Prinzmetal's variant angina: role of exercise-induced coronary arterial spasm. *Circulation* 1979;59:938-948.
- Waters DD, Szychcic J, Bourassa MG, Scholl JM, Theroux P. Exercise testing in patients with variant angina: results, correlation with clinical and angiographic features and prognostic significance. *Circulation* 1982;65:265-274.
- Miller DD, Waters DD, Szychcic J, Theroux P. Clinical characteristics associated with sudden death in patients with variant angina. *Circulation* 1982;66:588-592.
- Araki H, Koiwaya Y, Nakagaki O, Nakamura M. Diurnal distribution of ST-segment elevation and related arrhythmias in patients with variant angina: a study by ambulatory ECG monitoring. *Circulation* 1983;67:995-1000.
- Yasue H, Nagao M, Omote S, Takizawa A, Miwa K, Tanaka S. Coronary arterial spasm and Prinzmetal's variant form of angina induced by hyperventilation and Tris-buffer infusion. *Circulation* 1978;58:56-62.
- Weber S, Cabanes L, Simon JC, et al. Systemic alkalosis as a provocative test for coronary artery spasm in patients with infrequent resting chest pain. *Am Heart J* 1988;115:54-59.
- Fujii H, Yasue H, Okumura K, et al. Hyperventilation-induced simultaneous multivessel coronary spasm in patients with variant angina: an echocardiographic and arteriographic study. *J Am Coll Cardiol* 1988;12:1184-1192.
- Okumura K, Yasue H, Horio Y, et al. Multivessel coronary spasm in patients with variant angina: a study with intracoronary injection of acetylcholine. *Circulation* 1988;77:535-542.
- Goodmann MM, Kirsh G, Knapp Jr FF. Synthesis and evaluation of radioiodinated terminal p-iodophenyl-substituted alpha- and beta-methyl-branched fatty acids. *J Med Chem* 1984;27:390-397.
- Ambrose KR, Owen BA, Goodman MM, Knapp Jr FF. Evaluation of the metabolism in rat hearts of two new radioiodinated 3-methyl-branched fatty acid myocardial imaging agents. *Eur J Nucl Med* 1987;12:486-491.
- Okano S, Yoshimura H, Okano K, et al. Metabolite of 15-p-iodophenyl-3(R,S)-pentadecanoic acid ( $^{123}\text{I}$ ) in blood and urine. *Jpn J Nucl Med* 1992;29:1489-1493.
- Miller DD, Gill JB, Livni E, et al. Fatty acid analogue accumulation: a marker of myocyte viability in ischemic-reperfused myocardium. *Circ Res* 1988;63:681-692.
- Fujibayashi Y, Yonekura Y, Takemura Y, et al. Myocardial accumulation of iodinated beta-methyl-branched fatty acid analogue, iodine-125-15-(p-iodophenyl)-3-(R,S) methylpentadecanoic acid (BMIPP), in relation to ATP concentration. *J Nucl Med* 1990;31:1818-1822.
- Yamamoto K, Som P, Brill AB, et al. Dual-tracer autoradiographic study of  $\beta$ -methyl-(1- $^{14}\text{C}$ )heptadecanoic acid and 15-p-( $^{131}\text{I}$ )-iodophenyl- $\beta$ -methylpentadecanoic acid in normotensive and hypertensive rats. *J Nucl Med* 1986;27:1178-1183.
- Nishimura T, Sago M, Kihara K, et al. Fatty acid myocardial imaging using  $^{123}\text{I}$ - $\beta$ -methylpentadecanoic acid (BMIPP): comparison of myocardial perfusion and fatty acid utilization in canine myocardial infarction (occlusion and reperfusion model). *Eur J Nucl Med* 1989;15:341-345.
- Tamaki N, Kawamoto M, Yonekura Y, et al. Regional metabolic abnormality in relation to perfusion and wall motion in patients with myocardial infarction: assessment with emission tomography using an iodinated branched fatty acid analog. *J Nucl Med* 1992;33:659-667.
- Saito T, Yasuda T, Gold HK, et al. Differentiation of regional perfusion and fatty acid uptake in zones of myocardial injury. *Nucl Med Commun* 1991;12:663-675.
- Kurata C, Tawarahara K, Taguchi T, et al. Myocardial emission computed tomography with iodine-123-labeled beta-methyl-branched fatty acid in patients with hypertrophic cardiomyopathy. *J Nucl Med* 1992;33:6-13.
- Taki J, Nakajima K, Bunko H, et al. Iodine-123-labeled BMIPP fatty acid myocardial scintigraphy in patients with hypertrophic cardiomyopathy: SPECT comparison with stress  $^{201}\text{Tl}$ . *Nucl Med Commun* 1993;14:181-188.
- Wackers FJ, Berman DS, Maddahi J, et al. Technetium-99m hexakis 2-methoxyisobutyl isonitrile: human biodistribution, dosimetry, safety, and preliminary comparison to thallium-201 for myocardial perfusion imaging. *J Nucl Med* 1989;30:301-311.
- Kahn JK, McGhie I, Akers MS, et al. Quantitative rotational tomography with  $^{201}\text{Tl}$  and  $^{99\text{m}}\text{Tc}$ -2-methoxy-isobutyl-isonitrile. A direct comparison in normal individuals and patients with coronary artery disease. *Circulation* 1989;79:1282-1293.
- Berman DS, Kiat HS, Van Train KF, Germano G, Maddahi J, Friedman JD. Myocardial perfusion imaging with technetium-99m-sestamibi: comparative analysis of available imaging protocols. *J Nucl Med* 1994;35:681-688.
- DeGeeter F, Franken PR, Knapp FF, Bossuyt A. Relationship between blood flow and fatty acid metabolism in subacute myocardial infarction: a study by means of  $^{99\text{m}}\text{Tc}$ -sestamibi and  $^{123}\text{I}$ - $\beta$ -methyl-iodo-phenyl pentadecanoic acid. *Eur J Nucl Med* 1994;21:283-291.
- Franken PR, DeGeeter F, Dendale P, Demoor D, Block P, Blossuyt A. Abnormal free fatty acid uptake in subacute myocardial infarction after coronary thrombolysis: correlation with wall motion and inotropic reserve. *J Nucl Med* 1994;35:1758-1765.
- Nakajima K, Shuke N, Nitta Y, et al. Comparison of Tc-99m pyrophosphate, Tl-201 perfusion, I-123 labeled methyl-branched fatty acid and sympathetic imaging in acute coronary syndrome. *Nucl Med Commun* 1995;16:494-503.
- Matsunari I, Saga T, Taki J, et al. Kinetics of iodine-123-BMIPP in patients with prior myocardial infarction: assessment with dynamic rest and stress images compared with stress thallium-201 SPECT. *J Nucl Med* 1994;35:1279-1285.
- Tamaki N, Kawamoto M, Yonekura Y, et al. Assessment of fatty acid metabolism using I-123 branched fatty acid: comparison with positron emission tomography. *Ann Nucl Med* 1993;7:SII-41-SII-47.
- Amsterdam EA. Relation of silent myocardial ischemia to ventricular arrhythmias and sudden death. *Am J Cardiol* 1988;62:241-271.
- Beller GA. Myocardial perfusion imaging for detection of silent myocardial ischemia. *Am J Cardiol* 1988;61:22F-28F.