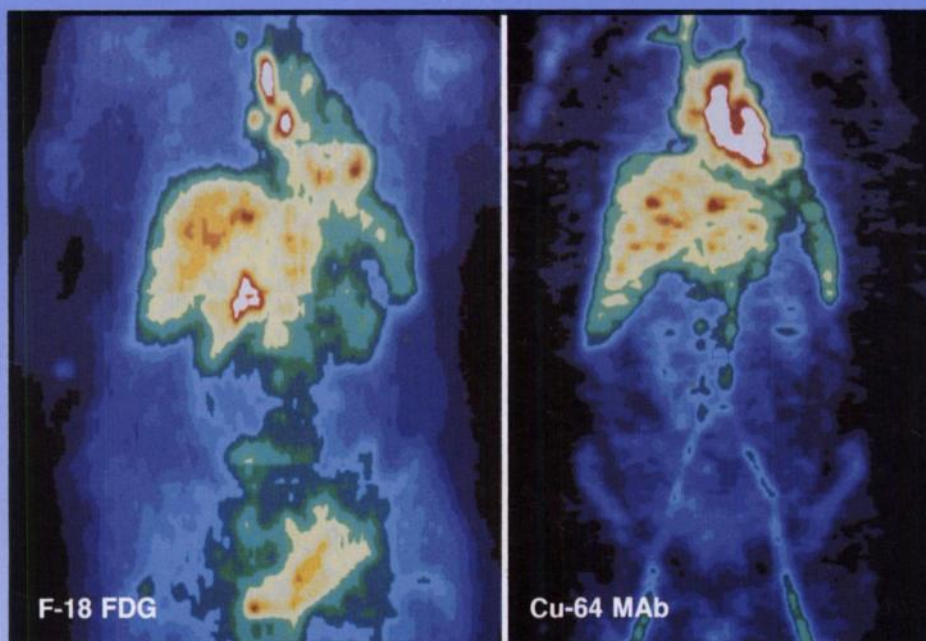

The Journal of Nuclear Medicine

JNM

Volume 36, Number 10 • October 1995



Positive ^{18}F FDG and negative ^{64}Cu -MAb 1A3 images of a woman with a history of rectal carcinoma who subsequently developed lymphadenopathy. See pages 1818-1824.



The Official Publication of
the Society of Nuclear Medicine, Inc.
