

Positional Biliary Stasis: Scintigraphic Findings Following Biliary-Enteric Bypass Surgery

Marvin H. Lucas, Abdelhamid H. Elgazzar and Dwight D. Cummings

Eugene L. Saenger Radioisotope Laboratory, Department of Radiology, University of Cincinnati Hospital, Cincinnati, Ohio

Hepatobiliary scintigraphy has proven to be a reliable noninvasive imaging modality to evaluate postoperative biliary obstruction, which is a frequent complication following biliary enteric bypass surgery. We present a case of a patient who had biliary enteric bypass surgery with a scintigraphic pattern simulating partial obstruction on a ^{99m}Tc hepatobiliary study performed with the patient in a supine position. The biliary stasis seen in the supine images disappeared almost completely when the images were repeated after 30 min in an upright position. Progressive accumulation of activity initially seen in the region of the biliary enteric anastomosis was not present 3 days later on a repeat study with the patient in an upright position, confirming that biliary stasis in this patient was due to a positional phenomenon. This case illustrates that biliary stasis may be positional in nature. Position related stasis should be a consideration when interpreting hepatobiliary scintigraphic studies in postoperative patients and when suspected, patients should be imaged in the upright position.

Key Words: scintigraphy; hepatobiliary; biliary enteric bypass; biliary stasis; biliary obstruction

J Nucl Med 1995; 36:104-106

Hepatobiliary imaging using ^{99m}Tc -labeled iminodiacetic acid (IDA) compounds is routinely performed for functional imaging of the biliary tract. The most common application of this procedure is in diagnosing acute cholecystitis. Evaluating biliary-enteric bypass procedures for either biliary leakage or recurrent obstruction is another situation where cholescintigraphy has left its mark (1-6).

Postoperative complications of biliary-enteric bypass procedures are relatively common. Potential problems in the early postoperative period include wound sepsis, wound hematoma, subhepatic abscess, hemoperitoneum and bile leak (7). Operative mortality has been reported in up to 4% of cases (8,9). Long-term complications include: recurrent obstruction, cholangitis, peptic ulcer disease, intrahepatic cholelithiasis and recurrent pain of uncertain

etiology (7-9). Obstruction, partial or complete, is a relatively common complication of biliary-enteric bypass surgery occurring in up to 23% of patients (8).

In this study, a patient with a Roux-en-Y hepaticojejunostomy suspected of having biliary obstruction was found by cholescintigraphy to have position-dependent stasis in the region of the hepaticojejunal anastomosis that simulated a scintigraphic pattern of partial biliary obstruction.

CASE REPORT

A 34-yr-old male with a history of Hodgkin's lymphoma and perihepatic involvement underwent a choledochojejunostomy procedure to relieve biliary obstruction. Subsequently, because of recurrent strictures, a Roux-en-Y hepaticojejunostomy was performed using the technique of Blumgart and Kelley (10) with a 4-cm side-to-side anastomosis of the left hepatic duct to a Roux-en-Y loop of jejunum (Fig. 1). The patient was referred for hepatobiliary imaging 6 wk later to exclude recurrent biliary obstruction due to persistently elevated alkaline phosphatase and a continuous dull ache in his back.

Upon referral for hepatobiliary imaging his laboratory values were as follows: alkaline phosphatase 212 mIU/ml (normal 35-95); total bilirubin 0.36 mg/dl (normal 0.1-1.1); gamma-glutamyltransferase 287 mIU/ml (normal 8-40); alanine aminotransferase (SGPT) 72 IU/liter (normal 7-35); aspartate aminotransferase (SGOT) 56 IU/liter (normal 10-30); albumin 4.1 gm/dl (normal 3.5-5.0); WBC 11.3 K/cumm (normal 4.8-10.8); hemoglobin 10.7 g/dl (normal 14-18); hematocrit 31.7% (normal 42-52) and platelet count 542 K/cumm (normal 150-375).

Following the administration of 4.48 mCi of ^{99m}Tc mebrofenin intravenously via an indwelling catheter, 5-min sequential images were obtained for 60 min. These images (Fig. 2) revealed significant and progressive accumulation of radionuclide activity within the proximal Roux-en-Y hepaticojejunal segment. Minimal transit into the small intestine was seen by 25 min which increased slightly by 55-60 min. The patient sat upright for half an hour before a 90-min delayed image was obtained. The 90-min image showed near-complete clearance of activity from the hepaticojejunal segment with the radiopharmaceutical seen clearly within the intestine. It was then suspected that the accumulation of radionuclide activity within the biliary-enteric anastomosis may have been related to the patient being in the supine position during the study. Accordingly, it was decided to repeat the study with the patient in the upright position during acquisition.

The patient returned 3 days later and was injected with 10.55 mCi of ^{99m}Tc -mebrofenin. Images were obtained every 5 min for

Received Feb. 16, 1994; revision accepted Aug. 11, 1994.
For correspondence or reprints contact: Abdelhamid H. Elgazzar, MD, University of Cincinnati Hospital, P.O. Box 670577, Cincinnati, OH 45267-0577.

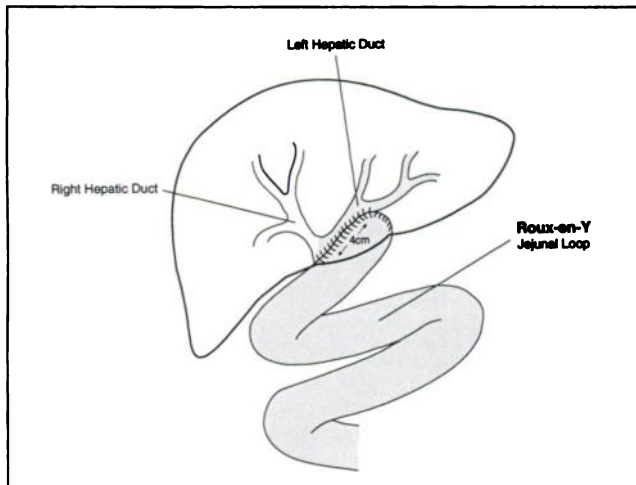


FIGURE 1. A schematic diagram of the hepaticojejunal bypass. The left hepatic duct was anastomosed side-to-side with a 4-cm segment of the Roux-en-Y jejunal loop. The Roux limb was approximately 70 cm in total length.

55 min in the upright position (Fig. 3). The radiopharmaceutical was seen promptly passing through the hepaticojejunal anastomosis and entering the small intestine. Compared to the initial study, performed in the supine position, there was no evidence of significant accumulation of activity in the region of the hepaticojejunal anastomosis and Roux limb. Significant emptying into the small intestine occurred, indicating that the accumulation seen on the previous study was in fact position-dependent and that no biliary obstruction was present.

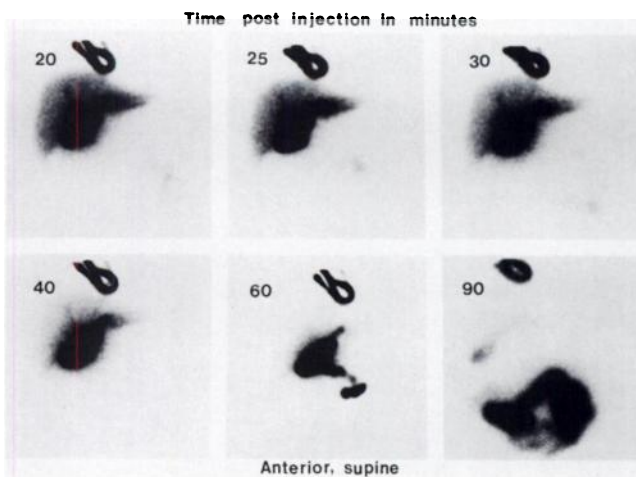


FIGURE 2. Selected images of the initial ^{99m}Tc -mebrofenin hepatobiliary study following administration of the radiopharmaceutical via an indwelling catheter. There is progressive accumulation of the radioisotope in the region of the biliary-enteric bypass anastomosis demonstrating the "blooming" effect. Only minimal activity within the intestine is noted by 1 hr. The gallbladder is surgically absent and therefore was not visualized. A 90-min image obtained after the patient sat upright for 30 min shows significant clearance of activity in the region of anastomosis with the majority of the radiopharmaceutical seen in the intestine. No evidence of biliary leakage was identified.

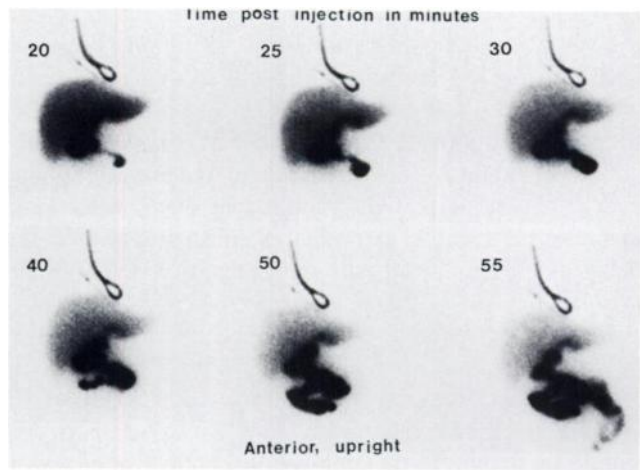


FIGURE 3. Repeat hepatobiliary scintigraphy performed with the patient in the upright position three days later. At 20 min postinjection, passage of the radionuclide into the Roux-en-Y limb is clearly seen. With the patient remaining in the upright position, there is evidence of good and prompt biliary flow into the intestine between 25–55 min. The significant accumulation of the radionuclide in the region of anastomosis seen on the initial supine study is no longer noted.

DISCUSSION

Methods of evaluating a biliary-enteric bypass for obstruction or other postoperative complications include hepatobiliary scintigraphy, ultrasonography, cross-sectional imaging, endoscopic retrograde cholangiopancreatography (ERCP) and percutaneous transhepatic cholangiography (PTC). ERCP and PTC are used to define the anatomy of the biliary tree and when the need for possible intervention is anticipated. The use of ultrasound as a noninvasive technique for detection of biliary-enteric bypass obstruction is limited by two factors. First, the presence of gas within the bowel or the biliary tree following surgery creates difficulties in the assessment of biliary duct size. As many as 50% of postsurgical ultrasounds have been reported as indeterminate for this reason (11). Second, if the size of the biliary ducts can be measured, ductal dilatation does not necessarily indicate an obstructive pattern in this population as dilatation may persist after surgical relief of obstruction.

Comparison of ultrasonography and hepatobiliary imaging in the evaluation of biliary-enteric anastomoses was reported (3). The 23 patients in the study had a total of 36 sonograms and 36 hepatobiliary scintigrams. Ultrasound was indeterminate in 14% of the cases because of excessive biliary or enteric air. When dilated biliary ducts were apparent, scintigraphy allowed differentiation of dilatation due to obstruction as opposed to persistently dilated postoperative ducts without obstruction.

The different scintigraphic patterns in patients following biliary-enteric bypass surgery have been described in a review of 73 hepatobiliary scintigraphic studies in 56 patients with biliary-enteric bypass anastomoses (2).

A normal scan was defined as intestinal excretion in less than an hour without ductal dilatation. Intestinal excretion in less than an hour with evidence of ductal dilatation was found to constitute functional patency. Intestinal excretion at 1 hr or longer indicated partial obstruction although the scintigraphic pattern of pooling and retention of activity in the bile ducts was found to be more reliable in predicting obstruction than the delayed appearance of intestinal activity (3). Persistent nonvisualization of the biliary system and intestine suggested the presence of a virtually complete biliary duct obstruction.

In our case, minimal intestinal excretion was seen by 1 hr on the initial scintigraphic study; however, there was significant pooling of the radiopharmaceutical in the region of the anastomosis, a scintigraphic appearance which is referred to as "blooming" (12).

The pooling of the radiopharmaceutical observed during the initial assessment of our patient was no longer present when the study was repeated in the upright position 3 days later. To our knowledge, positional stasis within a biliary-enteric bypass anastomosis has not been previously reported.

Decreased limited intestinal visualization on hepatobiliary studies has been interpreted as indicative of partial obstruction (2,3,6,13). This may lead to unnecessary invasive evaluations if positional stasis is the cause of this scintigraphic pattern. Thus, we suggest that in the setting of progressive accumulation of radionuclide activity in the

region of anastomosis in patients with previous biliary-enteric bypass surgery, the patient should be imaged in the upright position to exclude the possibility of positional stasis.

REFERENCES

1. Rosenthal L, Shaffer EA, Lisbona R, et al. Diagnosis of hepatobiliary disease by Tc-99m-HIDA cholescintigraphy. *Radiology* 1978;126:467-474.
2. Weissmann HS, Gliedman ML, Wilk PJ, et al. Evaluation of the postoperative patient with ^{99m}Tc-IDA cholescintigraphy. *Semin Nucl Med* 1982;12:27-52.
3. Zeman RK, Lee C, Stahl RS, et al. Ultrasonography and hepatobiliary scintigraphy in the assessment of biliary-enteric anastomoses. *Radiology* 1982;145:109-115.
4. Cote C, Carrier L, Picard D, et al. Asynchronous washout of the liver as a sign of partial biliary obstruction. *Clin Nucl Med* 1985;10:44-45.
5. Tidmore H, Ram MD. Scintiscanning in the evaluation of biliary enteric anastomoses. *Am Surg* 1985;51:158-161.
6. Belli G, Romano G, Monaco A, et al. HIDA scan in the follow-up of biliary-enteric anastomoses. *HPB Surg* 1988;1:29-32.
7. Bismuth H, Franco D, Corlette MB, et al. Long-term results of Roux-en-Y hepaticojejunostomy. *Surg Gyn Ob* 1978;146:161-167.
8. Lane CE, Sawyers JL, Riddell DH. Long-term results of Roux-en-Y hepatocholechojejunostomy. *Ann Surg* 1973;177:714-720.
9. Stefanini P, Carboni M, Petrassi N, et al. Roux-en-Y hepaticojejunostomy: a reappraisal of its indications and results. *Ann Surg* 1975;181:213-219.
10. Blumgart LH, Kelley CJ. Hepaticojejunostomy in benign and malignant high bile duct stricture: approaches to the left hepatic ducts. *Br J Surg* 1984;71:257-261.
11. Sample WF, Sarti DA, Goldstein LI, et al. Gray-scale ultrasonography of the jaundiced patient. *Radiology* 1978;128:719-725.
12. Lisbona R, Wexler MW, Novalés-Díaz JA. Pitfalls to avoid: misleading appearance of biliary dilatation. *J Can Assoc Rad* 1980;31:67-68.
13. Krishnamurthy S, Krishnamurthy GT, Lieberman D, et al. Scintigraphic criteria for the diagnosis of obstructive hepatobiliary diseases with ^{99m}Tc-IDA. *Clin Nucl Med* 1988;13:704-709.