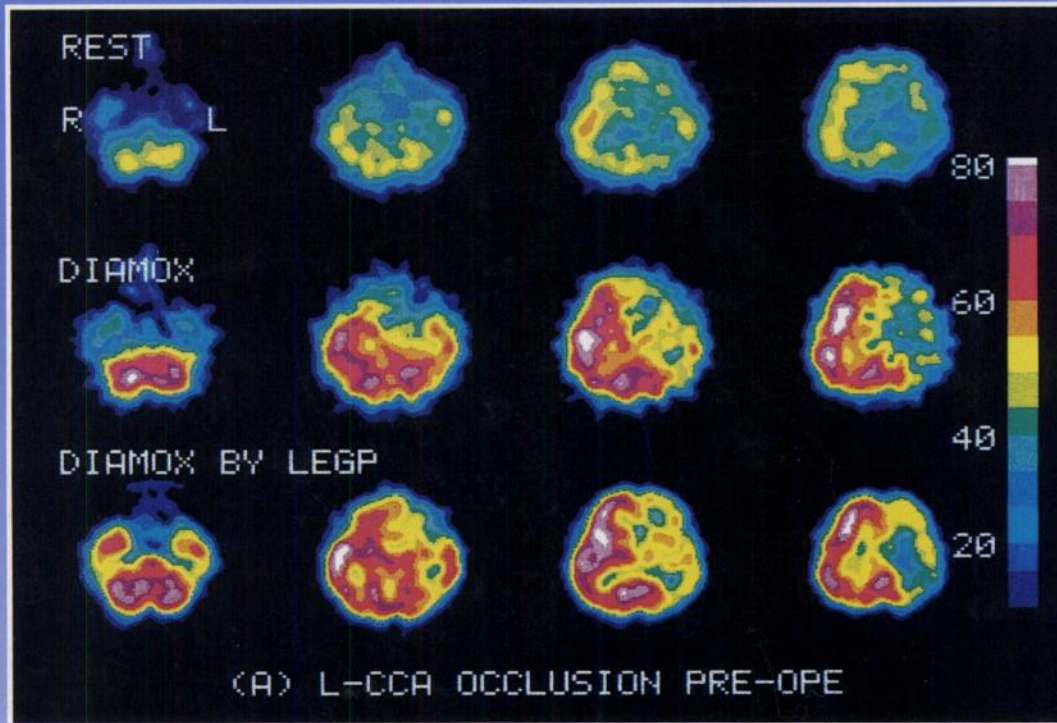


Judy Buchanan

The Journal of Nuclear Medicine

JNMM

Volume 35, Number 7 • July 1994



Preoperative SPECT ^{123}I -IMP images in a 58-yr-old man with left common carotid artery occlusion. See pages 1226-1233.



The Official Publication of
The Society of Nuclear Medicine, Inc.