

---

# Effects of Hyperglycemia on FDG Uptake in Human Brain and Glioma

Koichi Ishizu, Sadahiko Nishizawa, Yoshiharu Yonekura, Norihiro Sadato, Yasuhiro Magata, Nagara Tamaki, Tatsuro Tsuchida, Hidehiko Okazawa, Shin-ichi Miyatake, Masatsune Ishikawa, Haruhiko Kikuchi and Junji Konishi

*Departments of Nuclear Medicine and Brain Pathophysiology and Neurosurgery, Faculty of Medicine, Kyoto University, Kyoto, Japan*

---

This study evaluates the effects of hyperglycemia on fluorodeoxyglucose (FDG) uptake in the human brain and in brain tumors. **Methods:** We performed glucose loading during FDG PET studies in nine patients with brain tumors (eight gliomas and one brain metastasis) and one with resected glioma. Two FDG PET scans were obtained in all cases within 1 wk in a control state and with glucose loading by intravenous infusion of 10% glucose solution. Serial arterial blood sampling was performed in all cases to obtain fractional uptake of FDG normalized by the plasma integral uptake of radioactivity (FU). **Results:** In all nine patients with brain tumors, the tumor was depicted more clearly with glucose loading than in the control state. Glucose loading decreased FU in the cerebral cortex ( $54.2\% \pm 13.8\%$ ) nearly in inverse proportion to the plasma glucose level, while the tumors showed a decrease ( $42.5\% \pm 15.6\%$ ), resulting in an increased tumor-to-cortex ratio by  $26.0\% \pm 5.7\%$ . Fractional uptake in the cerebellum, white matter and the edematous area also decreased by glucose loading ( $53.9\% \pm 13.2\%$ ,  $49.6\% \pm 10.3\%$  and  $34.9\% \pm 9.6\%$ , respectively). **Conclusion:** These results demonstrate the different effects of hyperglycemia on normal brain tissue and on tumor, suggesting that glucose loading may be a valuable adjunct to FDG PET to enhance detection of recurrent or residual brain tumors

**Key Words:** fluorodeoxyglucose; PET; brain tumor; glucose loading

**J Nucl Med 1994; 35:1104-1109**

---

**P**ET using [ $^{18}\text{F}$ ]-2-fluoro-2-deoxy-D-glucose (FDG) enables the in vivo measurement of regional glucose metabolism of brain (1-3) and brain neoplasms. Increased glucose uptake in malignant gliomas compared to normal brain tissues is well established, and FDG PET is now widely applied to brain tumor patients for tumor grading, detection of recurrent or residual tumors and prediction of clinical outcome (4-8). Additionally, FDG PET has been

demonstrated to be the most reliable method for differentiation of recurrent tumors from radiation necrosis (9,10).

Glucose is a major substrate for brain energy metabolism, and a significant fraction of glucose metabolism is coupled to neuronal activity. As FDG enters the nerve cells using the same facilitated transport system as glucose, elevated plasma glucose levels should result in decreased FDG uptake in the brain. Although the influence of hyperglycemia on FDG uptake was recently reported in human extracranial tumors (11,12), little is known about the effects of hyperglycemia on FDG uptake and PET imaging of brain tumors.

We hypothesized that glioma cells may lack the normal physiological control of glucose metabolism in neuronal cells. In order to test this hypothesis and to examine the capability to enhance detection of brain tumors by glucose loading, we measured the magnitude of reduction of FDG uptake in normal and neoplastic parenchyma by hyperglycemia using paired FDG PET studies with intravenous glucose loading and nonloading.

## MATERIALS AND METHODS

### Subjects

A total of ten patients, seven males and three females, mean age 46.3 yr (range 29 to 70 yr), were studied. They included eight gliomas, one metastatic brain tumor with unknown origin, and one with total resection of glioma. Table 1 shows the clinical data for the patients. Diagnosis was established histologically in all patients by previous or later surgery. Six patients had recurrent tumors after previous surgery, irradiation and/or chemotherapy, and three patients had not received any treatment prior to PET scanning. These nine cases showed clear evidence of a solid mass by magnetic resonance (MR) imaging and/or x-ray computed tomography (CT) scan. One patient had no recurrent mass on MR and CT images after complete surgical resection. None had deficiency of glucose tolerance.

The study was performed under the guidance of the ethical committee of Kyoto University Hospital, and informed consent was obtained from all patients.

### Tomograph Characteristics

The PET study was performed using a multislice whole-body PET scanner (PCT-3600W, Hitachi Medical Co., Tokyo) (13). This system simultaneously acquires 15 slices with a center-to-

---

Received Oct. 5, 1993; revision accepted Mar. 1, 1994.  
For correspondence or reprints contact: Koichi Ishizu, MD, Department of Nuclear Medicine, Faculty of Medicine, Kyoto University, Shogoin, Sakyo-ku, Kyoto 606-01, Japan.

**TABLE 1**  
Patient's Data

Patient no.	Age	Sex	Histology (Grade)	Previous therapy		Interval (month) from first therapy	CT or MR findings
				Surgery	Irradiation		
1	70	F	Glioblastoma	None	None	—	lt. parasagittal, ring enhanced mass with central necrosis (CT, MR)
2	42	F	Glioblastoma	Partial	69 Gy	8	lt. temporo-parietal, ring enhanced mass with peripheral edema and central necrosis (CT)
3	31	M	Glioblastoma	Partial	69 Gy	7	lt. temporo-parietal, well enhanced mass with peripheral edema (CT)
4	64	M	Oligodendroglioma	None	None	—	lt. frontal, Gd-enhanced mass with calcified area (CT, MR)
5	29	M	Astrocytoma (III)	Partial	None	1	lt. thalamic, poorly enhanced mass (MR)
6	70	M	Glioblastoma	Partial	None	0.5	rt. parietal, ring enhanced mass (CT, MR)
7	56	M	Glioblastoma	Partial	41 Gy+ 23.5 Gy (Ir-192)	10	lt. thalamus, with periferal edema (MR)
8	30	M	Glioblastoma	Partial	50 Gy	94	rt. frontal, partially Gd-enhanced (MR)
9	33	F	Metastatic tumor	None	None	—	lt. parietal, ring enhanced mass with periferal edema (CT, MR)
10	38	M	Astrocytoma (II)	Lobectomy	None	1	rt. frontal, fluid collection after lobectomy (CT, MR)

lt. = left, rt. = right, Gd = gadolinium.

center distance of 7 mm. All scans were obtained at a resolution of 7.5 mm (FWHM) in the transaxial direction and 6.5 mm in the axial direction using detector wobbling. The matrix size of the reconstructed image was 128 × 128, and the pixel size was 2 × 2 mm. Prior to all emission measurements, tomographic transmission data were obtained for calculation of regional attenuation coefficients using a standard plate source of <sup>68</sup>Ge/<sup>68</sup>Ga. The tissue activity concentration in the PET images was cross-calibrated against the well counter using a cylindrical phantom filled with <sup>18</sup>F solution.

### Scan Protocol

Two FDG PET scans were obtained from all patients within a week in the control state and with glucose loading. Between the two scans, no substantial therapeutic intervention such as surgery, radiotherapy or chemotherapy (without steroid therapy) was performed on any of the patients. The control study was done before the loading study in seven patients, and conversely in the other three cases. A small catheter was placed in each patient's brachial artery for blood sampling.

Patients received 4.4 to 10.3 mCi of FDG by intravenous injection. PET imaging was started about 40 min after FDG injection, obtaining a static scan of 20 min duration. Arterial blood samples were obtained manually 16 times from the time of injection to the end of the study, and plasma activity was measured for quantitative calculation of FDG uptake.

The patient's head was positioned by two laser pointers in the head-holder equipped with the scanner. The lowest slice of the trans-axial plane was placed above the canthomeatal plane (CM); a plane through the lateral canthus of the eye and the external opening of the ear.

### Control of Plasma Glucose Level

**Glucose Loading Study.** Intravenous infusion of 10% glucose solution was started 10–15 min before FDG injection and continued until the end of the study. Total infused volume of glucose solution was approximately 500 ml (50 g of glucose), and the

infusion speed (5–7 ml/min) was kept constant throughout the scan. Plasma glucose levels were measured six times during the glucose loading study, i.e., before glucose loading, just before FDG injection, 6, 15, 30 and 60 min after FDG injection. During glucose loading, we also measured blood glucose levels several times by dextrometer in order to avoid excessive hyperglycemia.

**Control Study.** The control study was performed with at least 2 hr of fasting prior to the examination. In the control studies, plasma glucose levels were measured three times: before FDG injection, 30 min and 60 min after injection.

### Data Analysis

Tissue activity images of FDG were used for the region of interest (ROI) based analysis. On the reconstructed FDG images, similar sized areas corresponding to the solid tumor mass on the representative slice in CT and/or MR with positive FDG uptake were outlined excluding areas of presumed edema or necrosis. Irregular ROIs were also placed on the representative area of contralateral gray matter, ipsilateral cerebellar hemisphere, contralateral white matter and the edematous region surrounding the tumor. Similar sized ROIs were placed for control and glucose loading PET images. In one patient with complete resection, ROIs were not placed on the tumor.

Semiquantitative values of FDG uptake were obtained by applying the standardized uptake value (SUV), which has been popularly used to assess tumor uptake with PET. The SUV was calculated by normalizing the injected dose of FDG per body weight according to the following equation:

$$SUV = \frac{C(T)}{(\text{injected dose/body weight})}, \quad \text{Eq. 1}$$

where C(T) is tissue FDG activity obtained by the PET scanner. Although SUV is a simple and useful parameter, it may not be accurate to compare the two studies with significant changes in arterial input of FDG. Because dietary conditions influence the plasma glucose and FDG kinetics, we measured the fractional

uptake (FU) of FDG normalized by plasma FDG activity as the following equation:

$$FU = C(T) / \int_0^T C_p(t) dt, \quad \text{Eq. 2}$$

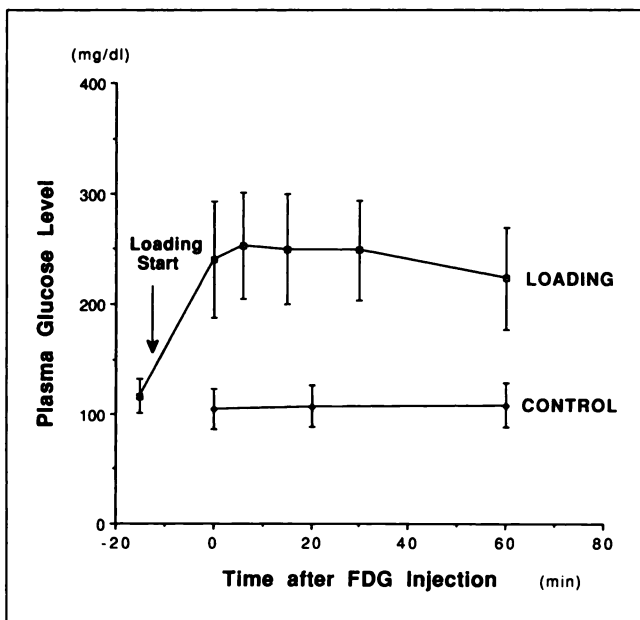
$C_p(t)$  is plasma activity of FDG obtained by serial arterial sampling (14,15). Both FU and SUV are dimensionless parameters.

FDG uptake in these ROIs was compared between the control state and loading state. Also calculated was the tumor-to-cortex ratio of FDG uptake in both states.

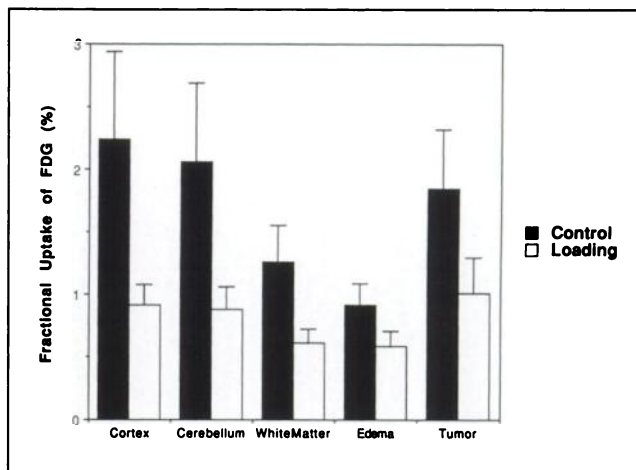
## RESULTS

The mean plasma glucose level of ten patients was  $106.8 \pm 18.9$  mg/dl ( $5.93 \pm 1.05$  mmole/liter) (mean  $\pm$  s.d.) in the control state, and  $242.5 \pm 43.4$  mg/dl ( $13.47 \pm 2.41$  mmole/liter) with glucose loading ( $p < 0.001$ ). Figure 1 shows serial changes in plasma glucose levels in control and glucose loading studies, indicating reasonably stable values during the initial uptake phase of FDG.

In the glucose loading study, FDG uptake, measured as FUs and SUVs, decreased markedly in all normal tissues and abnormal lesions. As shown in Figure 2, hyperglycemia induced a significant reduction of FU of FDG in all areas (cortex  $2.24 \pm 0.70$  to  $0.91 \pm 0.17$ , cerebellum  $2.06 \pm 0.63$  to  $0.88 \pm 0.18$ , white matter  $1.26 \pm 0.29$  to  $0.61 \pm 0.11$ , edematous region  $0.92 \pm 0.17$  to  $0.59 \pm 0.12$ , tumor  $1.84 \pm 0.48$  to  $1.01 \pm 0.28$ ) ( $p < 0.01$ ). However, tumors showed less of a reduction compared with the normal brain regions. Table 2 summarizes the quantitative values of FDG uptake in cerebral cortices and tumors. Glucose loading caused a  $54.2\% \pm 13.8\%$  decrease of FU in the con-



**FIGURE 1.** Serial changes in plasma glucose levels in control and glucose loading studies. Mean values with standard deviation of ten patients are shown. Glucose loading started about 15 min before FDG injection and continued during the loading study. The glucose level was sufficiently stable during the initial uptake phase of FDG.



**FIGURE 2.** Fractional uptake of FDG in control (black column) and glucose loading (white column) studies. FU values in the cortex, cerebellum, white matter, edema and tumor decreased significantly in the glucose loading study ( $p < 0.005$ ). Column and bar show mean and standard deviation, respectively.

tralateral cortices and  $42.5\% \pm 15.6\%$  decrease in tumors, resulting in an average increase of  $26.0\% \pm 5.7\%$  in the tumor-to-cortex ratio. SUV also decreased  $62.6\% \pm 13.8\%$  in the contralateral cortices and  $49.9\% \pm 16.3\%$  in tumors by glucose loading.

Figure 3 shows the average changes of fractional uptake of FDG by glucose loading in cerebral cortex and brain tumors, indicating that the fractional uptake of FDG in the cerebral cortex changed in good proportion to the reciprocal of plasma glucose values.

In nine patients with brain tumors, the tumor was visually recognized more clearly in glucose loading PET images than in the control study, although visible in both occasions. Figure 4 shows FDG PET images and the gadolinium enhanced MR image of Patient 4. FDG uptake in the tumor was more easily depicted in the glucose loading FDG PET image. One case with successful complete resection of the tumor showed no evidence of FDG tumor uptake in either state. No patient had symptoms caused by hyperglycemia.

## DISCUSSION

Our results showed that hyperglycemia reduced FU in human brain tumors less than in normal brain, resulting in higher tumor-to-gray matter ratio. Glucose metabolism in human gliomas tends to be high, but in clinical situations high uptake of FDG in normal gray matter makes it difficult to differentiate the lesion from normal tissue. It has been reported that reduction of FDG uptake in normal brain tissues would improve the detection of brain tumors using barbiturates to suppress glucose utilization in the brain (16,17). This theory is simple and the effect of barbiturates is evident in enhanced detection of brain tumors, however, the procedure is complicated and invasive. Glucose loading also increased the tumor-to-cortex ratio of FDG uptake, and is expected to make more distinct visualization of

**TABLE 2**  
FDG Uptake in Control and Glucose Loading

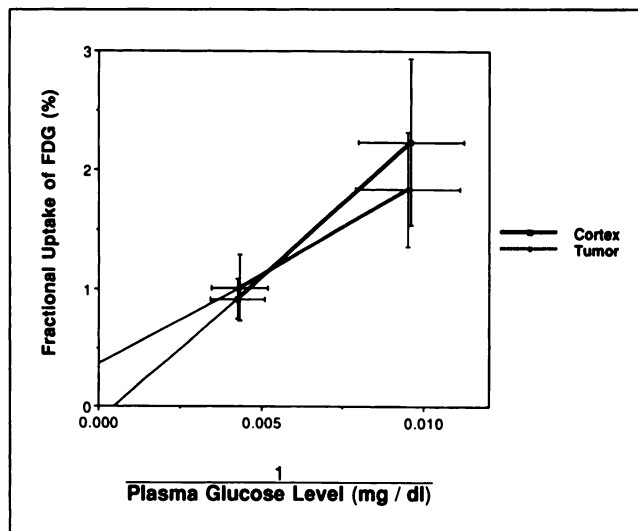
Patient no.	Cortex or Tumor	Plasma glucose		FU		SUV		TCR		% Increase
		Cont	Glu	Cont	Glu	Cont	Glu	Cont	Glu	
1	Cortex	128	295	1.96	0.99	4.12	1.61			
	Tumor			1.60	1.00	3.36	1.63	0.816	1.014	23.8
2	Cortex	96	250	3.05	1.08	4.02	1.40			
	Tumor			2.12	0.99	2.79	1.29	0.695	0.917	31.8
3	Cortex	107	171	2.18	1.26	4.95	2.67			
	Tumor			2.40	1.75	5.45	3.71	1.100	1.388	26.4
4	Cortex	89	258	3.30	0.81	5.86	1.28			
	Tumor			2.59	0.84	4.59	1.32	0.784	1.035	32.0
5	Cortex	82	251	2.60	0.76	4.97	0.96			
	Tumor			1.97	0.75	3.77	0.95	0.757	0.991	30.9
6	Cortex	136	251	1.19	0.77	2.42	1.16			
	Tumor			1.09	0.83	2.21	1.24	0.914	1.073	17.3
7	Cortex	135	189	1.20	0.82	2.77	1.80			
	Tumor			1.33	1.04	3.06	2.30	1.104	1.276	15.6
8	Cortex	95	187	2.30	1.03	5.95	1.80			
	Tumor			1.43	1.01	3.69	1.44	0.619	0.798	28.9
9	Cortex	110	305	1.69	0.70	3.19	1.13			
	Tumor			2.05	1.08	3.87	2.46	1.213	1.546	27.5
10	Cortex	90	268	2.91	0.91	5.86	1.55			
	Tumor			ND	ND	ND	ND	ND	ND	
Mean ± s.d.	Cortex	106.8 ± 18.9	242.5 ± 43.4*	2.24 ± 0.70	0.91 ± 0.17†	4.41 ± 1.25	1.54 ± 0.46*			
	Tumor			1.84 ± 0.48	1.01 ± 0.28†	3.64 ± 0.91	1.81 ± 0.82†	0.889 ± 0.195	1.115 ± 0.227*	26.0 ± 5.71

\*p < 0.001, †p < 0.01 (compared with control study).

FU = fractional uptake (%); SUV = standardized uptake value; TCR = tumor-to-cortex ratio; Cont = control; Glu = glucose loading; ND = not detected.

brain tumors in FDG images possible. This phenomenon may facilitate superior tumor detectability in brain FDG PET studies.

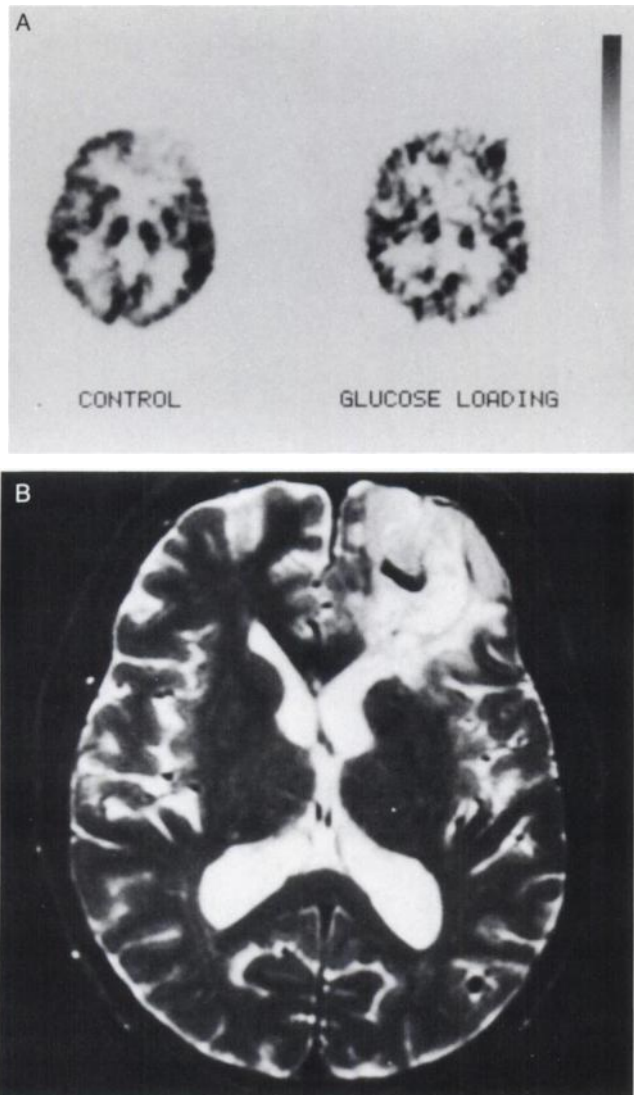
FDG metabolism seems to be easily affected by plasma



**FIGURE 3.** Fractional uptake of FDG in cortex and tumor in relation to the reciprocal of plasma glucose level (mean and standard deviation). In the cortex, FU of FDG changed in proportion to the reciprocal of plasma glucose level.

glucose concentration, but little is known about the effect of hyperglycemia on FDG metabolism in the human brain. It has been clearly shown that increased glucose levels in the serum diminish the uptake of <sup>11</sup>C-methylglucose in the healthy brain (18). This may be caused mainly by the competition of FDG and glucose at the membrane transport of the blood-brain barrier. Our results agreed with this hypothesis as fractional uptake of FDG in the brain decreased in all patients with glucose loading and was changed in proportion to the reciprocal of plasma glucose value in the cerebral cortex. On the other hand, fractional uptake of FDG showed less of a decrease by glucose loading in tumors and the edematous region than in the cortex, resulting in higher tumor-to-gray matter ratio.

In tumors and pathological areas, FDG kinetics, such as transport and phosphorylation, may differ in a variety of ways from those in normal tissues in both normoglycemia and hyperglycemia. In membrane transport, it has been reported that brain tumors have a different glucose transporter and increased ability of glucose transportation (19). There is evidence suggesting that amplified glucose transport capability may be one of the factors associated with the high glycolytic rate of neoplastic cells (20). Flier et al. demonstrated that the uptake of [<sup>3</sup>H]-2-deoxy-D-glucose was significantly increased in cultured rodent fibroblasts



**FIGURE 4.** (A) FDG PET images and (B) Gd-enhanced T1-weighted MR images of a patient with glioma (no. 4). In FDG PET studies, the tumor is visualized more clearly in the glucose loading study than in the control study.

transfected with ras or src oncogenes. The production of the transporter protein for glucose and the mRNA for this protein was also increased (21). In phosphorylation, tumor glucose metabolism may be increased by the difference of hexokinase activity. The competitive displacement of FDG by plasma glucose depends on the value of the Michaelis-Menten constant  $K_m$  of glucose transport and of hexokinase, respectively (22). Langen et al. explained a lower competition between FDG and plasma glucose in tumor by higher  $K_m$  of hexokinase (12,23). The lumped constant, which is the efficiency ratio of FDG to glucose in membrane transport and hexokinase metabolism, is reported to be different in brain tumor from normal brain (24–26).

In addition to the direct competitive process in hyperglycemia, decreased arterial input, increased serum insulin level and breakdown of the blood-brain barrier (BBB) might also have some effects on FDG uptake in brain

tumors. In animal studies, it has been shown that increased serum glucose levels reduced deoxyglucose uptake in normal brain more than that in transported mammary tumor, causing elevation of the tumor-to-normal brain ratio of FDG (27). However, the effect of serum glucose levels on glioma remains unclear.

In this study, we used FU to evaluate FDG accumulation in brain tissues. Calculation of the cerebral metabolic rate of glucose (CMRG) by Phelps and Huang's autoradiographic method (2,3) using arterial FDG input and a single static FDG scan cannot be applied in case of abnormal tissues, especially in hyperglycemic conditions. We calculated SUVs that have been proposed as a simple index of tissue and tumor accumulation of FDG, but the SUV may not be a suitable index for comparing FDG uptake under different plasma glucose concentrations. Hyperglycemia decreases arterial input of FDG due to faster blood clearance, and the same injected dose of FDG does not guarantee the same arterial input of FDG. Additionally, the SUV has been reported to be overestimated in heavier patients (28). On the other hand, FU represents the simple uptake value normalized by the arterial input of FDG and can neglect the influence of other organs FDG uptake and the patient's body weight.

Although glucose loading is a simple and safe procedure for nondiabetic patients, plasma glucose levels during the study should be monitored to avoid excess glucose-level elevation. None of our subjects presented in this article had diabetes mellitus. It has been reported that affinity of D-glucose carriers present in the BBB are within normal limits in treated insulin-dependent diabetic subjects, and insulin appears to have no effect on the transport of  $^{11}\text{C}$ -methylglucose across the BBB (29). Therefore, the hyperglycemic condition is also expected to show the same effect on FDG PET studies in diabetic patients.

Since hyperglycemia suppresses FDG uptake in normal brain tissue, the signal-to-noise ratio of the images slightly decreases due to the lower counts, as shown in our study. Although there was no significant diagnostic disadvantage in this study, longer scan time or larger amounts of injected dose than our routine protocol might improve image quality.

Carbon-11-methionine PET study also has high potential for brain tumor diagnosis (30,31). However, it always requires a cyclotron for its production, and the number of the studies is limited due to its short half-life. On the other hand, single production of FDG allows multiple patient studies. Moreover, FDG PET studies can be performed without a cyclotron if FDG is delivered from the core cyclotron center, which will enhance the future capability of clinical PET (32).

FDG PET studies with glucose loading are expected to increase sensitivity to detect recurrent or residual brain tumors after surgical treatment and/or radiation therapy. To confirm this expectation, further studies should be performed with a larger number of subjects with gliomas and other brain tumors, as well as metastatic tumors. It is also



necessary to determine the optimum plasma glucose level to obtain the maximum tumor-to-cortex ratio.

In conclusion, these results demonstrate the different effects of hyperglycemia on normal brain and brain tumors, demonstrating that glucose loading may be a valuable adjunct to FDG PET studies to enhance detection of recurrent or residual brain tumors.

## REFERENCES

1. Reivich M, Kuhl DE, Wolf A, et al. The [ $^{18}\text{F}$ ]fluorodeoxyglucose method for the measurement of local cerebral glucose utilization in man. *Circ Res* 1979;44:127-137.
2. Phelps ME, Huang S-C, Hoffman EJ, Selin C, Sokoloff L, Kuhl DE. Tomographic measurement of local cerebral glucose metabolic rate in humans with [ $^{18}\text{F}$ ]2-fluoro-deoxy-D-glucose: validation of method. *Ann Neurol* 1979;6:371-388.
3. Huang S-C, Phelps ME, Hoffman EJ, Sideris K, Selin CJ, Kuhl DE. Non-invasive determination of local cerebral metabolic rate of glucose in man. *Am J Physiol* 1980;238:E69-E82.
4. Tyler JL, Diksic M, Villemure J-G, et al. Metabolic and hemodynamic evaluation of gliomas using positron emission tomography. *J Nucl Med* 1987;28:1123-1133.
5. Di Chiro G, DeLaPaz RL, Brooks RA, et al. Glucose utilization of cerebral gliomas measured by [ $^{18}\text{F}$ ] fluorodeoxyglucose and positron emission tomography. *Neurology* 1982;32:1323-1329.
6. Di Chiro G. Positron emission tomography using [ $^{18}\text{F}$ ] fluorodeoxyglucose in brain tumors. A powerful diagnostic and prognostic tool. *Invest Radiol* 1987;22:360-371.
7. Alavi JB, Alavi A, Chawluk J, et al. Positron emission tomography in patients with glioma. *Cancer* 1988;62:1074-1078.
8. Patronas NJ, Di Chiro G, Kufta C, et al. Prediction of survival in glioma patients by means of positron emission tomography. *J Neurosurg* 1985;62:816-822.
9. Doyle WK, Budinger TF, Valk PE, et al. Differentiation of cerebral radiation necrosis from tumor recurrence by [ $^{18}\text{F}$ ] FDG and  $^{82}\text{Rb}$  positron emission tomography. *J Comput Assist Tomogr* 1987;11:563-570.
10. Patronas NJ, Di Chiro G, Brooks RA, et al. Work in progress: [ $^{18}\text{F}$ ] fluorodeoxyglucose and positron emission tomography in the evaluation of radiation necrosis of the brain. *Radiology* 1982;144:885-889.
11. Lindholm P, Minn H, Leskinen-Kallio S, Bergman J, Ruotsalainen U, Joensuu H. Influence of the blood glucose concentration on FDG uptake in cancer: a PET study. *J Nucl Med* 1993;34:1-6.
12. Langen KJ, Braun U, Kops ER. The influence of plasma glucose levels on fluorine-18-fluorodeoxyglucose uptake in bronchial carcinomas. *J Nucl Med* 1993;34:355-359.
13. Mukai T, Senda M, Yonekura Y, et al. System design and performance of a newly developed high resolution PET scanner using double wobbling mode [Abstract]. *J Nucl Med* 1988;5:877.
14. Tamaki N, Yonekura Y, Kawamoto M, et al. Simple quantification of regional myocardial uptake of fluorine-18-deoxyglucose in the fasting condition. *J Nucl Med* 1991;32:2152-2157.
15. Camici P, Araujo LI, Spinks T, et al. Increased uptake of  $^{18}\text{F}$ -fluorodeoxyglucose in postischemic myocardium of patients with exercise-induced angina. *Circulation* 1986;74:81-88.
16. Fray KA, Agranoff BW. Barbiturate-enhanced detection of brain lesions by carbon-14-labeled 2-deoxyglucose autoradiography. *Science* 1983;219:879-881.
17. Blacklock JB, Oldfield EH, Di Chiro G, et al. Effect of barbiturate coma on glucose utilization in normal brain versus gliomas. *J Neurosurg* 1987;67:71-75.
18. Brooks DJ, Beaney RP, Lammertsma AA, et al. Glucose transport across the blood-brain barrier in normal human subjects and patients with cerebral tumors studied using [ $^{11}\text{C}$ ]3-o-methyl-D-glucose and positron emission tomography. *J Cereb Blood Flow Metab* 1986;6:230-239.
19. Guerin C, Laterra J, Hruban RH, et al. The glucose transporter and blood-brain barrier of human brain tumors. *Ann Neurol* 1990;28:758-765.
20. Hawkins RA, Choi Y, Huang S-C, Messa C, Hoh CK, Phelps ME. Quantitating tumor glucose metabolism with FDG and PET [Editorial]. *J Nucl Med* 1992;3:339-344.
21. Flier JS, Mueckler MM, Usher P, Lodish HF. Elevated levels of glucose transport and transporter messenger RNA are induced by ras or src oncogenes. *Science* 1987;235:1492-1495.
22. Sokoloff L, Reivich M, Kennedy Y, et al. The [ $^{14}\text{C}$ ]deoxyglucose method for the measurement of local cerebral glucose utilization: therapy, procedure, and normal values in the conscious and anesthetized albino rat. *J Neurochem* 1977;28:897-916.
23. Bennet MJ, Timperley WR, Taylor CB, Hill SA. Isozymes of hexokinase in the developing, normal and neoplastic human brain. *Eur J Cancer* 1978;14:189-193.
24. Kapoor R, Spence AM, Muzi M, et al. Determination of the deoxyglucose and glucose phosphorylation ratio and the lumped constant in rat brain and a transplantable rat glioma. *J Neurochem* 1989;53:37-44.
25. Graham JF, Cummins CJ, Smith BH, et al. Regulation of hexokinase in cultured gliomas. *Neurosurgery* 1985;17:537-542.
26. Spence AM, Graham MM, Muzi M, et al. Deoxyglucose lumped constant estimated in a transported rat astrocytic glioma by the hexose utilization index. *J Cereb Blood Flow Metab* 1990;10:190-198.
27. Wahl RL, Henry CA, Ethier SP. Serum Glucose: effects on tumor and normal tissue accumulation of 2-[ $^{18}\text{F}$ ]fluoro-2-deoxy-D-glucose in rodents with mammary carcinoma. *Radiology* 1992;183:643-647.
28. Kenneth RZ, Richard LW. Standardized uptake values of normal tissues at PET with 2-[fluorine-18]-fluoro-2-deoxy-D-glucose: variations with body weight and a method for correction. *Radiology* 1993;189:847-850.
29. Derlon J-M, Bourdet C, Bustany P, et al. [ $^{11}\text{C}$ ]L-methionine uptake in gliomas. *Neurosurgery* 1989;25:720-728.
30. Brooks DJ, Gibbs JSR, Sharp P, et al. Regional cerebral glucose transport in insulin-dependent diabetic patients studied using [ $^{11}\text{C}$ ]3-O-methyl-D-glucose and positron emission tomography. *J Cereb Blood Flow Metab* 1986;6:240-244.
31. Bergstrom M, Ericson K, Hagenfeldt L, et al. PET study of methionine accumulation in gliomas and normal brain tissue; competition with branched chain amino acids. *J Comput Assist Tomogr* 1987;11:208-213.
32. Wagner HN. Oncology: a new engine for PET/SPECT. *J Nucl Med* 1993;34:13N-29N.