

Myocardial Perfusion Imaging with PET

Markus Schwaiger

Nuklearmedizinische Klinik und Poliklinik, Der Technischen Universität München, Klinikum Rechts der Isar, Munich, Germany

Although SPECT has become an accepted imaging technique for myocardial perfusion studies, there are several advantages to evaluating coronary artery disease (CAD) with PET. CAD is a complex, dynamic disease and quantitative measurements of myocardial blood flow by PET can improve the functional characterization of CAD. The major advantage of PET over SPECT is its ability to provide attenuation-corrected images, which decreases incidence of attenuation artifacts and increases specificity. Myocardial perfusion imaging with PET can also provide more accurate information on localization of disease, as well as quantitative assessment, in absolute values, of myocardial blood flow. The measurement of regional flow reserve allows for physiologic characterization of stenosis severity, and may provide early detection of CAD as well as prognostic information. The disadvantage of PET, compared to SPECT, is that the equipment and operations are more expensive. As more accurate diagnostic and prognostic data lead to improved patient management, the cost-to-benefit ratios of PET and SPECT in the clinical setting need to be further analyzed to determine which diagnostic test is most efficient in the work-up of patients with suspected or known CAD.

Key Words: myocardial perfusion imaging; coronary artery disease; SPECT; PET

J Nucl Med 1994; 35:693-698

It is well established that tomographic myocardial perfusion images provide higher spatial resolution than planar images for evaluating patients with coronary artery disease (CAD) (1,2). SPECT is used routinely in the clinical setting. There are three commercially available radiotracers for myocardial perfusion SPECT which have been employed successfully for the detection and localization of CAD (1-4): ^{201}Tl , $^{99\text{m}}\text{Tc}$ -sestamibi and $^{99\text{m}}\text{Tc}$ -teboroxime.

PET VERSUS SPECT

In comparison to SPECT, PET can detect radiotracer activity with 10 times the sensitivity of state-of-the-art

SPECT (5). PET spatial resolution is superior to that of SPECT, resulting in superior image quality and less partial volume effect (5). Most PET images are processed with a spatial resolution of about 6-10 mm, as compared with 10-15 mm for SPECT image reconstruction.

The major advantage of PET is its ability to correct for attenuation. Traditional myocardial perfusion imaging with single-photon radiotracers such as ^{201}Tl poses significant challenges in avoiding or identifying and correcting for attenuation artifacts, particularly those that involve the inferior wall in male patients and the anterior wall in female patients (6,7).

Unquestionably, attenuation correction provides more homogeneous radiotracer distribution in normal myocardium, and improved characterization of relative differences in regional perfusion (8). In addition, attenuation correction improves the accuracy of quantitative analysis of defect severity since variation within normal segments is reduced (8). Thus, PET can provide reliable, quantitative assessment of myocardial radiotracer distribution; whereas SPECT, without attenuation correction, provides a more variable reflection of regional myocardial radiotracer distribution. Such improvement in image quality is expected to result in enhanced diagnostic performance.

Validation

As new medical technology is introduced, several issues must be addressed.

One challenge is to validate a new diagnostic technology with established tests that are accepted as gold standards. If, for example, coronary angiography is used to confirm results of myocardial perfusion studies with PET, referral bias becomes a problem because only patients with abnormal myocardial perfusion scans are referred for cardiac catheterization (9). The selected study population, therefore, may not represent the general patient population that is referred for myocardial perfusion studies.

Secondly, it is important to consider which diagnostic accuracy is necessary to affect patient management decisions. Clinical experience shows, for example, that a normal ^{201}Tl study, even in the presence of CAD, is associated with a very good prognosis (10-12). Therefore, the sensitivity of ^{201}Tl SPECT for detection of CAD may be adequate. However, the specificity of ^{201}Tl studies is not sufficiently high, resulting in a reported false-positive rate ranging from 20% to 50% (13-15). As a consequence, pa-

Received Jan. 7, 1994; revision accepted Jan. 18, 1994.

This paper was presented in part at the Annual Meeting of the Society of Nuclear Medicine on June 8, 1993 as part of a Continuing Medical Education Seminar organized by the Cardiovascular Council.

For correspondence or reprints contact: Prof. Dr. Markus Schwaiger, Nuklearmedizinische Klinik und Poliklinik, Der Technischen Universität München, Klinikum Rechts der Isar, Ismaninger Strasse 22, 8000 München 80, Germany.

tient care may not suffer, but unnecessary additional diagnostic procedures will be performed, affecting the cost of patient care.

Thirdly, as diagnostic imaging technology advances, it provides new approaches to more sophisticated diagnostic challenges. Although the presence of CAD can be detected adequately with a variety of diagnostic tests, other questions—such as the exact location of stenoses and their hemodynamic significance—require more advanced quantitative measurements of regional blood flow. Over recent years, internists and cardiologists have become more aggressive in treating CAD and more demanding of documented outcomes. The need for noninvasive techniques to monitor therapy is well appreciated. Quantitative measurements of regional flow reserve, which PET can provide, may be able to monitor the progression or regression of CAD and, thus, allow for guided therapy in patients with a high risk for accelerated atherosclerotic disease processes in primary and secondary prevention (16).

PET MYOCARDIAL PERFUSION TRACERS

There are several positron-emitting radiotracers useful for myocardial perfusion imaging.

Rubidium-82

Rubidium-82 is a convenient radiotracer because it can be produced by a radionuclide generator system (17). Any nuclear cardiac imaging facility with PET, therefore, can provide ^{82}Rb studies without the need for an on-site cyclotron. With a half-life of 76 sec, ^{82}Rb allows for repeated blood flow measurements in short time intervals. The relation between ^{82}Rb uptake and blood flow is nonlinear with decreasing myocardial extraction at higher flow rates, however, the practicality of the radiotracer offsets this physiologic limitation. Several studies have shown that ^{82}Rb , in combination with pharmacologic stress, allows accurate detection of CAD (18–21).

Nitrogen-13-Ammonia

Nitrogen-13-ammonia is cyclotron-produced. Its half-life of 10 min requires a 30- to 40-min waiting period before the rest and second stress injection (21). With respect to the relation between blood flow and radiotracer uptake, ^{13}N -ammonia behaves similarly to ^{201}Tl in that its uptake is less affected by high flow rates as compared with ^{82}Rb . This radiotracer excels by the excellent image quality and convenient use in a clinical setting (8).

Oxygen-15-Water

Oxygen-15-water is used primarily in the research environment (22,23). Theoretically, this radiotracer is ideal for quantitative flow measurements by PET for two reasons: it diffuses freely across the myocyte membranes, and the tissue retention of ^{15}O -water uptake is not affected by metabolic factors. However, the technical requirements of ^{15}O -water studies limit its clinical application. This technique involves dynamic imaging procedures and subtraction methods for removal of blood tracer activity (22).

Copper-62-PTSM

Copper-62-pyruvaldehyde bis(n-methylthio-semicarbazono) (PTSM) is currently being validated as an alternative to ^{82}Rb for myocardial perfusion imaging (24). As with ^{82}Rb , the relation between ^{62}Cu -PTSM and blood flow is nonlinear and may therefore lead to an underestimation of coronary flow reserve estimates. Direct comparison of ^{82}Rb and ^{62}Cu -PTSM studies are necessary to define the future clinical role of this new radiotracer.

IMAGE QUALITY

Excellent PET image quality is obtainable with ^{82}Rb , ^{13}N -ammonia and ^{62}Cu -PTSM, with a high contrast between myocardium and underlying lung tissue or blood pool (24,25). Because ^{82}Rb emits a high-energy positron that travels a longer distance before colliding with an electron to produce two gamma photons, ^{82}Rb PET images have a lower intrinsic resolution. Figure 1 shows images and polar maps representing the normal distribution of all three tracers (13).

PET images with ^{82}Rb demonstrate homogeneous distribution, reflecting the effect of attenuation correction; ^{13}N -ammonia distribution is slightly nonhomogeneous, with reduced radiotracer activity in the lateral wall (Fig. 1); and ^{62}Cu -PTSM maps demonstrate some scatter in the inferior wall, resulting from its high liver uptake. The low uptake of ^{13}N -ammonia in the lateral wall is a reproducible finding in both rest and stress images. Although the mechanism is unknown, it appears to be a regional metabolic alteration in ^{13}N -ammonia tissue retention (26).

PROTOCOLS

As a rule, PET studies are obtained with short scanning times. A typical myocardial perfusion study with ^{82}Rb can be completed in 1 hr. After injection of ^{82}Rb , the protocol entails: a 15-min transmission scan, a 5-min rest flow study, injection of a pharmacologic stress agent, a second dose of ^{82}Rb and a 5-min stress study acquisition (17). Similar protocols are followed for myocardial perfusion PET imaging with ^{13}N -ammonia, which requires a waiting period for ^{13}N decay, but can be completed within 1.5 to 2.0 hr (8). The short completion times of these PET protocols offer a distinct advantage over myocardial perfusion studies with ^{201}Tl or $^{99\text{m}}\text{Tc}$ -sestamibi.

DIAGNOSTIC ACCURACY

Myocardial perfusion studies with PET have been shown to provide a higher diagnostic accuracy than those with SPECT (Table 1) (18–22,27,28). The reported sensitivities of PET for CAD detection are in the range of 80%–95%; whereas reported specificity values of PET are 80%–95%. Although there are only two studies comparing PET and SPECT in the same patient populations, and although these studies have been criticized for referral bias, the results consistently find that PET provides about

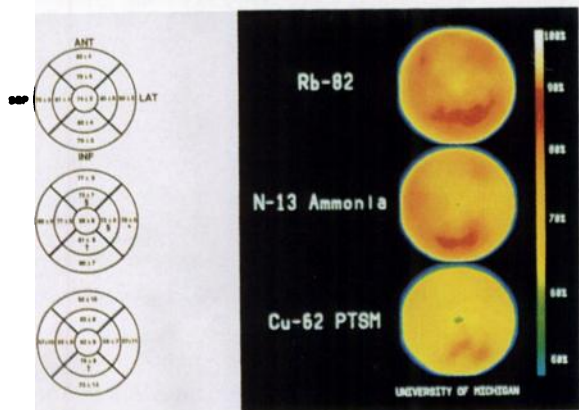
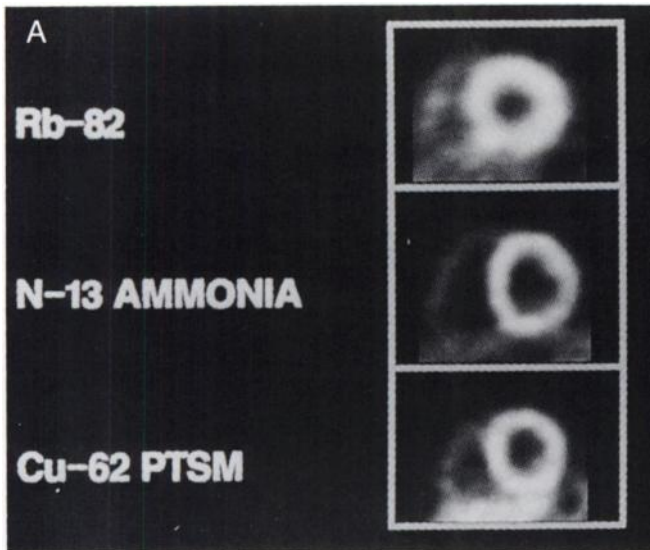


FIGURE 1. PET images of myocardial blood flow, mid-ventricular short-axis plane (A), and polar maps of radiotracer distribution (B) with ^{82}Rb , ^{13}N -ammonia and ^{62}Cu -PTSM. Reprinted with permission from C.V. Mosby, St. Louis, MO (*American Heart Journal* 1989; 13:600-612).

10% higher diagnostic accuracy than SPECT for detection of CAD (19,20).

More data are needed to define the diagnostic differences in large patient populations, and to calculate the cost-to-benefit ratios of various clinical situations to deter-

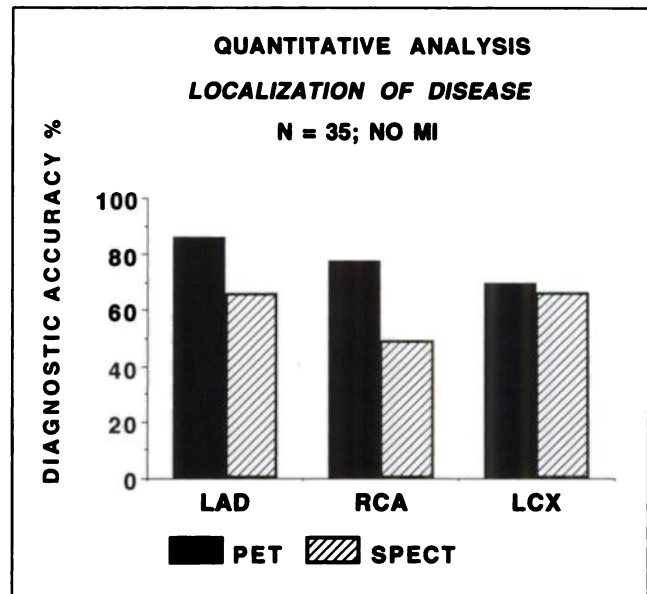


FIGURE 2. Diagnostic accuracy in detection of regional CAD by quantitative evaluation of ^{201}Tl SPECT and ^{82}Rb PET in patients without prior MI. Reprinted with permission from Reference 29.

mine when PET should replace SPECT for myocardial perfusion studies in patients with suspected CAD.

Localization of Disease

The quantitative assessment of PET radiotracer distribution can provide a significant advantage over SPECT in cases where attenuation artifacts pose limitations in the localization of disease (8). Automated programs can objectively determine the extent and severity of perfusion defects by comparison with normal databases with sensitivities and specificities of approximately 85% and 80%, respectively, for both 50% and 75% stenoses (28).

A study of 35 patients who underwent both ^{201}Tl SPECT and ^{82}Rb PET perfusion studies demonstrated a diagnostic gain in accurate localization of regional disease with the ^{82}Rb studies. Quantitative analysis was performed for both the ^{201}Tl studies and ^{82}Rb studies (Fig. 2) (29).

In another study of 34 patients without previous myocardial infarction (MI), ^{13}N -ammonia PET provided high

TABLE 1
Diagnostic Performance of PET vs. SPECT in Detection of CAD

Author	Stress	Tracer	PET				SPECT			
			N	Sen (%)	Spec (%)	Acc (%)	N	Sen (%)	Spec (%)	Acc (%)
Schelbert et al. (22)	Dipyridamole	$^{13}\text{NH}_3$	35	97	100	98	—	—	—	—
Demer et al. (18)	Dipyridamole	$^{13}\text{NH}_3, ^{82}\text{Rb}$	193	82	95	88	—	—	—	—
Stewart et al. (19)	Dipyridamole	^{82}Rb	81	85	84	85	81	84	53	79
Go et al. (20)	Dipyridamole	^{82}Rb	135	95	82	92	135	79	76	78
Tamaki et al. (27)	Exercise*	$^{13}\text{NH}_3$	48	98	—	—	48	96	—	—
Total			492	91	90	92	264	86	65	78

*Bicycle ergometer.

Sen = sensitivity; Spec = specificity; Acc = accuracy; NH_3 = ammonia.

**ROC Analysis
N-13 Ammonia PET
Localization of Disease
N=34**

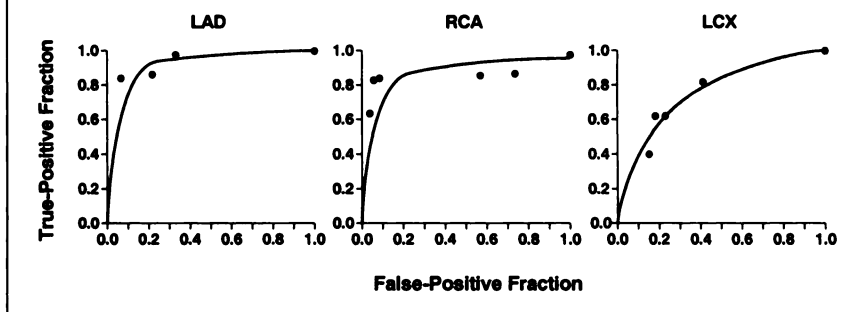


FIGURE 3. ROC curves for detection and localization of CAD using quantitative evaluation of ¹³N-ammonia PET images in patients without prior MI. Reprinted with permission from Reference 28.

sensitivity and specificity in localizing disease in the left anterior descending (LAD) artery and the right coronary artery (RCA) (Fig. 3) (28). PET was somewhat less successful in localizing disease of the circumflex artery.

Quantification of Blood Flow

PET quantification of myocardial blood flow is more difficult than diagnosis and localization of CAD because of the technical requirements of data acquisition; it is necessary to process dynamic data acquisition, which is sensitive to patient motion. A kinetic model of radiotracer biodistribution, validated in animal models, as well as sophisticated computer processing, are necessary to translate scintigraphic information into absolute blood flow measurements. However, several approaches have been shown to provide reproducible blood flow measurements in ml/min/100 g of left ventricular tissue Table 2 (24,30–33).

In a study of healthy volunteers, quantitative regional data presented in polar maps demonstrated that resting blood flow averaged 70 cc/min/100 g, with little variation within the left ventricular myocardium (8). After pharmacologic stress, blood flow increased four to five times, which correlated with the expected coronary flow reserve in normal myocardial tissue.

Are these PET blood flow measurements clinically useful? In a study that compared blood flow estimates with quantitative angiography, results showed that a high degree of stenosis (70%–90%) correlated with a very high

incidence of abnormal coronary reserve (34). On the other hand, a more moderate degree of stenosis (50%–70%) was associated with considerable scatter of coronary reserve values, suggesting complementary information provided by functional characterization with PET.

The surprising observation, however, was that patients with angiographically normal myocardial regions, especially in the presence of coronary stenosis in remote vessels, had significantly reduced coronary reserve. This finding indicates that normal angiographic results in patients with CAD are not always associated with functionally normal vasculature.

Based on these results, we investigated whether quantitative assessment of blood flow reserve can identify early atherosclerosis in asymptomatic subjects at high risk for CAD. A study compared age-matched male patients with a strong family history of premature CAD with a second group of asymptomatic male subjects without risk factors for CAD (35). The results showed that coronary flow reserve was significantly low in the patients with high risk. The degree of impaired flow reserve correlated with the severity of lipid abnormality. These data suggest a potential application of quantitative PET blood flow measurements in the early detection of CAD in high-risk populations. Furthermore, the monitoring of flow reserve may serve as a useful endpoint in the assessment of therapy designed to prevent the progression of CAD.

TABLE 2
Myocardial Blood-Flow Estimates in Humans Determined by PET

Author	Tracer	Rest flow (ml/100 g/min)	Stress flow (ml/100 g/min)	Exercise/Rest	Type of stress
Bergmann et al. (24)	¹⁵ O-water	90 ± 22	355 ± 112	3.94	Dipyridamole
Hutchins et al. (31)	¹³ N-ammonia	88 ± 17	417 ± 112	4.74	Dipyridamole
Krivokapich et al. (33)	¹³ N-ammonia	70 ± 17	132 ± 22	1.97	Exercise*
Czernin et al. (32)	¹³ N-ammonia	76 ± 17	300 ± 80	3.00	Dipyridamole

*Bicycle ergometer.

Assessment of Endothelial Function

Cold-pressor testing is considered a specific test for endothelial function of coronary arteries. We have recently explored the feasibility of myocardial perfusion imaging in combination with cold-pressor testing (36). During PET scanning, the patient's foot is immersed in ice-cold water; coronary blood flow is measured before and during this stress procedure. Results showed that all patients with angiographically normal CAD had increased myocardial blood flow in response to the cold-pressor test, whereas patients with minimal CAD had a wide range of responses; in contrast, patients with severe CAD demonstrated a decrease of blood flow. These preliminary results suggest that an abnormal response to cold-pressor testing may identify endothelial dysfunction associated with early CAD, and may provide a noninvasive technique (with PET imaging) to define endothelial pathology.

From these data, hypotheses on prognostic indicators from quantitative myocardial perfusion PET in patients with CAD can be derived and subsequently tested in prospective studies.

CONCLUSION

Several positron-emitting radiotracers are useful for myocardial perfusion PET, including ^{82}Rb and ^{13}N -ammonia. The use of ^{62}Cu -PTSM is still being validated and ^{15}O -water is mainly used in the research environment. PET technology can provide improved diagnostic accuracy, compared with SPECT, in evaluating patients with known or suspected CAD. The major advantage of PET over SPECT is its ability to provide attenuation-corrected images, which increases the specificity (decreasing the false-positive rate) of the diagnostic test. As improved methods of attenuation correction for SPECT—such as transmission/emission acquisition—progress, SPECT will become more competitive with PET for myocardial perfusion imaging. The cost-to-benefit ratios of using myocardial perfusion PET in the clinical setting are as yet undefined.

In addition to diagnostic evaluation of CAD, myocardial perfusion imaging with PET can provide quantitative assessment of myocardial blood flow. The quantitative assessment of regional flow reserve allows for physiologic characterization of CAD, which may enhance the understanding of CAD and provide additional prognostic information.

ACKNOWLEDGMENTS

Financial support for this work was provided by NIH grants ROI HL41047 and ROI HL4743. The work was performed under the tenure of an established investigatorship by the AMA.

REFERENCES

- Maddahi J, KVT, Prigent F, et al. Quantitative single photon emission computed thallium-201 tomography for detection and localization of coronary artery disease: optimization and prospective validation of a new technique. *J Am Coll Cardiol* 1989;14:1689–1699.
- Fintel DJ, Links JM, Brinker JA, Frank TL, Parker M, Becker LC. Improved diagnostic performance of exercise thallium-201 single photon emission computed tomography over planar imaging in the diagnosis of coronary artery disease: a receiver operating characteristic analysis. *J Am Coll Cardiol* 1989;13:600–612.
- Kiat H, Maddahi J, Roy LT, et al. Comparison of technetium 99m methoxy isobutyl isonitrile and thallium-201 for evaluation of coronary artery disease by planar and tomographic methods. *Am Heart J* 1989;117:1–11.
- Seldin DW, Johnson LL, Blood DK, et al. Myocardial perfusion imaging with technetium-99m SQ30217: comparison with thallium-201 and coronary anatomy. *J Nucl Med* 1989;30:312–319.
- Koeppe RA, Hutchins GD. Instrumentation for positron emission tomography: tomographs and data processing and display systems. *Semin Nucl Med* 1992;22:162–181.
- Friedman J, Van Train K, Maddhi J, et al. “Upward creep” of the heart: a frequent source of false positive reversible defects during thallium-201 stress-redistribution tomographic myocardial scintigraphy. *J Nucl Med* 1989;30:1718–1722.
- Eisner RI, Tamas MJ, Cloninger K, et al. Normal SPECT thallium-201 bulls-eye display: gender differences. *J Nucl Med* 1988;29:1901–1909.
- Schwaiger M, Muzik O. Assessment of myocardial perfusion by positron emission tomography. *Am J Cardiol* 1991;67:35D–43D.
- Rozanski A. Referral bias and the efficacy of radionuclide stress tests: problems and solutions. *J Nucl Med* 1992;33:2074–2078.
- Wackers FJT, Russo DJ, Russo D, Clements JP. Prognostic significance of normal quantitative planar thallium-201 stress scintigraphy in patients with chest pain. *J Am Coll Cardiol* 1985;6:27–30.
- Pamelia FX, Gibson RS, Watson DD, Craddock GB, Sirowatka J, Beller GA. Prognosis with chest pain and normal thallium-201 exercise scintigrams. *Am J Cardiol* 1992;55:920–926.
- Wahl JM, Hakki A-H, Iskandrian AS. Prognostic implications of normal exercise thallium-201 images. *Arch Intern Med* 1985;145:253–256.
- Allman K, Berry J, Sucharski L. How well does adenosine thallium scintigraphy characterize extent and location of coronary artery disease? *J Am Coll Cardiol* 1992;19:311.
- Schwartz RS, Jackson WG, Celio PV, Hickman JR. Exercise thallium-201 scintigraphy for detecting coronary artery disease in asymptomatic young men. *J Am Coll Cardiol* 1988;11:80A.
- Gould KL, Goldstein RA, Mullani NA, et al. Noninvasive assessment of coronary stenoses by myocardial perfusion imaging during pharmacologic coronary vasodilation. VIII. clinical feasibility of positron cardiac imaging without a cyclotron using generator-produced rubidium-82. *J Am Coll Cardiol* 1986;7:775–789.
- Ornish DM, Scherwitz IW, Brown SE, et al. Can lifestyle changes reverse atherosclerosis? *Circulation* 1988;78:II-11.
- Gould KL. How accurate is thallium exercise testing? *J Am Coll Cardiol* 1989;14:1487–1490.
- Demer L, Gould K, Goldstein R, et al. Assessment of coronary artery disease severity by positron emission tomography: comparison with quantitative arteriography in 193 patients. *Circulation* 1989;79:825–835.
- Stewart R, Schwaiger M, Molina E, et al. Comparison of rubidium-82 positron emission tomography and thallium-201 SPECT imaging for detection of coronary artery disease. *Am J Cardiol* 1991;67:1303–1310.
- Go RT, Marwick TH, McIntyre WJ, et al. A prospective comparison of rubidium-82 PET and thallium-201 SPECT myocardial perfusion imaging utilizing a single dipyridamole stress in the diagnosis of coronary artery disease. *J Nucl Med* 1990;31:1899–1905.
- Williams B, Jansen D, Wong L, et al. Positron emission tomography for the diagnosis of coronary artery disease: a non-university experience and correlation with coronary angiography [Abstract]. *J Nucl Med* 1989;30:845.
- Schelbert HR, Wisenberg G, Phelps ME, et al. Noninvasive assessment of coronary stenoses by myocardial imaging during pharmacologic coronary vasodilation. VI. Detection of coronary artery disease in man with intravenous N-13 ammonia and positron computed tomography. *Am J Cardiol* 1982;49:1197–1207.
- Walsh MN, Bergmann SR, Steele RL, et al. Delineation of impaired regional myocardial perfusion by positron emission tomography with H_2^{15}O . *Circulation* 1988;78:612–620.
- Bergmann SR, Herrero P, Markham J, Weinheimer CJ, Walsh MN. Noninvasive quantitation of myocardial blood flow in human subjects with oxygen-15-labeled water and positron emission tomography. *J Am Coll Cardiol* 1989;14:639–652.
- Beanlands R, Muzik O, Mintun M, et al. The kinetics of copper-62-PTSM in the normal human heart. *J Nucl Med* 1992;33:684–690.
- Hutchins GD, Beanlands RSB, Muzik O, Schwaiger M. Quantitative vs. semi-quantitative PET myocardial blood flow: influence of regional ammonia kinetics. *Circulation* 1992;86:1-710.

27. Tamaki N, Yonekura Y, Yamashita K, et al. Value of rest-stress myocardial positron tomography using nitrogen-13 ammonia for the preoperative prediction of reversible asynergy. *J Nucl Med* 1989;30:1302-1310.
28. Laubenbacher C, Rothley J, Sitomer J, et al. An automated analysis program for the evaluation of cardiac PET studies: initial results in the detection and localization of coronary artery disease using nitrogen-13 ammonia. *J Nucl Med* 1993;34:968-978.
29. Allmann CJ, Rothley JM, Yang S, et al. Quantitative analysis of Rb-82 PET images: intra- and interobserver variability [Abstract]. *J Nucl Med Technol* 1992;20:101.
30. Iida H, Kanno I, Takahashi A, et al. Measurement of absolute myocardial blood flow with H₂¹⁵O and dynamic positron emission tomography: strategy for quantification in relation to the partial-volume effect. *Circulation* 1988;78:104-115.
31. Hutchins GD, Schwaiger M, Rosenspire KC, Krivokapich J, Schelbert H, Kuhl DE. Noninvasive quantification of regional blood flow in the human heart using N-13-ammonia and dynamic positron emission tomographic imaging. *J Am Coll Cardiol* 1990;15:1032-1042.
32. Czernin J, Müller P, Chan S, et al. Influence of age and hemodynamics on myocardial blood flow and flow reserve. *Circulation* 1993;88:62-69.
33. Krivokapich J, Stevenson LW, Kobashigawa J, et al. Quantification of absolute myocardial perfusion at rest and during exercise with positron emission tomography after human cardiac transplantation. *J Am Coll Cardiol* 1991;18:512-517.
34. Beanlands RSB, Melon PG, Muzik O, et al. N-13 ammonia PET identifies reduced perfusion reserve in angiographically normal regions of patients with CAD. *Circulation* 1992;86:1-184.
35. Dayanikli F, Grambow D, Muzik O, Mosca L, Rubenfire M, Schwaiger M. Evaluation of coronary flow reserve in asymptomatic males with hyperlipidemia and family history of coronary artery disease (CAD) [Abstract]. *J Nucl Med* 1993;34:115.
36. Grambow D, Dayanikli F, Muzik O, et al. Assessment of endothelial function with PET cold pressor test in patients with various degrees of coronary atherosclerosis [Abstract]. *J Nucl Med* 1993;34:36P.
37. Schwaiger M, Hutchins GD. Evaluation of coronary artery disease with positron emission tomography. *Semin Nucl Med* 1992;12:210-223.