
Technetium-99m-Tetrofosmin Myocardial Imaging: A Comparison with Thallium-201 and Angiography

Pierre Rigo, Brigitte Leclercq, Roland Itti, Avijit Lahiri and Simon Braat

Division of Nuclear Medicine, Department of Medicine, University of Liege, Belgium; Neuro-Cardiological Hospital, Lyon, France; Northwick Park Hospital, Harrow, U.K.; and Department of Cardiology, Academic Hospital Maastricht, University of Limburg, The Netherlands

Images recorded after intravenous administration of ^{99m}Tc -tetrofosmin were compared to those obtained with ^{201}Tl in a series of 40 patients with angiographically documented coronary artery disease. These patients were part of a Phase II tetrofosmin study and presented anamnestic or laboratory evidence suggestive of ischemic heart disease. **Methods:** Thirty-seven patients had one or more coronary obstructions greater or equal to 70% of luminal diameter. Three patients studied after bypass surgery or angioplasty had patent grafts, absence of disease progression or no significant restenosis. Twenty-six patients had evidence of previous myocardial infarction. All images were processed into a common display format by a core laboratory. They were identified by code and read by consensus of four investigators. Each segment was classified as normal or abnormal and these readings were combined and categorized into normal, reversible, fixed or mixed regional defects. **Results:** There was good segmental correspondence between thallium and tetrofosmin (κ -pa values ranged from 0.43 to 1.00). The ability of thallium and tetrofosmin to recognize and localize myocardial infarction was excellent, since corresponding abnormalities were present in respectively 24 and 25 of the 26 patients with previous myocardial infarction. Abnormalities in noninfarcted territories were recognized with both tracers in 16 of 28 patients presenting with coronary lesions involving vessels unrelated to the infarct. **Conclusion:** In comparison to rest tetrofosmin, thallium redistribution shows more reversibility in areas with myocardial infarction but less reversibility in areas of myocardial ischemia. Current Phase II results suggest that tetrofosmin is a sensitive and reliable tracer for detecting myocardial infarction and ischemia. Results should be confirmed in a larger group of patients.

Key Words: myocardial perfusion imaging; coronary angiography; thallium-201; technetium-99m-tetrofosmin

J Nucl Med 1994; 35:587-593

Myo-cardial scintigraphy is increasingly used to assess patients with known or suspected coronary artery disease

Received Jul. 8, 1993; revision accepted Dec. 10, 1993.
For correspondence and reprints contact: Pierre Rigo, MD, Nuclear Medicine Division, C.H.U. Sart Tilman, B.35, 4000 Liege 1, Belgium.

(CAD) (1). Indeed, this technique, primarily developed using ^{201}Tl , has been shown to be useful for diagnosing perfusion defects indicative of exercise-induced myocardial ischemia and evaluating the site and extent of postinfarct myocardial scar (2). This information is essential not only for diagnosing CAD but also for assessing prognosis and planning therapy in conjunction with data on global and regional cardiac function (3-5).

Thallium chloride, however, has less than ideal physical properties because its relatively long half-life limits the administered dose and its low photopeak energy limits resolution (6). Thallium therefore has less than optimal characteristics for tomographic myocardial imaging and cannot be utilized to assess myocardial function using either the first-pass or gated imaging approach.

Technetium-labeled radiopharmaceuticals, on the other hand, offer significant physical advantages over thallium, including more suitable and abundant photons for imaging, thus reducing the radiation dose to the patient (7). Several technetium-labeled agents have been introduced or are at various stages of development (8).

A drug formulation (Myoview™, Amersham International Plc) yielding a preparation containing the lipophilic cation diphosphin ^{99m}Tc -tetrofosmin upon reconstitution at room temperature with pertechnetate has been introduced (9). Preparation of this compound does not require heating but only a 15-min incubation at room temperature.

Preliminary studies revealed ^{99m}Tc -tetrofosmin to have good myocardial uptake ($\approx 1.2\%$ of the injected dose) and relatively slow clearance, while background clearance was rapid (10). Clinically insignificant redistribution associated with the possibility of early imaging (within 15-30 min) should make this compound particularly attractive in patients with acute ischemic syndromes.

A Phase II study was performed to determine the safety and optimum protocol for the use of ^{99m}Tc -tetrofosmin in the diagnosis of patients with ischemic heart disease. We report on the preliminary efficacy analysis and compare the Phase II study results with clinical and angiographic results as well as stress-redistribution thallium results.

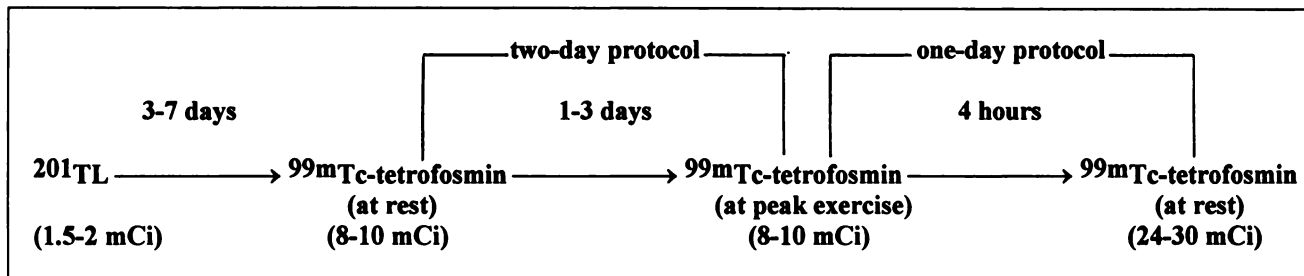


FIGURE 1. Protocol for Phase II tetrofosmin study.

METHODS

Forty patients (37 male, 3 female; mean age 60 yr, range 45–79 yr) with suspected or documented coronary heart disease were recruited at the following institutions: C.H.U. Liege, Belgium; Hôpital Neurocardiologique, Lyon, France; Northwick Park Hospital, Harrow U.K.; Academic Hospital Maastricht, University of Limburg, Maastricht, The Netherlands.

Patients eligible for inclusion had either stable myocardial infarction or a history of chest pain suggestive for CAD associated with positive signs of ischemia (e.g., ST-segment depression on exercise ECG, positive ^{201}Tl scan or an abnormal angiogram).

Exclusion criteria included females of child-bearing potential, patients with unstable disease whether recent infarction (<2 wk old) or angina, or associated problems such as congestive heart failure, cardiomyopathy, significant valvular heart disease or left bundle branch block. Cardioactive medications were stopped for 48 hr whenever possible.

The patients included in this report underwent coronary angiography as part of their diagnostic workup within 10 wk of tetrofosmin myocardial imaging (median value, range 3 yr before to 62 days after). Patients with a long delay between angiography and the tetrofosmin study had stable disease and no intercurrent events.

All scintigrams were available in digital form transferable to the core laboratory computer preparing scans for blinded random review.

Thirty-seven patients had one or more coronary lesions with stenosis of 70% or greater as graded by visual analysis. Two patients had previous bypass surgery with patent grafts and absence of disease progression. One patient with previous angioplasty studied for questionable restenosis had only a mild nonsignificant (30%) stenosis. Twenty-six patients had a previous myocardial infarction. Nine had single-vessel disease corresponding to the site of the infarct, while 17 had additional coronary artery lesions. Eleven patients had no previous myocardial infarction. Five patients had single-vessel disease; six patients had multivessel disease.

Prior to the commencement of the study, the protocol along with informed consent and patient information forms were reviewed and approved by the relevant hospital ethical committees. Details of the study were explained to each patient individually by the physician in the presence of an observer who witnessed the patient's written informed consent.

The study design is described below (Fig. 1). Each patient initially performed ^{201}Tl (1.5–2 mCi) bicycle exercise test followed by redistribution imaging. Three to seven days later, rest scintigrams were performed on each patient after supine injection of

$^{99\text{m}}\text{Tc}$ -tetrofosmin (8–10 mCi). Between 24 to 72 hr later, the patient underwent a second exercise test with $^{99\text{m}}\text{Tc}$ -tetrofosmin (8–10 mCi) followed approximately 4 hr later by a second resting scan performed after a rest injection of a third dose of tetrofosmin (24–30 mCi).

Patient preparation was identical for both the thallium and tetrofosmin phases of the study. Exercise was performed on a bicycle ergometer. The workload was initially set at 25 watts and increased by 25 watts every 3 min. Exercise was limited by chest pain, dyspnea, fatigue or significant ventricular arrhythmia. The tracer was injected intravenously at peak exercise and flushed with 10 ml of saline. Exercise was continued for 1 min after injection of the imaging agent. Each patient was encouraged to exercise to the same level (as determined by heart rate and blood pressure) in both the thallium and tetrofosmin phases of the study.

Static images in four standard views (anterior, left anterior oblique 40°, left anterior oblique 70° and left lateral) were acquired starting at about 10 min and 4 hr after injection of thallium and at 5, 30, 60, 90, 120 and 240 min after injection of tetrofosmin. Images were acquired for approximately 5 min per view.

Tetrofosmin was supplied by Amersham International Plc as a freeze-dried solid. Each vial contained 0.23 mg of tetrofosmin, 0.32 mg of disodium sulphosalicylate, 0.03 mg stannous chloride dihydrate and 1.00 mg of sodium D-gluconate sealed under an inert nitrogen atmosphere. Each vial was reconstituted with 4–8 ml of sterile $^{99\text{m}}\text{Tc}$ as sodium pertechnetate, containing no more than 30 mCi of $^{99\text{m}}\text{Tc}$ per ml. The vial was shaken to ensure adequate mixing and then allowed to stand at room temperature for 15 min. Radiochemical purity was determined by thin-layer chromatography and only preparations with $\geq 90\%$ labeling were used within 8 hr of preparation.

Data Analysis

Images were stored digitally and transferred to a central processing computer. Images were zoomed when appropriate to reduce disparity in image size between centers. A modified interpolative background subtraction was applied (11) and images were normalized to the highest pixel value within the heart. Pixels with higher value in noncardiac areas were also reduced to that normalization value. Images were printed on black and white transparency films and on color paper with and without background subtraction and smoothing.

Images were identified by code numbers only and read by four of the investigators. The readers had no knowledge of the origin of the scans or of the patient's underlying clinical condition.

The thallium exercise and redistribution images and the one-day tetrofosmin stress and rest images at 30–60 min were selected for analysis. Each view of the left ventricle was divided in five

TABLE 1
Hemodynamic Parameters During Ergometry

	Thallium	Myoview
Max. heart rate	124.9 (84–165)	124.3 (90–170)
Max. systolic BP	174.4 (130–240)	176.4 (136–240)
HR × BP product	22003 (11592–33000)	22046 (12240–35200)

segments. These were reported individually by the readers as normal or abnormal. Disagreements in the initial interpretation, if present, were resolved by consensus. Segments were combined in regional groups and the combined assessment of the exercise, redistribution or reinjection data led to the categorizations as normal, reversible, fixed or mixed defects in the anteroseptal, inferior, lateral or apical groups of segments. As previously reported, the anteroseptal segments were considered to primarily represent the left anterior descending territory, the lateral segments the left circumflex territory, and the inferior segments the posterior descending artery territory. The latter is most frequently part of the right coronary artery territory (12). The apical segments were considered to be nonspecific.

Coronary angiography and scintigraphic data were compared by determining the infarct territory on the basis of EKG (site of Q-waves) and angiographic data indicative of the artery responsible for myocardial infarction (corresponding coronary obstruction and wall motion abnormality). Analysis of the scintigraphic detection of myocardial infarction was focused to the infarct territory and performed in the 9 patients with previous myocardial infarction and single-vessel disease as well as in the 17 patients with previous myocardial infarction and multivessel disease. Three patients had two infarcts corresponding to separate coronary lesions. Scintigraphic patterns of potential myocardial ischemia were analyzed in the 11 patients without infarction as well as in the 17 patients with previous myocardial infarction and multivessel disease. In the latter patients, territories of previous myocardial infarction were excluded from this analysis.

Statistical Analysis

Quantitative data were analyzed using Student's t-test. Thallium and tetrofosmin concordance were assessed using kappa statistics (13).

RESULTS

No patient experienced any side effects from tetrofosmin injection. Vital sign measurements (including pulse, temperature, blood pressure and ECG) revealed no clinically significant drug-related changes postinjection either at rest or following exercise. There was no evidence of clinically significant drug-related changes in the hematologic parameters monitored. However, small transient increases in white cell counts following administration of ^{99m}Tc-tetrofosmin were noted in a minority of patients. Three patients had lymphocyte counts that rose transiently above the normal range.

Hemodynamic parameters during bicycle ergometry with thallium and tetrofosmin injections are shown in Table 1. Exercise workload and duration were not significantly

TABLE 2
Concordance Data on All Patients: Global Reading

		Thallium			
		Normal	Reversible	Fixed	Mixed
Tetrofosmin	Normal	6	0	0	1
	Reversible	1	1	0	4
	Fixed	0	2	13	4
	Mixed	1	1	2	4

different during the two procedures [mean duration of exercise: thallium, 10 min 15 sec (range 4 min 15 sec–18 min); Myoview™, 10 min 13 sec (range 5–21 min)]. Angina occurred in 17 and 19 patients and ST-segment depression in 11 and 13 patients, respectively. ST-segment changes were absent in all 12 “nonischemic patients” (three patients without significant residual lesions and nine patients with coronary lesions affecting only the artery responsible for the infarct). Abnormal ST-segment depression on stress ECG was observed in 8 of 11 patients without a previous myocardial infarction as compared to 5 of 17 patients with previous myocardial infarction.

Comparison of the diagnosis derived from the tetrofosmin and thallium images was performed overall (Table 2) and for each segmental group. The overall segmental concordance is 81%. Discordances predominate in the inferior (27%), lateral (20%) and apical (20%) regions, whereas concordance is better in the anteroseptal region (93%).

Thallium and tetrofosmin data were also analyzed using 2 × 2 tables comparing scans for the presence of any abnormality (abnormal versus normal) of myocardial ischemia (ischemia versus no ischemia, that is presence or absence of a reversible or mixed defect) and of myocardial scar (presence or absence of a fixed defect) (Table 3). Kappa values for these comparisons are listed in Table 4. Kappa values are lower for diagnosis of ischemia as compared to the two other groups.

Tetrofosmin identified an abnormality in 25 of the 26 patients with previous myocardial infarction and in 27 of the 29 infarct sites. By comparison, thallium identified 24 patients and 25 infarct sites (Table 5). With tetrofosmin, fixed defects were reported in 21 patients, partially reversible defects in three patients and reversible defects in one. With thallium, fixed defects were present in 16 patients, partially reversible defects in six patients and reversible defects in two. An example of a patient with a previous myocardial infarction is shown in Figure 2.

Twenty-eight patients had coronary artery lesions in arteries supplying noninfarcted regions. Sixteen of these potentially ischemic patients were identified by tetrofosmin; ten had a reversible defect, three a partially reversible defect and three a fixed defect. Sixteen were also identified by thallium; four had a reversible defect, eight a partially reversible defect and four a fixed defect. Thallium and tetrofosmin data differed in four of these patients, with

TABLE 3
Segmental Thallium/Tetrofosmin Comparison

		T H A L L I U M					
		Any defect		Ischemia		Scar	
		+	-	+	-	+	-
E	Inferior	+ 18	2	+ 5	3	+ 7	5
T		- 1	19	- 5	27	- 2	26
R	Lateral	+ 11	1	+ 5	3	+ 4	0
O		- 3	25	- 2	30	- 3	33
F	Apical	+ 18	3	+ 4	3	+ 13	1
O		- 4	15	- 3	30	- 2	24
S	Ant. Sep.	+ 12	0	+ 2	0	+ 8	2
M		- 0	28	- 2	36	- 0	30
I	Overall	+ 31	2	+ 10	4	+ 13	6
N		- 1	6	- 7	19	- 2	21

each tracer showing an abnormality in two patients while the results were normal with the other tracer (Table 6). An example of a patient with myocardial ischemia is shown in Figure 3.

Ten patients had no abnormality in the potentially ischemic territory. Three had single-vessel disease without previous myocardial infarction, seven had a previous myocardial infarction and multivessel disease but no further abnormality beyond the territory of the myocardial infarction. Thallium and tetrofosmin results were similar in these ten patients.

DISCUSSION

The primary goals of this Phase II study were to confirm the safety of tetrofosmin as a myocardial imaging tracer for

TABLE 4
Thallium and Tetrofosmin Comparison: Kappa Values

	Any defect	Ischemia	Scar
Inferior segments	0.85	0.43	0.55
Lateral segments	0.77	0.59	0.69
Apical segments	0.65	0.48	0.84
Anteroseptal segments	1.00	0.64	0.86
Overall	0.75	0.42	0.61

human use, to analyze its biokinetics in patients with CAD and to define an optimal imaging protocol by comparing different imaging times and sequences with a standard thallium stress-redistribution study. Results of these investigations have confirmed the safety of the agent (10). Similarly, in this investigation, no drug-related symptoms or changes in vital signs were noted. However, transient mild changes in white cell counts occurring in a minority of patients remain unexplained. They could be related to stress, exercise, multiple cannulation or tetrofosmin administration. Tetrofosmin has rapid blood and background clearance that allows early myocardial imaging. Yet myocardial washout is slow (4%/hr postexercise) and redistribution is not observed (14).

Comparison of single- and separate-day protocols suggests that both are possible and that a one-day protocol with a stress/rest sequence is feasible (15). Indeed, a stress/rest sequence is clinically preferable when myocardial scintigraphy is performed for diagnostic reasons because a normal stress study does not need to be confirmed by an additional resting scan. However, as reported by Taillefer, interpretation of images from such a protocol may be problematic because a normal resting scan is more difficult to recognize when superimposed on a previous abnormal stress study (16).

Thallium and tetrofosmin imaging data were compared segmentally. The overall concordance is quite satisfactory despite the expected variability. Better concordance was

TABLE 5
Comparison of Tetrofosmin and Thallium to Detect Sites of Myocardial Necrosis

		Anterior	Inferior	Lateral	No corresponding defect
Thallium	Anterior	10	0	0	1
ECG + ANGIO	Inferior	0	9	0	2
	Lateral	0	0	6	1
Tetrofosmin	Anterior	11	0	0	0
ECG + ANGIO	Inferior	0	9	0	2
	Lateral	0	0	7	0
Thallium	Anterior	10	0	0	1
Tetrofosmin	Inferior	0	8	0	1
	Lateral	0	0	6	1
	No corresponding defect	0	1	0	1

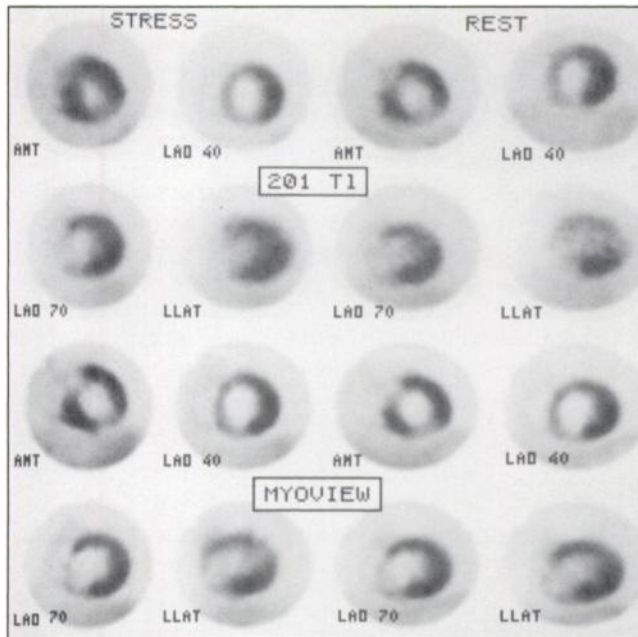


FIGURE 2. Stress and redistribution (rest) ^{201}Tl and $^{99\text{m}}\text{Tc}$ -tetrofosmin planar images in four projections in a patient with a large anteroseptal and apical infarct. Images are unchanged and the infarct appears as a fixed defect with both tracers.

observed in the anteroseptal region. This was probably related to the fact that there were less frequent abnormalities in that region and particularly less frequent reversible defects (17). The overall consequences of these discordances are better judged in relation to angiography. Indeed, as patients underwent angiography as part of their diagnostic workup, it was possible to report on the efficacy of tetrofosmin to diagnose myocardial infarction and ischemia in comparison to thallium.

Identification of the arterial site of infarct origin was

made based on ECG and angiographic data (18). Noninfarcted myocardial segments perfused by arteries with significant narrowing were considered as potentially ischemic, and scintigraphic abnormalities in these segments were considered to reflect ischemic changes. It is more difficult to assess the occurrence of residual ischemia in patients with previous myocardial infarction. Patients with previous myocardial infarction and single-vessel disease in an artery perfusing the infarct site were considered to have only myocardial necrosis and none of these patients had a positive ECG or anginal chest pain during exercise. Conversely, patients with previous myocardial infarction and multivessel disease were considered to have potentially ischemic myocardium during exercise, although ischemia probably occurred only in some of these patients as suggested by the exercise data (5/17 positive ECGs, despite six additional patients complaining of chest pain).

As previously reported with other tracers, including thallium, sestamibi, teboroxime, cesium, rubidium, potassium, as well as other PET tracers, the ability to recognize and localize myocardial infarction is excellent (19–21). Twenty-one of 26 infarct patients had fixed defects recognized by tetrofosmin and four had reversible or partially reversible defects. Results with thallium performances were similar although defects were seen as reversible or partially reversible in eight patients. In the absence of functional and follow-up studies to assess peri-infarct viability, it is impossible to judge which tracer correctly estimated the extent of reversibility in these patients.

Of the 28 patients with potentially ischemic myocardium, reversible or partially reversible defects were observed in ten and three patients with tetrofosmin and in four and eight patients with thallium, respectively, whereas fixed defects were reported to occur in three patients (tetrofosmin) and four patients (thallium). Incomplete re-

TABLE 6
Comparison of Tetrofosmin and Thallium for Detecting Myocardial Ischemia

		Thallium				Total
		Normal	Reversible	Fixed	Mixed	
Tetrofosmin	Normal	10		1	1	12
	Reversible	2	3		5	10
	Fixed		1	1	1	3
	Mixed			2	1	3
	Total	12	4	4	8	28

		Ischemia Thallium	
		+	-
Tetrofosmin	+	9	4
	-	3	12

K = 0.49 (95% CI: 0.17 to 0.82)

11 patients with CAD but no previous MI; 17 patients with previous MI and multivessel disease.

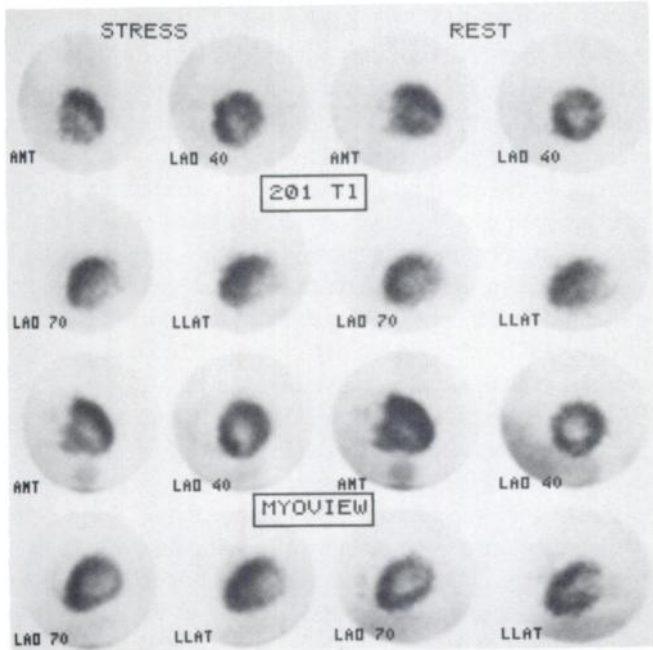


FIGURE 3. Stress and redistribution (rest) ^{201}Tl and $^{99\text{m}}\text{Tc}$ -tetrofosmin images in a patient with inferior and posteroinferior ischemia. The defect almost completely normalizes at redistribution (rest) on images obtained with both tracers.

distribution of thallium in reversibly ischemic myocardium is a known limitation of this tracer and reinjecting thallium at 4 hr or, as originally described, performing separate rest injections (22) is recommended. At the time of initiation of this study, however, the standard protocol for thallium was exercise injection with 4 hr redistribution, which we believed to be preferable for comparing tetrofosmin to thallium under such conditions. As can be seen, tetrofosmin did not appear to underestimate ischemia in comparison to thallium, which suggests that the slight differences observed in patients with infarction reflect technical rather than physiological differences.

Tetrofosmin thus appears to have adequate sensitivity for diagnosing myocardial ischemia and infarction. Analysis of specificity was not a goal of this study since it appeared inappropriate to expose a large number of volunteers or patients without CAD to a new tracer and radiation dose before establishing its preliminary efficacy. Indirect evidence can be presented, however, by the study of three patients with satisfactory revascularization and normal scans, as well as on the basis of absent abnormalities beyond the infarct territory in patients with previous myocardial infarction and single-vessel disease (eight of nine patients had concomitant fixed defects on thallium and tetrofosmin images, the last patient had a fixed defect with tetrofosmin and a reversible defect with thallium). The normalcy rate in subjects with low likelihood for CAD was studied later with this tracer and was found to be satisfactory (23).

If adequate sensitivity and specificity can be confirmed by larger studies involving both planar and tomographic imaging, tetrofosmin would appear to have several potential advantages over currently available agents:

1. It is easily prepared from a kit at room temperature, leading to faster preparation, an important consideration when study of acute patients is contemplated.
2. Imaging can be performed early, reducing waiting time for patients and potentially total study time.

Although less important than biological properties, these methodological constraints are important factors in clinical practice.

REFERENCES

1. Beller GA. Diagnostic accuracy of thallium-201 myocardial perfusion imaging. *Circulation* 1991;84:11-16.
2. Pohost GM, Zir LM, Moore RM, Guiney TE, Beller GA. Differentiation of transiently ischemic from infarcted myocardium by serial imaging after a single dose of thallium-201. *Circulation* 1979;55:294-302.
3. Brown KA. Prognostic value of thallium-201 myocardial perfusion imaging. A diagnostic tool comes of age. *Circulation* 1991;83:363-381.
4. Freeman MR, Williams AE, Chisholm RJ, Patt NL, Greyson ND, Armstrong PW. Role of resting thallium-201 perfusion in predicting coronary anatomy, left ventricular wall motion and hospital outcome in unstable angina pectoris. *Am Heart J* 1989;117:306-314.
5. Jones RH, Borges-Neto S, Potts JM. Simultaneous measurement of myocardial perfusion and ventricular function during exercise from a single injection of technetium-99m sestamibi in coronary artery disease. *Am J Cardiol* 1990;66:68E-71E.
6. Kiat H, Maddahi J, Roy LT, et al. Comparison of Tc-99m methoxy isobutyl isonitrile with thallium-201 imaging by planar and SPECT techniques for assessment of coronary disease. *Am Heart J* 1989;117:1-11.
7. Berman DS. Introduction—technetium-99m myocardial perfusion imaging agents and their relation to thallium-201. *Am J Cardiol* 1990;66:1E-4E.
8. Leppo J, DePuey G, Johnson LL. A review of cardiac imaging with sestamibi and tetrofosmin. *J Nucl Med* 1991;32:2012-2022.
9. Higley B, Lahiri A, Kelly DJ. Technetium-99m complexes of functionalized diphosphines for myocardial perfusion imaging in man. In: van der Wall EE, Sochor H, Righetti A, Niemeyer MG, eds. *What's new in cardiac imaging. SPECT, PET and MRI*. The Netherlands: Kluwer Academic Publishers; 1992:93-109.
10. Higley B, Smith FW, Smith T, et al. Technetium-99m 1,2-bis[bis(2 ethoxyethyl) phosphino]ethane: human biodistribution, dosimetry and safety of a new myocardial perfusion imaging agent. *J Nucl Med* 1993;34:30-38.
11. Smith WH, Watson DD. Technical aspects of myocardial planar imaging with technetium-99m sestamibi. *Am J Cardiol* 1990;66:16E-22E.
12. Rigo P, Bailey IK, Griffith LS, Pitt B, Wagner HN Jr, Becker LC. Stress thallium-201 myocardial scintigraphy for the detection of individual coronary arterial lesions in patients with and without previous myocardial infarction. *Am J Cardiol* 1981;48:209-216.
13. Altman DG. *Practical statistics for medical research*. London: Chapman and Hall, 1991:403-409.
14. Sridhara BS, Braat S, Rigo P, Itti R, Cload P, Lahiri A. Comparison of myocardial perfusion imaging with technetium-99m-tetrofosmin versus thallium-201 in coronary artery disease. *Am J Cardiol* 1993;72:1015-1019.
15. Braat S, Leclercq B, Itti R, Lahiri A, Rigo P. Myocardial perfusion imaging with tetrofosmin. Comparison between a one- and a two-day protocol [Abstract]. *J Am Coll Cardiol* 1993;21:251A.
16. Taillefer R, Gagnon A, Laflamme L, Gregoire J, Leveille J, Phaneuf D. Same-day injections of Tc-99m methoxy isobutyl isonitrile (hexamibi) for myocardial tomographic imaging: comparison between rest-stress and stress-rest injection sequences. *Eur J Nucl Med* 1988;15:113-117.
17. Braat SH, Lahiri A, Itti R, Rigo P. Comparison of defect size 5 and 240 minutes after injection of tetrofosmin at peak exercise [Abstract]. *J Nucl Med* 1992;33:874.
18. Dilsizian V, Rocco TP, Strauss HW, Boucher CA. Technetium-99m isonitrile myocardial uptake at rest. I. Relation to severity of coronary artery stenosis. *J Am Coll Cardiol* 1989;14:1673-1677.

19. Wackers FJTh. Thallium-201 myocardial scintigraphy in acute myocardial infarction and ischemia. *Semin Nucl Med* 1980;10:127-145.
20. Boucher CA. Detection and location of myocardial infarction using technetium-99m-sestamibi imaging at rest. *Am J Cardiol* 1990;66:32E-35E.
21. Fudo R, Kambara H, Hashimoto T, et al. Fluorine-18 deoxyglucose and stress N-13 ammonia positron emission tomography in anterior wall healed myocardial infarction. *Am J Cardiol* 1989;61:1191-1197.
22. Dilsizian V, Bonow RO. Current diagnostic techniques of assessing myocardial viability in patient with hibernating and stunned myocardium. *Circulation* 1993;87:1-20.
23. The Tetrofosmin Study Group. Comparative myocardial perfusion imaging with Tc-99m tetrofosmin and thallium-201: results of phase III international trial [Abstract]. *Circulation* 1992;86:1-506.

Condensed from 15 Years Ago:

Comparison of Wall Motion and Regional Ejection Fraction at Rest and During Isometric Exercise: Concise Communication

M. M. Bodenheimer, V. S. Banka, C. M. Fooshee, G. A. Hermánn and R. H. Helfant

*University of Pennsylvania School of Medicine,
Philadelphia, Pennsylvania*

The detection of regional abnormalities of left ventricular wall motion provides strong evidence for the presence of coronary heart disease. In 129 patients undergoing coronary arteriography, the relative value of radionuclide angiographic assessment of wall motion was compared with computer-generated regional ejection fraction, at rest and during handgrip exercise. Wall motion was determined by superposition of computer-derived end-diastolic and end-systolic perimeters. Relative regional ejection fraction was determined using a computer-generated 16-color isocount image that permitted

a quantitative assessment of zonal contribution to ejection fraction. Of the 129 patients, coronary arteries were normal in 31 and diseased in 98. Of 24 patients with single-vessel disease, wall motion abnormalities were present, at rest or during exercise in 15, whereas regional ejection fraction was detected in 20 patients. Seventy-four patients had multivessel disease. Of these, wall motion abnormalities occurred in 52 but regional ejection fraction was abnormal in 69 ($p < 0.01$). Overall, sensitivity was 67% by wall motion and 91% by relative regional ejection fraction ($p < 0.001$). Specificity was 94% by wall motion and 87% by regional ejection fraction (not significant). Thus, radionuclide angiographic assessment of regional ejection fraction during handgrip exercise is both highly sensitive and specific for coronary heart disease and significantly enhances detection of coronary heart disease compared with wall motion assessment, with little loss in specificity.

J Nucl Med 1979; 20:724-732