

- substrate availability on myocardial metabolism. *Am Heart J* 1983;105:492-504.
23. Raichle ME, Welch MJ, Grubb RT Jr, et al. Measurement of regional substrate utilization rates by emission tomography. *Science* 1978;199:986-987.
 24. Goldstein RA, Klein MS, Welch MJ, et al. External assessment of myocardial metabolism with C-11 palmitate in vivo. *J Nucl Med* 1980;21:342-348.
 25. Schon HR, Schelbert HR, Najafi A, et al. C-11 labeled palmitic acid for the noninvasive evaluation of regional myocardial fatty acid metabolism with positron computed tomography. II. Kinetics of C-11 palmitic acid in acutely ischemic myocardium. *Am Heart J* 1982;103:548-561.
 26. Ter-Pogossian MM, Klein MS, Markham J, et al. Regional assessment of myocardial metabolic integrity in vivo by positron-emission tomography with ¹¹C-labeled palmitate. *Circulation* 1980;61:242-255.
 27. Livni E, Elmaleh DR, Levy S, Brownell GL, Strauss HW. ¹¹C-Labeled betamethylheptadecanoic acid: A new approach for assessing myocardial tracers for positron tomography. *J Nucl Med* 1982;23:169-175.
 28. Elmaleh DR, Livni E, Levy S, Varnum D, Strauss HW, Brownell GL. Comparison of ¹¹C and ¹⁴C-labeled fatty acids and their betamethyl analogs. *Int J Nucl Med Biol* 1983;10:181-187.
 29. Elmaleh DR, Livni E, Brownell GL, Strauss HW. Biochemical rationale for the use of fatty acid analogs as agents for studying myocardial metabolism. *Proc Int Symp on Myocardial Metabolism: Clinical Cardiology* 1986.
 30. Strauss HW, Livni E, Brill B, et al. In vivo studies of branched chain fatty acids. *Proc Int'l Symp on Myocardial Metabolism: Clinical Cardiology* 1986.
 31. Fox KA, Abendschein DR, Ambos HD, Sobel BE, Bergmann SR. Efflux of metabolized and nonmetabolized fatty acid from canine myocardium. Implications for quantifying myocardial metabolism tomographically. *Circ Res* 1975;57:232-243.
 32. Abendschein DR, Fox KA, Ambos HD, Sobel BE, Bergmann SR. Metabolism of beta-methyl [1-¹¹C] heptadecanoic acid in canine myocardium. *Int J Rad Appl Instrum [B]* 1987;16:579-585.
 33. Humbert T, Keriel C, Battle DM, Luu-Duc C, Comet M, Cuchet P. Intramyocardial fate of 15-p-iodophenyl-beta-methylpentadecanoic acid (IMPPA): is it a good tracer of fatty acid myocardial uptake? *Mol Cell Biochem* 1989;88:195-200.
 34. Heymann MA, Payne BD, Hoffman JIE, Rodolph AN. Blood flow measurement with radionuclide labeled particles. *Prog Cardiovasc Dis* 1977;20:55-79.
 35. Fink GD, Montgomery JA, France D, et al. Metabolism of beta-methyl-heptadecanoic acid in the perfused rat heart and liver. *J Nucl Med* 1990;31:1823-1830.
 36. Litton J, Bergstrom M, Ericksson L, Bohm C, Blomquist G. Performance study of the PC-384 PET camera for the brain. *J Comput Assist Tomogr* 1984;8:74-87.

ERRATUM

Due to a production error, Figures 1 and 2 in the February 1994 First Impressions were printed incorrectly. The corrected figures and text are shown below.

FIRST IMPRESSIONS

A pinhole pertechnetate thyroid scan of a male with suspected Grave's disease.

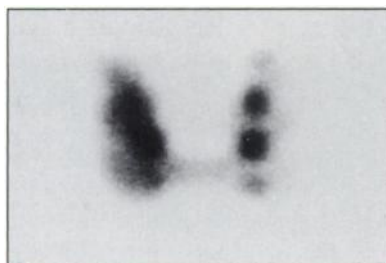


FIGURE 1.

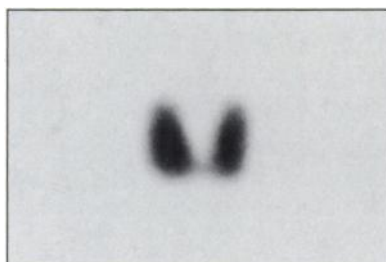


FIGURE 2.



FIGURE 3.

PURPOSE

This 69-yr-old man was referred for evaluation of hyperthyroidism. The multinodular appearance on the initial study (Fig. 1) did not correlate with the smooth gland on palpation. A parallel-hole view on another camera demonstrated a gland consistent with Grave's disease (Fig. 2). A repeat "flood" revealed the reason for the discrepancy (Fig. 3).

TRACER

Technetium-99m-pertechnetate

ROUTE OF ADMINISTRATION

Intravenously

TIME AFTER INJECTION

20 minutes

INSTRUMENTATION

General Electric gamma camera; Siemens gamma camera

CONTRIBUTORS

A. Southee, P. Thomas and D. Front

INSTITUTION

Royal Newcastle Hospital, Newcastle, NSW, Australia