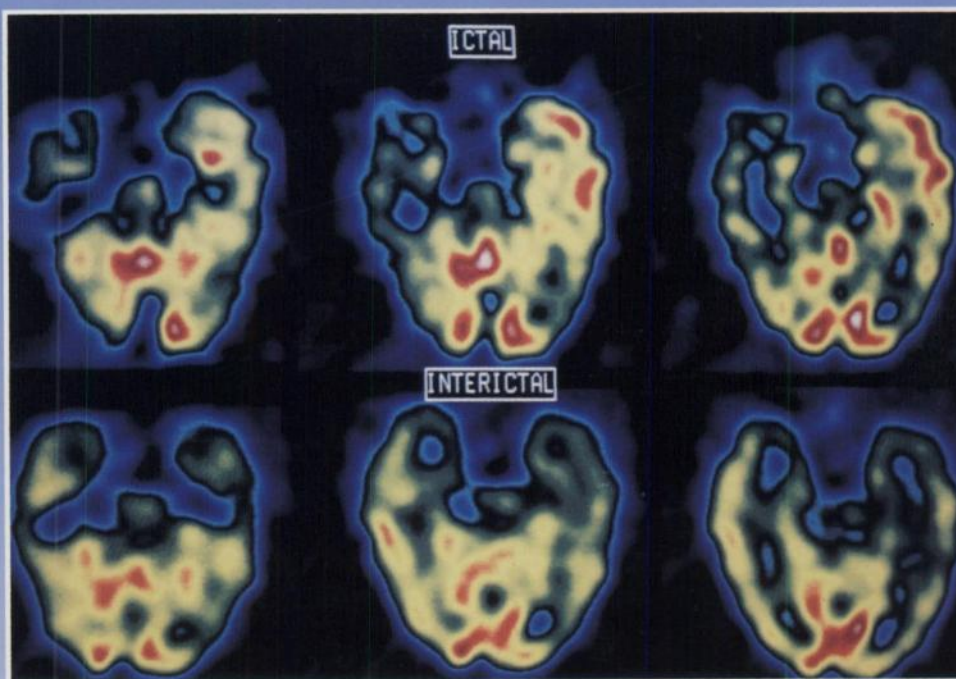

The Journal of Nuclear Medicine

JNM

Volume 35, Number 12 • December 1994



Ictal and interictal perfusion patterns in a 38-yr-old woman with bilateral EEG foci and suspected left temporal lobe sclerosis. Technetium-99m-ECD SPECT shows decreased perfusion in the left temporal lobe interictally and markedly increased perfusion in the left temporolateral and temporopolar region and slightly increased perfusion in the mesial structures during the seizure. See pages 1896-1901.



The Official Publication of
the Society of Nuclear Medicine, Inc.
