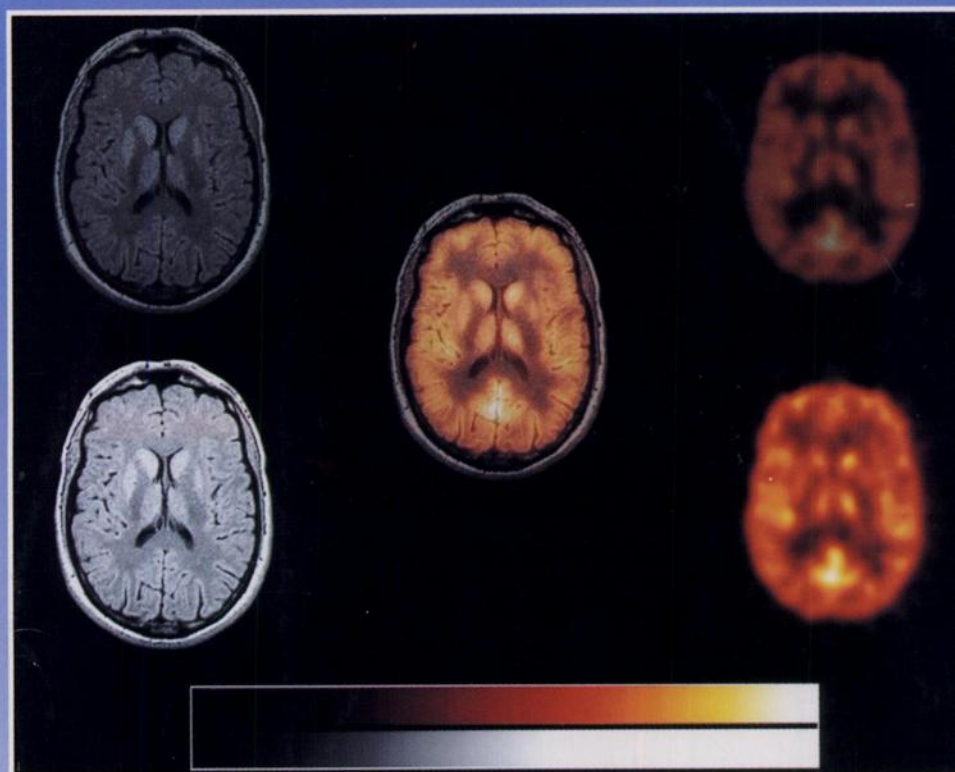

The Journal of Nuclear Medicine

JNM

Volume 35, Number 11 • November 1994



Interleaved MRI and PET slices of a normal brain (center). Interleaved MRI slice with PET color scale set to black (upper left) and noninterleaved MRI slice (lower left). Interleaved PET slice with MRI color scale set to black (upper right) and noninterleaved PET slice (lower right). See pages 1815-1821.



The Official Publication of
The Society of Nuclear Medicine, Inc.
