

# Myocardial Imaging with Technetium-99m-Tetrofosmin: Comparison of One-Day and Two-Day Protocols

Simon H. Braat, Brigitte Leclercq, Roland Itti, Avijit Lahiri, Bangalore Sridhara and Pierre Rigo

Department of Cardiology, Academic Hospital Maastricht, University of Limburg, The Netherlands; Centre Hospitalier Universitaire, Liege, Belgium; Hôpital Neuro-Cardiologique, Lyon, France; and Northwick Park Hospital and Clinical Research Centre, Harrow, United Kingdom

There is no evidence of myocardial redistribution after tetrofosmin injection, therefore, two separate injections are needed to differentiate scar from ischemia with this tracer. The injections can be given on the same day (one-day protocol) or on separate days (two-day protocol). As part of a Phase II clinical study, a one-day protocol was compared with a two-day protocol. **Methods:** Fifty-five patients with suspected coronary artery disease were studied according to the following protocol: on the first day at rest, anterior, left lateral, left anterior oblique 40° and 70° images were acquired 30 min after injection of 8 mCi of tetrofosmin for 5 min each. Two days later, exercise and rest images were acquired on the same day. At peak exercise, 8 mCi of tetrofosmin were injected and 30 min later the same four standard planar images were recorded as on Day one. Four hours after the exercise injection, 24 mCi of tetrofosmin were injected at rest and imaging was repeated 30 min later. Qualitative comparisons between the one- and two-day protocols were performed in 50 patients in whom all data were available following blinded evaluation of images by three readers. **Results:** All three readers reported identical results for the 26 patients. A difference in extent or location between the observers was found in seven patients, differences between normal and abnormal in eight patients, while discrepancies between ischemia and necrosis were noted in four patients. In five patients, an ischemic area was found according to the one-day protocol, but according to the data of the two-day protocol, this area was judged to be necrotic. One observer reported the opposite in one patient. These discrepancies between the reversibility of defects were restricted to the inferior wall. Comparison with <sup>201</sup>Tl data showed no systematic pattern of variation. **Conclusion:** Tetrofosmin can be used in a one-day protocol. However, in planar imaging, the inferior wall should be reported with caution.

**Key Words:** tetrofosmin; exercise test; perfusion tracer

**J Nucl Med 1994; 35:1581-1585**

Received Sept. 21, 1993; revision accepted May 5, 1994.  
For correspondence or reprints contact: Simon H. Braat, Dept. of Cardiology, Academic Hospital Maastricht, P.O. Box 5800, 6202 AZ Maastricht, The Netherlands.

**T**he clinical use of <sup>201</sup>Tl as a myocardial perfusion agent has been well-established for almost 20 yr (1-4). However, its physical characteristics are far from ideal. The energy of 68-80 keV is suboptimal, and its long half-life of 73 hr results in suboptimal dosimetry.

Since the introduction of <sup>201</sup>Tl attempts have been made to develop a perfusion agent labeled with <sup>99m</sup>Tc. Technetium-99m has an energy of 140 keV and a half-life of 6 hr making it an ideal radionuclide for gamma camera imaging. For several years two groups of tracers, isonitrile and boronic acid adducts of technetium dioxime BATO compounds, labeled with <sup>99m</sup>Tc have been available. Amersham International, plc has developed a tracer, tetrofosmin, which can be labeled at room temperature with <sup>99m</sup>Tc. Technetium-99m-tetrofosmin is a lipophilic, cationic diphosphine which has been developed for myocardial perfusion imaging. The chemical name of this compound is 1,2-bis[bis(2-ethoxyethyl)phosphino]ethene.

A Phase I study (5) showed <sup>99m</sup>Tc-tetrofosmin to have rapid heart uptake (approximately 1.2% of the injected activity by 5 min postinjection) and relatively slow clearance (approximately 1% of the injected activity at 2 hr postinjection). In contrast, background clearance was rapid from blood, lung and liver, and was significantly increased following exercise (particularly in terms of liver activity), probably largely due to enhanced sequestration of activity in skeletal muscle (5-9). There appears to be no significant myocardial redistribution 3-4 hr postinjection (10-13).

The Phase II study aimed to determine the safety and optimum protocol for the use of <sup>99m</sup>Tc-tetrofosmin in the diagnosis of ischemic heart disease.

As part of the Phase II study, we also evaluated the capability of a one-day protocol as compared to data acquired with a two-day protocol.

## METHODS

Fifty-five patients with stable coronary artery disease (CAD) were studied (51 males, 4 females, mean age 58.6 yr, range 45-79 yr). Patients had either a previous well-documented myocardial infarction (32 patients) or clinical symptoms suggestive of CAD

and at least one of the following: positive exercise ECG study; reversible myocardial ischemia as determined by a positive  $^{201}\text{Tl}$  scan; or occlusion of at least one major coronary artery by coronary angiographs  $>70\%$ . Patients with left bundle branch block, significant valvular disease, unstable angina and cardiomyopathies were excluded. Whenever possible, patients stopped their routine medication for at least 48 hr prior to the tests.

### Radlpharmaceutical Preparation

Tetrofosmin was supplied by Amersham International, plc as freeze-dried vials. Each vial contained 0.23 mg of tetrofosmin, 0.32 mg of disodium sulphosalicylate, 0.03 mg stannous chloride dihydrate and 1.00 mg of sodium D-gluconate sealed under an inert nitrogen atmosphere. Each vial was reconstituted at room temperature with 4–8 ml of sterile sodium [ $^{99\text{m}}\text{Tc}$ ]pertechnetate, containing no more than 30 mCi/ml of  $^{99\text{m}}\text{Tc}$ . The vial was shaken to ensure adequate mixing and then allowed to stand at room temperature for 15 min. Radiochemical purity was determined by thin-layer chromatography and only doses with  $\geq 90\%$  labeling were used within 8 hr of preparation.

### Study Design

Each patient underwent a symptom-limited  $^{201}\text{Tl}$  exercise test with continuous 12 lead ECG monitoring and 4-hr redistribution imaging.

Within 3–7 days of the  $^{201}\text{Tl}$  exercise test, each patient underwent a tetrofosmin study which involved stress imaging following graded, ergometric exercise (to the same workload as in the  $^{201}\text{Tl}$  study) and same-day rest-reinjection, 4 hr after the stress injection. On a separate day, tetrofosmin was also administered at rest.

Patients were exercised using graded bicycle ergometry until they developed any one of the following: angina, breathlessness, hypotension, severe arrhythmias, leg pain or fatigue. Patients continued exercising for 1 min after injection.

### Thallium-201 Scintigraphy

A standard stress-redistribution  $^{201}\text{Tl}$  imaging protocol was used. At peak exercise, 2.5 mCi of  $^{201}\text{Tl}$  (at the centers in Maastricht, Liege and Lyon) or 1.5 mCi (at Northwick Park) was injected and immediately flushed with 10 ml of normal saline solution. Planar imaging was started within 10 min after injection and four planar views (left anterior oblique  $40^\circ$ , left anterior oblique  $70^\circ$ , anterior and left lateral) were acquired. Each image was acquired for 5 min with a 20% symmetrical window centered around the 68–80-keV x-ray peaks.

Redistribution images were obtained 4 hr later, using the same parameters.

### Tetrofosmin Scintigraphy

Within 3–7 days of  $^{201}\text{Tl}$  scintigraphy, each patient was submitted to the same level of exercise. At peak exercise, 8–10 mCi of tetrofosmin was injected intravenously. The same four planar views acquired during the  $^{201}\text{Tl}$  study (left anterior oblique  $40^\circ$ , left anterior oblique  $70^\circ$ , anterior and left lateral) were acquired at 5, 30, 60, 90, 120 and 240 min postinjection. Each view was acquired for 5 min. After completion of the last dataset, patients received a repeat injection of 24–30 mCi of tetrofosmin at rest. Multiple planar images in the same four views were obtained again at 5, 30, 60, 90, 120 and 240 min after rest injection. Each view was again acquired for 5 min. All patients also received a single injection (8–10 mCi) at rest on a separate day and images were again obtained at 5, 30, 60, 90, 120 and 240 min postinjection.

### Data Analysis

For the purpose of the multicenter study, the  $^{201}\text{Tl}$  data were read by consensus opinion of the four principal investigators. For the purpose of this study, only the images obtained 30 min after injection were reported by three independent readers without prior knowledge of patients' history, stress electrocardiogram,  $^{201}\text{Tl}$  scan or coronary artery anatomy.

The residual activity remaining at 240 min postinjection from the initial injection at exercise during the one-day protocol was calculated for all patients.

All data were converted to the same image format and computer so that the center of origin was not apparent. Each view was arbitrarily divided into five segments that were read as normal, or showing fixed or reversible defects. Rest and stress segmental data were then combined to classify each myocardial region (anterior, septal, inferior and lateral) as normal, infarcted or ischemic, based on normal myocardial distribution, fixed defects or reversible defects, respectively. Partially reversible defects were classified as ischemia. Data from the one-day protocol (stress and rest) were read separately from the data of the two-day protocol (stress and rest).

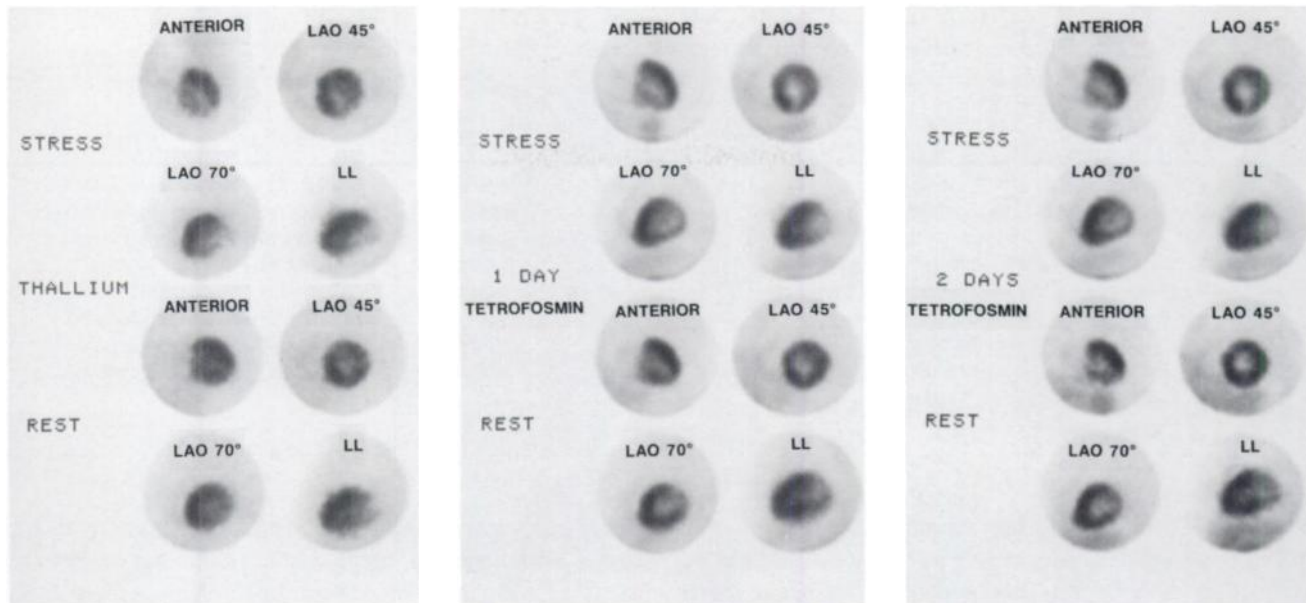
### RESULTS

The complete data of 50 of the 55 patients were studied. In five patients data were missing because of logistics and are therefore not included in the analysis. Evidence of a previous myocardial infarction, clinical documentation or pathologic q-waves on the ECG was present in 32 patients. Good correlation was found between the  $^{201}\text{Tl}$  and tetrofosmin data. No apparent redistribution was seen by visual analysis on the tetrofosmin images obtained 4 hr postinjection. The amount of activity 30 min after the second injection in the normal myocardium was compared to the activity in the same area 240 min after the first injection. The count ratio ranged between 4.1 and 5.9, mean  $4.95 \pm 0.3$  (s.d.).

The amount of activity in the normal myocardium after the second injection at rest was at least four times as high compared to the activity in the same area 240 min postinjection at peak exercise. In all 50 patients, the image sets obtained 30 min postinjection were suitable for evaluation.

All three observers found identical results in 26 of the 50 patients between the one-day and the two-day tetrofosmin protocol, as well as the  $^{201}\text{Tl}$  data (Fig. 1). Differences in the extent of the perfusion defects as seen by the three observers were noted in seven patients and were unrelated to the one-day or two-day protocol (Table 1). In four of these patients the differences concerned extension of the defect to the inferior wall in cases of a predominantly antero-septal abnormality or, conversely, extension of the defect to the septum in a predominantly infero-lateral and apical abnormality (2 patients). Thallium-201 showed less extension than tetrofosmin.

Differences between abnormal and normal readings among the three observers were noted in eight patients (Table 2). In five patients the  $^{201}\text{Tl}$  data were in agreement with two observers and in the other patient with one ob-



**FIGURE 1.** Clinical example in a patient with myocardial ischemia in the inferior and posterior-inferior wall. Results of thallium and tetrofosmin (one-day and two-day protocol) are identical. Four projections are presented for each image set. Exercise data are shown at the top and the rest data below.

server. Again these differences appear unrelated to the one-day or two-day protocol.

Reading differences between necrosis and ischemia were noted in four patients among the three observers (Table 3). In Patient 23, differences between the one-day and two-day protocols were also noted for one observer. Three  $^{201}\text{Tl}$  scans in this subgroup were read to have no reversible defects.

Finally, differences between the one-day and two-day protocols, with respect to ischemia or necrosis, were observed in six patients, five of whom had ischemia in the one-day protocol versus necrosis in the two-day protocol. This discrepancy was always related to the inferior wall. This difference between necrosis or ischemia in the inferior wall was observed in one patient by all three observers, in two patients by two observers and in two patients by one observer. One observer judged the lateral wall to be necrotic according to the one-day protocol while he judged

this wall to be ischemic in the two-day protocol. The  $^{201}\text{Tl}$  scans showed a reversible defect in four of these six patients (Table 4).

#### Intraobserver Variability

Because only one exercise study was performed, intraobserver variability can be judged only from differences in defect extent or from variations in the presence or absence of exercise abnormalities. Variability in the extent of the defect between the one-day and two-day protocols was found in two patients by two observers, while the other observer found a difference in extent between the one-day and two-day protocols in one patient.

#### DISCUSSION

Thallium-201 has been used for more than 20 yr as a myocardial perfusion agent in spite of its far from ideal characteristics. Therefore attempts have been made since its introduction to develop a perfusion agent labeled with  $^{99\text{m}}\text{Tc}$ . For several years two groups of tracers, cationic

**TABLE 1**  
Differences in the Extent or Location of the Perfusion Defects as Seen by the Three Observers

Patient no.	Observer 1		Observer 2		Observer 3		Thallium-201
	One-day	Two-day	One-day	Two-day	One-day	Two-day	
1	Ischemia A.S.L.I.	Ischemia A.L.I.	Ischemia A.L.	Ischemia A.L.	Ischemia A.L.	Ischemia A.L.	Ischemia A.L.
6	Necrosis A.S.I.	Necrosis A.S.I.	Necrosis A.S.I.	Necrosis A.S.I.	Necrosis A.S.	Necrosis A.S.	Necrosis A.S.I.
9	Ischemia L.	Ischemia L.	Ischemia A.	Ischemia A.	Ischemia L.	Ischemia L.	Ischemia L.
11	Necrosis I.L.	Necrosis I.L.	Necrosis I.L.	Necrosis I.L.	Necrosis S.I.L.	Necrosis S.I.L.	Necrosis I.L.
29	Ischemia S.I.	Ischemia S.I.	Ischemia I.	Ischemia I.	Ischemia I.	Ischemia I.	Ischemia I.
41	Necrosis A.S.I.	Necrosis A.S.I.	Necrosis A.S.	Necrosis A.S.I.	Necrosis A.S.	Necrosis A.S.	Necrosis A.S.
42	Necrosis A.S.I.	Necrosis A.S.I.	Necrosis A.S.	Necrosis A.S.	Necrosis A.S.	Necrosis A.S.	Necrosis A.S.

A = anterior; S = septal; I = inferior; and L = lateral.

**TABLE 2**  
Differences between Abnormal and Normal Readings Between the Three Observers

Patient no.	Observer 1		Observer 2		Observer 3		Thallium-201
	One-day	Two-day	One-day	Two-day	One-day	Two-day	
5	Necrosis L.	Necrosis L.	Normal	Normal	Normal	Normal	Necrosis L.
8	Ischemia A.L.	Ischemia A.L.	Normal	Normal	Ischemia A.	Ischemia A.	Ischemia A.L.
15	Ischemia L.	Ischemia L.	Normal	Normal	Ischemia L.	Ischemia L.	Ischemia L.
21	Normal	Normal	Normal	Normal	Necrosis S.	Necrosis A.S.	Normal
25	Ischemia I.	Ischemia I.	Normal	Normal	Normal	Normal	Normal
27	Necrosis I.	Necrosis I.	Normal	Normal	Normal	Normal	Necrosis I.
47	Necrosis S.	Necrosis S.	Normal	Normal	Necrosis A.S.	Necrosis A.S.	Normal
49	Ischemia I.	Ischemia I.	Ischemia I.	Ischemia I.	Normal	Normal	Ischemia I.

Abbreviations the same as in Table 1.

isonitriles (Cardiolite) and boronic acid adducts (Cardiotec) have been available. Amersham International, plc has developed a diphosphine-Tc complex, tetrofosmin (Myoview™), for myocardial perfusion imaging. Phase I and II studies (5,8,9) have shown that it has a fast clearance from the blood with excellent cardiac uptake and relatively slow clearance, no significant redistribution (10-12) and diagnostic accuracy for cardiac ischemia similar to <sup>201</sup>Tl (13).

As tetrofosmin does not redistribute, two injections are necessary to differentiate ischemic tissue. A two-day protocol was found to be superior to a one-day protocol for the diagnosis and localization of myocardial ischemia (14). In this two-day protocol, ischemia was seen in some patients judged to have necrotic areas using the one-day stress and rest protocol. These discrepancies were believed to result from the fact that during the one-day protocol, the resting

image was superimposed on the residual stress activity and that a "true" resting image was not obtained despite the use of a resting injection comprising three times the activity of the exercise injection. Furthermore, as rest injection follows the exercise injection, it is more difficult to exclude residual ischemia at the time of reinjection.

Working with tetrofosmin, however, we found a different pattern. In three patients (Patients 10, 16 and 48) at least two observers diagnosed an ischemic area in the inferior wall using the one-day protocol while a scar was judged to be present using the two-day protocol in the same patient. A possible explanation is that it reflects the influence of the liver and abdominal background on the count density in the inferior wall. Higher background contribution could make the inferior wall appear normal on the rest injection while it appears abnormal when the rest injection

**TABLE 3**  
Differences between Ischemia and Necrosis as Judged by Three Observers

Patient no.	Observer 1		Observer 2		Observer 3		Thallium-201
	One-day	Two-day	One-day	Two-day	One-day	Two-day	
14	Ischemia A.	Ischemia A.	Ischemia A.	Ischemia A.	Necrosis A.	Necrosis A.	Ischemia A.
23	Necrosis I.	Necrosis I.	Ischemia I.	Necrosis I.	Ischemia I.L.	Ischemia I.L.	Necrosis I.
31	Necrosis A.S.	Necrosis A.S.	Ischemia A.S.	Ischemia A.S.	Necrosis A.S.	Necrosis A.	Necrosis A.S.
44	Necrosis A.S.	Necrosis A.S.	Ischemia A.S.	Ischemia A.S.	Necrosis A.S.	Necrosis A.S.	Necrosis A.S.

Abbreviations the same as in Table 1.

**TABLE 4**  
Differences between the One-Day and Two-Day Protocol

Patient no.	One-day	Two-day	One-day	Two-day	One-day	Two-day	Thallium-201
10	Ischemia I.	Necrosis I.L.	Necrosis I.L.	Necrosis I.L.	Ischemia I.L.	Necrosis I.L.	Ischemia I.L.
16	Ischemia I.L.	Necrosis I.L.	Ischemia I.L.	Necrosis I.L.	Ischemia I.L.	Ischemia I.L.	Necrosis I.L.
20	Ischemia L.	Ischemia L.	Ischemia L.	Ischemia L.	Necrosis L.	Ischemia L.	Ischemia I.
23	Necrosis I.	Necrosis I.	Ischemia I.	Necrosis I.	Ischemia I.L.	Ischemia I.L.	Ischemia I.
30	Ischemia I.	Necrosis I.	Necrosis I.	Necrosis I.	Necrosis I.L.	Necrosis I.L.	Necrosis I.
48	Ischemia I.	Necrosis I.	Ischemia I.	Necrosis I.	Ischemia I.	Necrosis I.	Ischemia I.

Abbreviations the same as in Table 1.

is not preceded by another study. Indeed, at the time of the second study, the biliary activity has migrated through the gut and is more diffusely dispersed throughout the abdomen.

Consistent with that interpretation is the fact that this phenomenon affected only the inferior wall and no other parts of the heart. If so, the use of tomography could at least in part solve this problem.

It is somewhat surprising that a similar problem has not been reported using sestamibi. This may be due to the fact that in many one-day sestamibi studies the rest injection is administered first (14). Also, the faster liver and gallbladder clearance of tetrofosmin compared to sestamibi may contribute to this phenomenon.

The clinical impact of these discrepancies remains very limited as they affected only a very small number of patients.

In conclusion, tetrofosmin can be used in a one-day protocol; however, with planar imaging the inferior wall should be reported with caution.

## REFERENCES

1. Pohost GM, Zir LM, Moore RM, Guiney TE, Beller GA. Differentiation of transiently ischaemic from infarcted myocardium by serial imaging after a single dose of  $^{201}\text{Tl}$ . *Circulation* 1979;55:294-302.
2. Okada RG, Boucher CA, Strauss HW, Pohost GM. Exercise radionuclide imaging approaches to coronary artery disease. *Am J Cardiol* 1980;46:1188-1204.
3. Gibson RS, Watson DD, Craddock GB, et al. Prediction of cardiac events after uncomplicated myocardial infarction: a prospective study comparing pre-discharge exercise thallium-201 scintigraphy and coronary angiography. *Circulation* 1983;68:321-336.
4. Brown KA. Prognostic value of thallium-201 myocardial perfusion imaging. A diagnostic tool comes of age. *Circulation* 1991;83:363-381.
5. Lahiri A, Higley B, Smith T, et al. Myocardial perfusion imaging in man using new  $^{99\text{m}}\text{Tc}$ -labelled diphosphine complexes [Abstract]. *Nucl Med Commun* 1989;10:245.
6. Kelly JD, Higley B, Archer CM, et al. Technetium-99m complexes of functionalised diphosphines for myocardial imaging. In: Nicolini M, Bandoli G, Mazzi U, eds. *Technetium and rhenium in chemistry and nuclear medicine 3*. New York: Raven Press; 1990:405-412.
7. Lahiri A, Higley B, Crawley JCW, et al. Novel functionalized diphosphine complexes of  $^{99\text{m}}\text{Tc}$  for myocardial imaging in man [Abstract]. *J Nucl Med* 1989;30:818.
8. Higley B, Lahiri A, Kelly JD. Technetium-99m complexes of functionalized diphosphines for myocardial perfusion imaging in man. In: van der Wall EE, Sochor H, Righetti A, Niemeyer MG, eds. *What's new in cardiac imaging*. Dordrecht: Kluwer Academic Publisher.
9. Higley B, Smith FW, Smith T, et al. Technetium-99m 1,2-bis(bis(2 ethoxy ethyl) phosphino-ethane): human biodistribution, dosimetry and safety of a new myocardial perfusion imaging. *J Nucl Med* 1993;34:30-38.
10. Braat SH, Lahiri A, Itti R, Rigo P. Comparison of defect size 5 and 240 minutes after injection of tetrofosmin at peak exercise. *J Nucl Med* 1992;33:210,874.
11. Sridhara BS, Braat S, Itti R, Rigo P, Cload P, Lahiri A. Early and late myocardial imaging with a new technetium-99m-diphosphine (PPN1011) in coronary artery disease [Abstract]. *J Am Coll Cardiol* 1992;19:202A.
12. Jain D, Wackers FJTh, McMahon M, Zaret BL. Is there any redistribution with  $^{99\text{m}}\text{Tc}$ -tetrofosmin imaging? A quantitative study using serial planar imaging. *Circulation* 1992;86:1-46.
13. Sridhara BS, Braat SH, Rigo P, Itti R, Cload P, Lahiri A. Myocardial perfusion imaging with  $^{99\text{m}}\text{Tc}$ -tetrofosmin versus thallium-201 in coronary artery disease. *Am J Card* 1993;72:1015-1019.
14. Taillefer R, Gagnon A, Laflamme L, Gregoire J, Leveille J, Phaneuf DC. Same day injection of Tlc-99m methoxy isobutyl isonitrile (hexamibi) for myocardial tomographic imaging: comparison between rest-stress and stress-rest injection sequence. *Eur J Nucl Med* 1989;15:113-117.