

Successful Gallium-67 Imaging of North American Pulmonary Blastomycosis

B. Firat Dayanikli, Alan F. Weissman and Richard L. Wahl

Division of Nuclear Medicine, Department of Internal Medicine, University of Michigan Medical Center, Ann Arbor, Michigan

South American blastomycosis (Paracoccidioidomycosis) has been previously imaged using ^{67}Ga imaging. We present a case of North American pulmonary blastomycosis successfully imaged with ^{67}Ga . Clinical, radiologic and biopsy findings are correlated.

J Nucl Med 1993; 34:958–960

Gallium-67 imaging has been widely employed in the detection of inflammation, infections and tumors. Gallium imaging has been successful in detecting various mycotic infections in humans (1–6). For example, ^{67}Ga has been found useful in detecting the extent of disease and in evaluating response to therapy of South American blastomycosis, known as paracoccidioidomycosis (7). North American blastomyces dermatitidis, which occurs predominantly in the south central and midwestern United States, may also be amenable to evaluation by ^{67}Ga scintigraphy (8). We present a case of pulmonary blastomycosis successfully imaged with ^{67}Ga .

CASE REPORT

A previously healthy 41-yr-old male was transferred to our institution after being evaluated at another hospital for a 2-mo history of febrile illness associated with a right lower lobe infiltrate and a possible diagnosis of pulmonary blastomycosis.

At that institution, in addition to the right lower lobe consolidation, elevated white blood cell count and fever, the patient had multiple signs and symptoms (headache, myalgias, nonproductive cough) and biochemical abnormalities (moderately elevated transaminases, anemia) suggestive of a disseminated infection. The pertinent studies and findings included: a right upper quadrant ultrasound which showed a normal gallbladder, no biliary dilatation and normal hepatic parenchyma; an hepatitis screen was only positive for Hepatitis A antibody; head CT and lumbar puncture were all unremarkable; sputum and blood cultures were negative as was a biochemical screen for connective tissue disorders and malignancy. A transbronchial biopsy was negative for malignancy, bacterial infection, protozoans and tuberculosis, but cul-

tures revealed dysmorphic fungi with PAS stain suggestive of blastomycosis.

On admission to our hospital, the patient complained of a nonproductive cough, myalgias, night sweats and fronto-parietal headaches. Pertinent points in the history revealed that the patient was a nonsmoker, owned an air conditioning firm, had no previous exposure to farm animals or birds and had a dog. He had traveled in the southwestern states 9 mo prior to admission and had “flu-like symptoms” while he was in Tennessee. Upon careful questioning, he remembered walking in the woods in the mid-west region of the country. On physical examination, he had a temperature of 101°F, pulse 92, blood pressure 120/70 and a few rales at the right lung base. Relevant biochemical findings were as follows: WBC 13,700; hemoglobin 11.1 g/dl; AST/ALT 282 IU/liter/270 IU/liter (normal AST/ALT 2-35 IU/liter, 0–45 IU/liter); and admission chest x-ray confirmed the homogeneous mass-like consolidation in the right lower lobe (Fig. 1A).

Further radiologic evaluation by computed tomography (CT) showed that this mass-like consolidation in the right lower lobe had a central area of decreased attenuation and was associated with a small right pleural effusion (Fig. 1B). A bone scan obtained to evaluate the possibility of disseminated blastomycosis showed increased tracer uptake in the proximal upper extremity and lower extremity muscles and uptake in the ribs which were concordant with intramuscular injections and history of trauma.

A gallium scan of the whole body and spot views were obtained using a medium-energy, parallel-hole collimator 24 hr after intravenous administration of 5 mCi of ^{67}Ga . This showed increased uptake in the right lower lung field corresponding to an area of “infiltrate” demonstrated by CT (Fig. 1C). Soft-tissue uptake seen in the shoulder and thighs were concordant with bone scan abnormalities. Further evaluation of the patient’s liver function abnormalities by liver biopsy was unremarkable. Repeat lumbar punctures and cranial magnetic resonance imaging were unremarkable for explaining the etiology of the patient’s headaches. After confirmation of the pathologic diagnosis of pulmonary blastomycosis (Fig. 2), the patient was treated with oral fluconazole and was discharged from the hospital with improvement.

DISCUSSION

Blastomycosis, coccidioidomycosis and histoplasmosis are the major pulmonary mycoses of humans. Each is considered to be a primary pulmonary disease acquired by inhalation of infectious spores from the environment. Blastomycosis is often acquired by inhalation of the fungus from soil, rotting wood or decomposed vegetation (9).

North American blastomycosis, first reported in 1894

Received Dec. 3, 1992; revision accepted Feb. 1, 1993.

For correspondence and reprints contact: Richard L. Wahl, MD, Div. of Nuclear Medicine, University of Michigan Medical Center, 1500 E. Medical Center Dr., B1G412, Ann Arbor, MI 48109-0028.

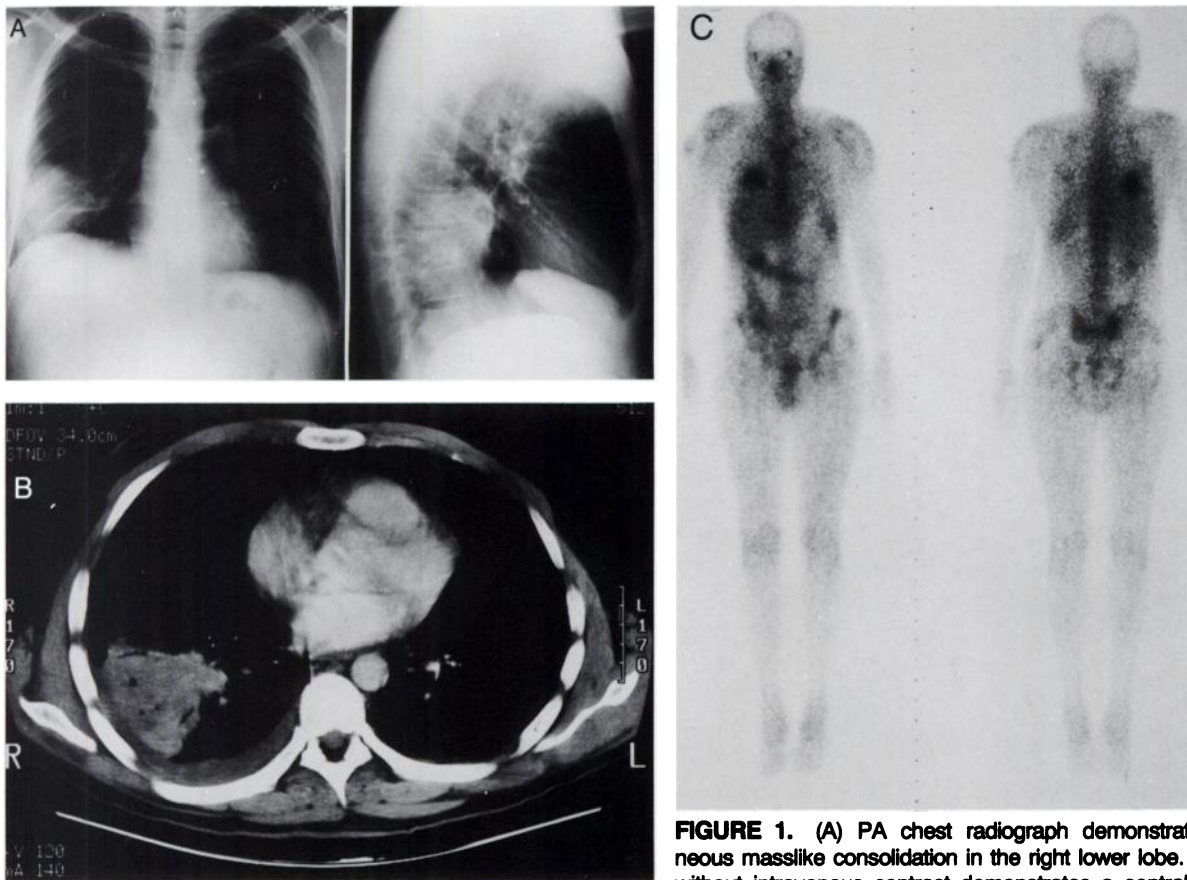


FIGURE 1. (A) PA chest radiograph demonstrates homogeneous masslike consolidation in the right lower lobe. (B) CT scan without intravenous contrast demonstrates a central area of decreased attenuation in the mass and associated with pleural effusion. (C) Gallium-67 scan at 24 hr postinjection demonstrates increased uptake of ^{67}Ga in the right lower lung field.

and once thought to be a geographically localized disease, has now been reported worldwide. The greatest number of cases occur in the Mississippi, Missouri and Ohio River basins (10).

Pneumonia is the most common manifestation of blastomycosis, and the lungs are almost always the organ initially infected. Adult respiratory distress syndrome developing

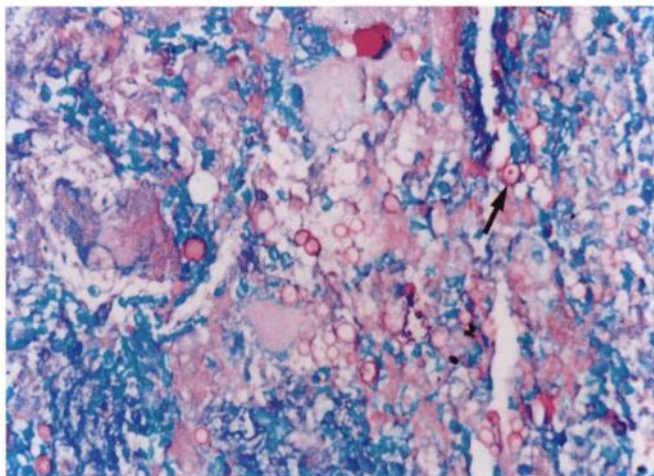


FIGURE 2. Photomicrograph of transbronchial biopsy from right lower lobe specimen with PAS stain shows round, oval-shaped (arrow) yeast forms of *B. dermatitidis*.

as a cause of pulmonary blastomycosis has been previously described (11). The manifestations of disease at other body sites are the result of hematogenous dissemination from a primary pulmonary infection. The dissemination of infection from the primary lung lesion may not be evident for weeks or years after the initial pulmonary appearance (9). Skin, bone, prostate and the central nervous system are the next most frequently infected organs in descending order (12,13). Involvement of the peritoneum (14) and spleen (15) are also described in the literature.

The spectrum of clinical manifestations, varying severity and unusual occurrence in most geographic areas make the diagnosis of blastomyces dermatitis difficult. Because routine serologic methods and skin tests are not reliable for this pathogen, diagnosis is made by visualization of the organism in tissue, sputum, exudate or by culture (16). The pathological picture involves inflammatory response consisting of clusters of neutrophils, noncaseating granulomas with epithelioid and giant cells (10).

Radiologic findings in pulmonary blastomycosis are variable, ranging from consolidation to fibronodular infiltrates, with or without cavitation (17,18). Uncommonly, pulmonary blastomycosis may present as a mass that resembles a lung tumor on radiographs (19). Knowledge of the risk factors such as living in or visiting endemic areas or activ-

ities involving contact with soil or associated skin lesions, should alert the physician to the possibility of blastomycosis. In the case presented, the patient had been in the endemic areas and had contact with soil in the woods.

Skeletal involvement is the next most common extrapulmonary manifestation after skin disease. The long bones, vertebrae and ribs are most commonly involved (20) but any bone can be affected. A well circumscribed osteolytic lesion is typical (21). Gallium-67 imaging has been shown to detect radiologically and clinically unsuspected lesions in South American blastomycosis (paracoccidioidomycosis) (10). It needs further evaluation whether this is the case for North American blastomycosis. In the case presented, there was no evidence of skeletal involvement on either the ⁶⁷Ga or accompanying bone scan.

Endogenous reactivation and opportunistic infections have been newly appreciated as clinical presentations of blastomycosis (22). Fungal pneumonias as a complication of solid organ transplantation are subject to similar diagnostic difficulties as they are in immunocompetent hosts (23).

The feasibility of ⁶⁷Ga imaging in paracoccidioidomycosis has been documented. Gallium-67 scanning has been useful in evaluating the extent of blastomycosis in this case of North American blastomycosis. Further evaluation is necessary as to whether the application of ⁶⁷Ga in this setting holds as much promise as it does for paracoccidioidomycosis in defining the degree of activity of the disease process, evaluating the spatial extent of the disease and the treatment response. As an increasing number of patients with acquired immunodeficiency are affected with fungal pathogens, the accurate diagnosis and monitoring of such infections is becoming increasingly relevant.

REFERENCES

1. Armbuster TG, Georgen TG, Resnick D, Catanzaro A. Utility in bone scanning in disseminated coccidioidomycosis. *J Nucl Med* 1977;18:450-454.
2. McGahan J, Graves D, Palmer P, Stadalnik R. Classic and contemporary imaging of coccidioidomycosis. *Am J Radiol* 1981;136:393-404.
3. Stadalnik RC, Goldstein E. Diagnostic value of gallium and bone scans in evaluation of extrapulmonary coccidioidomycoses. *Am Rev Respir Dis* 1980;14:149-151.
4. Okuyama S, Sato T, Sasaki M. Delineation of aspergilloma and granuloma with radiogallium and radiostrontium. *Sci Rep Res Inst Tohoku Univ* [Med] 1981;28:1-6.
5. Rao GM, Guruprakash GH, Bhaskar G. Localization of gallium-67 in aspergilloma [Letter]. *J Nucl Med* 1979;20:900.
6. Thadepalli H, Salem FA, Mandal AK, Rambhatla K, Einstein HE. Pulmonary mycetoma due to *Coccidioides immitis*. *Chest* 1978;71:429-430.
7. Giorgi MC, Camargo EE, Pinto WP, Del NG. Gallium-67 imaging in the diagnosis of blastomycosis. *Eur J Nucl Med* 1987;13:300-304.
8. Bradsher RW. Blastomycosis. *Clin Infect Dis* 1992;14(suppl 1):S82-S90.
9. Bennet JE. Fungal Infections. In: Wilson JD, ed. *Harrison's principles of internal medicine*. New York: McGraw-Hill; 1991:743-753.
10. Logsdon MT, Jones HE. North American blastomycosis: a review. *Cutis* 1979;24:524-527.
11. Evans ME, Haynes JB, Atkinson JB, Delvaux TJ, Kaiser AB. Blastomycosis dermatitis and the adult respiratory distress syndrome. Case reports and review of the literature. *Am Rev Respir Dis* 1982;126:1099-102.
12. Schwartz J, Baum GL. Blastomycosis. *Am J Clin Pathol* 1951;11:999-1029.
13. Gonyea EF. The spectrum of primary blastomycotic meningitis: a review of central nervous system blastomycosis. *Ann Neurol* 1978;3:26-39.
14. Perez LG, Nolan RL, Chapman SW, Achord JL. Peritoneal blastomycosis. *Am J Gastroenterol* 1991;86:357-359.
15. Dubuisson RL, Jones TB. Splenic abscess due to blastomycosis: scintigraphic, sonographic and CT evaluation. *Am J Roentgenol* 1983;140:66-68.
16. Bradsher RW. Systemic fungal infections: diagnosis and treatment. I. Blastomycosis. *Infect Dis Clin North Am* 1988;2:877-898.
17. Halvorsen RA, Duncan DJ, Merten DF. Pulmonary blastomycosis: radiologic manifestations. *Radiology* 1984;150:1-5.
18. Poe RH, Vasollo CL, Plessinger VA. Pulmonary blastomycosis versus carcinoma. A challenging differential. *Am J Med Sci* 1972;263:145-155.
19. Weingardt J, Li YP. North American blastomycosis. *Am Fam Physician* 1991;43:1245-1248.
20. Basset FH, Tindall J. Blastomycosis of bone. *South Med J* 1971;65:547-555.
21. Gehweiler JA, Capp MP, Chick EW. Observations on the roentgen patterns in blastomycosis of bone. A review of cases from the Blastomycosis Cooperative Study of the Veterans Administration and Duke University Medical Center. *Am J Roentgenol Radium Ther Nucl Med* 1970;108:497-510.
22. Tenenbaum MJ, Greenspan J, Kerkering TM. Blastomycosis. *Crit Rev Microbiol* 1982;9:139-163.
23. Zeluff BJ. Fungal pneumonia in transplant recipients. *Semin Respir Infect* 1990;5:80-89.