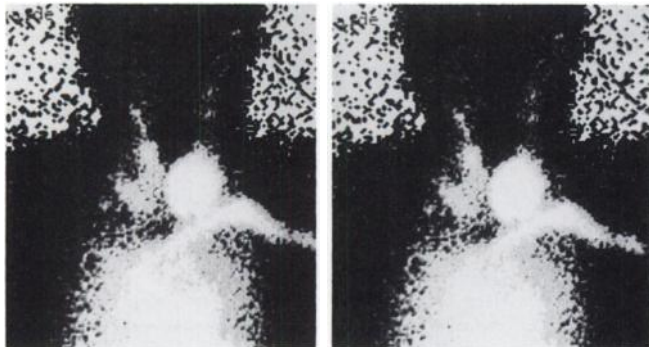

**FIGURE 2.** Perfusion image of the same patient. Note that the suppressed right lobe of the thyroid is now visualized.

## REFERENCES

1. Corstens F, Huhsmans D, Kloppenborg P. Tl-201 scintigraphy of suppressed thyroid: an alternative for I-123 scanning after TSH stimulation. *J Nucl Med* 1988;29:1360-1363.
2. Ramanathan P, Patel RB, Subrahmanyam N, et al. Visualization of suppressed thyroid tissue by Tc-99m-tertiary butyl isonitrile: an alternative to post-TSH stimulation scanning. *J Nucl Med* 1990;31:1363-1365.

Erkan Derebek  
Hayal Özkiliç  
Ege University Hospital  
Izmir, Turkey

## Thallium Stress Test for ECG Response and Perfusion Images

**TO THE EDITOR:** The CPC entitled "A Thallium Scan Goes to Court" appearing in the January issue was very well done and informative. Although I am sure all of us agree with the court's decision in favor of the defendants, it is somewhat disheartening that there were colleagues willing to be so resolute in their testimony with regard to the thallium stress test for both the ECG response and perfusion images.

Certainly the case presents a number of interesting questions. These include whether the test was indeed a false-negative, unusual for a middle-aged man, even from the standpoint of the ECG response, or whether in fact the underlying LAD stenosis was not flow-limiting (flow-limiting or decreased coronary blood flow reserve does not automatically indicate the presence of myocardial ischemia) at the time of the study. Certainly we are well aware that local-endothelial and rheologic factors play a very important role during "active" phases, especially periods of unstable angina pectoris. Although a number of reports have indicated that it is difficult to identify a culprit lesion and up to 66% of acute infarctions may be associated with stenosis of less than 50% (1,2), this is most likely not the general community experience. Our experience is less than 30% (3000 diagnostic catheterizations and >600 interventions per year). In this particular case, cause and effect along with the timing of the events can be debated. However, to go back to the beginning, this was a 41-year-old male with a very bothersome clinical presentation with multiple coronary artery disease risk factors present, in addition to a baseline abnormal ECG. Even though the patient was stabilized by medical therapy, considering his age and presentation, invasive

evaluation with coronary arteriography should have been performed. If the patient's clinical presentation was more atypical, if he had no or minimal coronary artery disease risk factors, and a perfectly normal ECG, then perhaps initial noninvasive evaluation would have been appropriate. Although the physician's approach was acceptable and no negligence occurred with regard to the performance and interpretation of the patient's thallium stress test, the initial approach to this patient's diagnosis and therapeutic considerations should be considered inadequate.

## REFERENCES

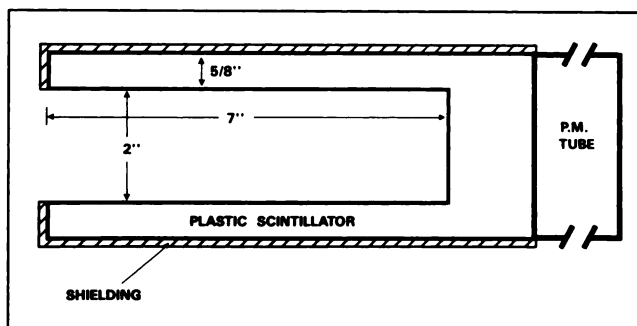
1. Ambrose JA, Tannenbaum MA, Alexopoulos D, et al. Angiographic progression of coronary artery disease and the development of myocardial infarction. *J Am Coll Cardiol* 1988;12:56-62.
2. Little WC, Constantinescu M, Applegate RJ, et al. Can coronary angiography predict the site of a subsequent myocardial infarction in patients with mild-to-moderate coronary artery disease? *Circulation* 1988;79:1157-1166.

Peter Alagona Jr.  
St. Joseph's Heart Institute  
Clinical Research Center  
Tampa, Florida

## Quantitative Dynamic Parameters to Evaluate Impotence

**TO THE EDITOR:** In light of our own interest in impotence studies (1), we were most pleased to see the recent attention focused on this topic in the January issue of *The Journal of Nuclear Medicine* (2-4). The ability to quantitate dynamic parameters by scintimetric means contributes uniquely to the evaluation of impotence and has increased in relevance with the availability of intracavernosal injection therapy.

In the historical development of both penile blood pool and xenon-washout studies, the original researchers utilized nonimaging probes to measure penile radioactivity (5-7). Subsequent workers substituted imaging on the Anger gamma camera with background subtraction and operator-defined regions of interest; however, no study has indicated that spatial information is of any particular value, other than in defining the penile region (1). With this understanding, absence of penile images in the recent publications comes as no surprise (2,3). In our own impotence



**FIGURE 1.** Cross-sectional schematic of the circumferential penile probe graphically demonstrates the near-optimal geometric efficiency and lack of collimation possible with this dedicated, portable unit.

studies, we have elected to use a circumferential nonimaging crystal to quantitate penile activity. In comparison to gamma camera methods, the nonimaging crystal offers portability, superior count rate sensitivity, eliminates operator-dependent regions of interest and frees up expensive gamma cameras and computer systems for their intended imaging applications.

While nuclear medicine has tended to abandon nonimaging probes in all but thyroid applications, the current climate of cost-effectiveness and radiation awareness argues effectively for these devices in specialized applications such as this.

#### ACKNOWLEDGMENTS

Dr. Zuckier is supported in part by Physician Scientist Award 1K11 CA01503; start-up funds for the circumferential penile probe were provided through a Pilot Research grant awarded by the Society of Nuclear Medicine Education and Research Foundation.

#### REFERENCES

1. Zuckier LS, Strober MD. Nuclear medicine in problems of fertility and impotence. *Semin Nucl Med* 1992;22:in press.
2. Groshar D, Lidgi S, Frenkel A, Vardi Y. Radionuclide assessment of penile corporal venous leak using technetium-99m-labeled red blood cells. *J Nucl Med* 1992;33:49-51.
3. Miraldi F, Nelson AD, Jones WT, Thompson S, Kursh ED. A dual-radioisotope technique for the evaluation of penile blood flow during tumescence. *J Nucl Med* 1992;33:41-46.
4. Seftel AD, Goldstein I. Vascular testing for impotence. *J Nucl Med* 1992;33:46-48.
5. Shirai M, Nakamura M, Ishii N, Mitsukawa S, Sawai Y. Determination of intrapenial blood volume using <sup>99m</sup>Tc-labeled autologous red blood cells. *Tohoku J Exp Med* 1976;120:377-383.
6. Shirai M, Ishii N, Mitsukawa S, Matsuda S, Nakamura M. Hemodynamic mechanism of erection in the human penis. *Arch Androl* 1978;1:345-349.
7. Wagner G, Uhrenholdt A. Blood flow measurement by the clearance method in the human corpus cavernosum in the flaccid and erect states. In: Zorniootti AW, Rossi G, eds. *Vasculogenic impotence*. Springfield, Illinois: Charles C. Thomas; 1980:41-46.

Lionel S. Zuckier  
M. Donald Blaufox,  
Richard Ricciardi  
Arnold Melman  
*Albert Einstein College of Medicine  
Montefiore Medical Center  
Bronx, New York*