
Comparison of Technetium-99m-MIBI and Thallium-201-Chloride Uptake in Primary Thyroid Lymphoma

Andrew M. Scott, Lale Kostakoglu, James P. O'Brien, David J. Straus, Hussein M. Abdel-Dayem, and Steven M. Larson

Nuclear Medicine Service and Lymphoma Service, Memorial Sloan-Kettering Cancer Center, New York, New York

A case of primary thyroid lymphoma demonstrating uptake of ^{99m}Tc -hexakis-2-methoxy isobutyl isonitrile (MIBI) is presented. The ^{99m}Tc -MIBI image more clearly delineated the extent of tumor as demonstrated on CT compared to ^{201}Tl -chloride and [^{99m}Tc]pertechnetate images. Following two courses of chemotherapy, repeat radionuclide studies and CT scan showed complete resolution of the thyroid tumor. Technetium-99m-MIBI may be useful in the assessment of disease activity and monitoring response to treatment in patients with lymphoma.

J Nucl Med 1992; 33:1396-1398

The use of ^{99m}Tc -hexakis-2-methoxy isobutyl isonitrile (MIBI) as a myocardial perfusion agent has been well established (1,2). Although ^{99m}Tc -MIBI uptake has been described in benign, malignant and inflammatory lesions (3-10), the utility of ^{99m}Tc -MIBI uptake in lymphoma is unknown. We present a case of primary thyroid lymphoma successfully imaged with ^{99m}Tc -MIBI.

CASE REPORT

The patient, a 62-yr-old white woman, initially presented to her local doctor in March 1991 complaining of neck swelling. There was no history of thyroid disease or previous malignancy, and the patient reported no systemic symptoms at the time of presentation. An ultrasound of the neck was performed, which suggested multinodular change throughout both thyroid lobes. Thyroid function tests were normal apart from a raised antithyroglobulin titre of 2.6 (normal $<0.3 \mu\text{g/ml}$). The patient was then placed on Synthroid therapy, 150 $\mu\text{g/day}$. After 3 mo of therapy, the neck mass was noticed to be enlarging, and a fine-needle aspiration biopsy was performed. The results of the biopsy were inconclusive, although suggestive of lymphoma, and the patient was referred to this institution for further evaluation.

On presentation, a firm mass, approximately $8 \times 5 \text{ cm}$, was palpable in the right side of the neck. A CXR showed a mass in the superior mediastinum extending down from the neck, and

displacing the trachea to the left. A CT scan revealed a $13 \times 6 \text{ cm}$ mass in the right side of the neck, extending circumferentially around and possibly involving the right lobe of the thyroid. Adjacent structures in the neck were markedly displaced, and there was extension of tumor into the superior mediastinum (Fig. 1). The tumor was heterogeneous in density, with areas of low density in the center suggestive of necrosis. The left lobe of the thyroid was normal. Apart from a uterine fibroid, the abdomen and pelvis were normal in appearance.

The patient then underwent a sequential tumor localization study to evaluate the extent of the tumor, and possible thyroid involvement. Fifteen minutes following injection of 3 mCi of ^{201}Tl -chloride, a 10-min planar image of the neck was obtained with a Genesys gamma camera (Milpitas, CA) linked to an ADAC Pegasys computer system (Image 1 in Fig. 2). Twenty minutes after a subsequent injection of 10 mCi [^{99m}Tc]pertechnetate, and with the patient in the same position on the camera table, a 5-min image of the neck was obtained (Image 2). The patient was then injected with 20 mCi of ^{99m}Tc -MIBI (Dupont Co.), and after waiting another 10 min, a 5-min image of the neck was acquired (Image 3). The final ^{99m}Tc -MIBI image was produced by subtracting Image 2 from Image 3 to produce Image 4 (Fig. 2). All images were acquired in a $256 \times 256 \times 8$ matrix. Both the ^{201}Tl -chloride image and the [^{99m}Tc]pertechnetate image showed marked enlargement of the right lobe of the thyroid, with an area of reduced uptake in the center suggestive of necrosis. The ^{99m}Tc -MIBI image showed more clearly the extent of the tumor, and also revealed an area of tumor in a lymph node in the inferolateral aspect of the mass which was not clearly appreciated in the ^{201}Tl -chloride or [^{99m}Tc]pertechnetate images, or on CT scan.

Following an open biopsy, pathological examination revealed the tumor to be a malignant B-cell lymphoma, diffuse large-cell type. In view of the predominate thyroid involvement, the diagnosis of a primary thyroid lymphoma was made, and the patient commenced a combination chemotherapy protocol. After two courses of chemotherapy, and 6 wk after the first study, a repeat tumor localization study was performed, using the same sequence of images with ^{201}Tl -chloride, [^{99m}Tc]pertechnetate and ^{99m}Tc -MIBI as described above. These images showed complete resolution of the thyroid mass (Fig. 3). A CT scan performed at this time also demonstrated no evidence of residual tumor mass.

DISCUSSION

Approximately 4% of all thyroid malignancies are due to thyroid lymphoma, which is usually of B-cell origin

Received Dec. 19, 1991; revision accepted Feb. 20, 1992.
For reprints contact: Andrew M. Scott, FRACP, Nuclear Medicine Service, Memorial Sloan-Kettering Cancer Center, 1275 York Ave., New York, NY 10021.

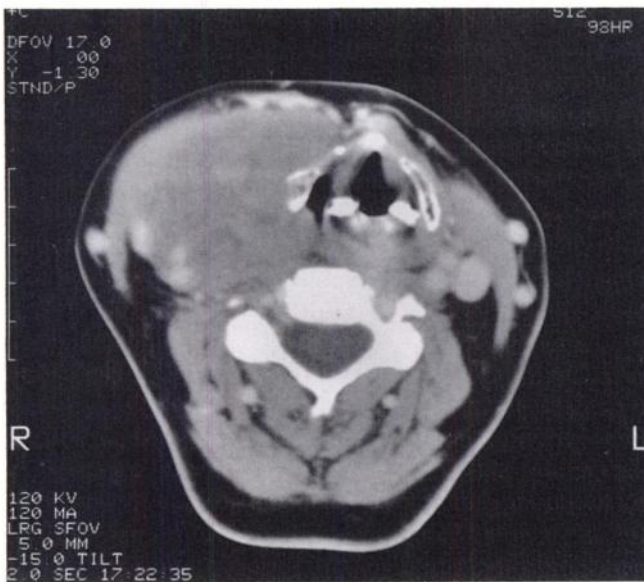


FIGURE 1. CT scan of the neck prior to treatment, showing a 13 × 6 cm mass in the right side of the neck, which appeared to involve or arise from the right lobe of the thyroid gland. A primary lymphoma of cervical lymph nodes could not, however, be excluded.

(11). Women are more frequently affected than men, and most patients are elderly (11–13). The presenting symptom is usually that of a rapidly enlarging goiter, often with symptoms of obstruction (11–13). Primary thyroid lymphoma normally arises in a gland affected by chronic lymphocytic thyroiditis, a disorder which may have a

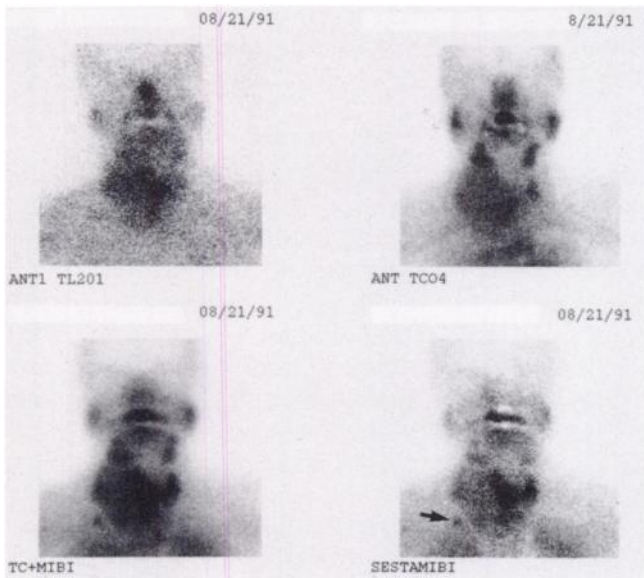


FIGURE 2. Initial ^{201}Tl -chloride and $^{99\text{m}}\text{Tc}$ pertechnetate images show increased uptake in the region of the right lobe of the thyroid gland, extending down to the superior mediastinum. The background-subtracted $^{99\text{m}}\text{Tc}$ -MIBI image, in addition to the above findings, shows a distinct area of uptake (arrow) in the inferolateral aspect of the tumor mass due to lymph node involvement.

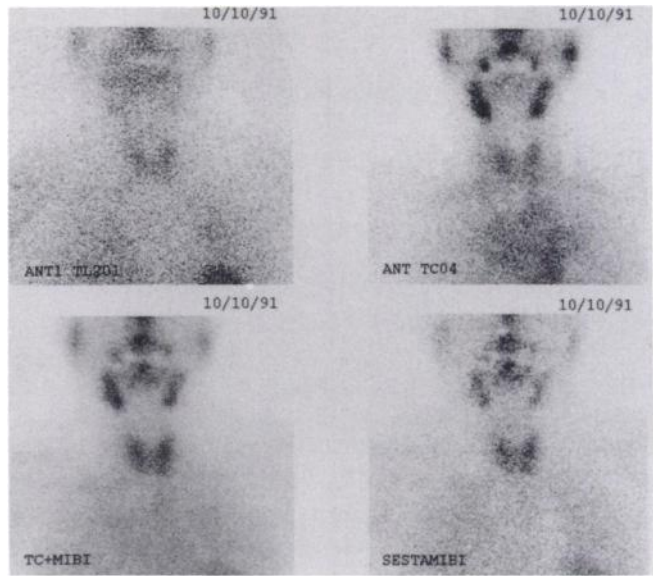


FIGURE 3. Repeat radionuclide imaging with ^{201}Tl -chloride, $^{99\text{m}}\text{Tc}$ pertechnetate and $^{99\text{m}}\text{Tc}$ -MIBI reveal normal uptake in the right neck and thyroid gland consistent with resolution of tumor following chemotherapy.

similar appearance to multinodular change on ultrasound (14). Regional lymph node involvement is a not infrequent finding, as was found in this patient (11). Thyroid function tests are usually normal, apart from elevated autoantibodies indicating prior thyroiditis, as was present in this case (13).

Previous reports have described the use of $^{99\text{m}}\text{Tc}$ -MIBI in benign and malignant tumors of the lung (3,4), mediastinal and pulmonary metastases of thyroid carcinoma (5), parathyroid adenomas (6), brain tumor (7) and in osteosarcoma (8). In this patient, $^{99\text{m}}\text{Tc}$ -MIBI more accurately identified the extent of tumor compared to ^{201}Tl -chloride, and the direct involvement of the thyroid gland was better appreciated in these studies than on the CT scan. The use of serial radionuclide studies also allowed an assessment of tumor response to chemotherapy to be made. Although the use of delayed (2–3 hr) compared to early thallium images has been reported to improve tumor detection in thyroid and lung malignancies (15,16), this has not been demonstrated in other nonlung malignancies (17,18), and the optimal technique in lymphoma is unclear (15,19). We did not perform delayed thallium images, since the purpose of the study was not to differentiate between benign or malignant lesions, but rather to delineate the true extent of the disease, and more particularly assess the degree of thyroid involvement with the disease process. We also wished to perform the studies in as short a time as possible for patient tolerance of the procedure. Nevertheless, the biological and physical characteristics of $^{99\text{m}}\text{Tc}$ -MIBI, as well as the demonstrated tumor uptake in this case, suggest that $^{99\text{m}}\text{Tc}$ -MIBI may be superior to ^{201}Tl -chloride in the assessment of this disease. Technetium- $^{99\text{m}}$ -MIBI also has potential advantages over ^{67}Ga -citrate

in terms of imaging time and image quality, although a direct comparison of these modalities was not performed in this case. Further studies are underway to more accurately define the utility of ^{99m}Tc -MIBI in the initial assessment of lymphoma and in monitoring tumor response to treatment.

ACKNOWLEDGMENT

The authors thank the Dupont Co. in supplying the MIBI kits used in tumor imaging in this patient.

REFERENCES

1. Wackers FJ-Th, Berman DS, Maddahi J, et al. Technetium-99m-hexakis 2-methoxyisobutylisonitrile: human biodistribution, dosimetry, safety, and preliminary comparison to thallium-201 for myocardial perfusion imaging. *J Nucl Med* 1989;30:301-311.
2. West DJ, Najim YC, Mistry R, Clarke SE, Fogelman I, Maisey MN. The localisation of myocardial ischaemia with technetium-99m methoxy isobutyl isonitrile and single photon emission computed tomography. *Br J Radiol* 1989;62:303-313.
3. Hassan IM, Sahweil A, Constantinides C, et al. Uptake and kinetics of Tc-99m-hexakis 2-methoxy isobutyl isonitrile in benign and malignant lesions in the lungs. *Clin Nucl Med* 1989;14:333-340.
4. Muller SP, Reiner C, Paas M, et al. Tc-99m-MIBI and Tl-201 uptake in bronchial carcinoma [Abstract]. *J Nucl Med* 1989;30:845.
5. Muller St, Guth-Taugelides B, Creutzig H. Imaging of malignant tumours with Tc-99m-MIBI SPECT [Abstract]. *J Nucl Med* 1987;28:562.
6. Coakley AJ, Kettle AG, Wells CP, O'Doherty MJ, Collins REC. Tc-99m-sestamibi: a new agent for parathyroid imaging. *Nucl Med Commun* 1989;10:791-794.
7. O'Tuama LA, Packard AB, Treves ST. SPECT imaging of paediatric brain tumor with hexakis (methoxyisobutylisonitrile) technetium (I). *J Nucl Med* 1990;31:2040-2041.
8. Caner B, Kitapci M, Anas T, Erben G, Ugur O, Bekdik C. Increased accumulation of hexakis (2-methoxyisobutylisonitrile) technetium (I) in osteosarcoma and its metastatic lymph nodes. *J Nucl Med* 1991;32:1977-1978.
9. Aktolun C, Bayhan H, Celasun B, Kir MK. Unexpected uptake of technetium-99m hexakis-2-methoxy-isobutylisonitrile in giant lymph node hyperplasia of the mediastinum (Castleman's disease). *Eur J Nucl Med* 1991;18:856-859.
10. Aktolun C, Demirel D, Kir M, Bayhan H, Maden HA. Technetium-99m-MIBI and thallium-201 uptake in pulmonary actinomycosis. *J Nucl Med* 1991;32:1429-1431.
11. Souhami L, Simpson WJ, Carruthers JS. Malignant lymphoma of the thyroid gland. *Int J Rad Oncol Biol Phys* 1980;6:1143-1147.
12. Burke JS, Butler JJ, Fuller LM. Malignant lymphomas of the thyroid. A clinical pathologic study of 35 pts including ultrastructural observations. *Cancer* 1977;39:1587-1602.
13. LiVolsi VA. Pathology of thyroid disease. In: Stephen A. Falk, ed. *Thyroid disease: endocrinology, surgery, nuclear medicine and radiotherapy*. New York: Raven Press; 1990:149-150.
14. Simeone JF, Daniels GH, Mueller PR, et al. High resolution real-time ultrasound of the thyroid. *Radiology* 1982;145:431-435.
15. Ochi H, Sawa H, Fukuda T, et al. Thallium-201-chloride scintigraphy to evaluate benign and/or malignant nodules: usefulness of the delayed scan. *Cancer* 1982;50:236-240.
16. Tonami N, Shuke N, Yokoyama K, et al. Thallium-201 single photon emission computed tomography in the evaluation of suspected lung cancer. *J Nucl Med* 1989;30:997-1004.
17. Kim K, Black K, Marciano J, et al. Thallium-201 SPECT imaging of brain tumours; methods and results. *J Nucl Med* 1990;31:965-969.
18. Tonami N, Yokoyama K, Michigishi T, et al. Thallium-201 single photon emission computed tomograms of double cancers: lung and breast. *Clin Nucl Med* 1989;14:594-596.
19. Hisada K, Tonami N, Miyamae T, et al. Clinical evaluation of tumour imaging with Tl-201 chloride. *Radiology* 1978;129:497-500.