
Clinical Comparison of Technetium-99m-Teboroxime and Thallium-201 Utilizing a Continuous SPECT Imaging Protocol

A.N. Serafini, S. Topchik, H. Jimenez, A. Friden, W.I. Ganz, and G.N. Sfakianakis

Department of Radiology, Division of Nuclear Medicine, University of Miami School of Medicine, and Cedars Medical Center, Miami, Florida

To examine the advantages of a ^{99m}Tc -labeled cardiac perfusion agent, teboroxime or SQ30,217 (Squibb Diagnostics), a prospective study was undertaken comparing it to ^{201}Tl stress testing in 17 patients suspected or known of having coronary artery disease (CAD). All patients were studied utilizing a single-detector SPECT camera with a continuous acquisition imaging protocol. Testing was performed on a treadmill to comparable levels with both agents within a 2-wk period. Concordance between the two studies on a patient by patient basis was seen in 16/17 (94%) patients, and discordance was seen in 1/17 (6%) patients. Comparison of findings between ^{201}Tl and ^{99m}Tc -teboroxime on a segment by segment basis showed concordance in 107/119 (90%) segments, and 12/119 (10%) were discordant. Both examinations independently detected an equal number of normal (77) and abnormal (42) segments. There was no significant difference between the two agents in classifying lesions as ischemic, although there were significant differences between thallium and teboroxime in classifying infarct and infarct/ischemia. Technetium-99m-teboroxime SPECT imaging is a clinically useful method for detecting CAD, with a major advantage being the shorter examination time per individual patient study. The mean total examination time for completion of the ^{99m}Tc -teboroxime study was 2.5 hr versus 4.0 hr for ^{201}Tl .

J Nucl Med 1992; 33:1304–1311

An improved cardiac perfusion agent based on ^{99m}Tc , which has ideal physical characteristics for scintigraphic imaging, would be highly advantageous as an alternative to ^{201}Tl imaging, especially for SPECT. Although ^{201}Tl has had extensive clinical use in the past, its low photon energy (69–83 keV), prolonged half-life (which limits the dose that can be administered) and its availability restrictions have certain limitations in the clinical setting (1).

CardioTec, ^{99m}Tc -labeled teboroxime or SQ30,217 (Squibb Diagnostics), is a new myocardial perfusion imaging agent that has rapid myocardial uptake with high

myocardial extraction (allowing imaging to begin within 2 min) and fast myocardial clearance (thereby requiring a rapid imaging protocol that starts within 2–3 min of injection and must be completed within 10 min). Preliminary reports utilizing ^{99m}Tc -teboroxime and conventional planar and SPECT scintigraphy have shown good correlation with ^{201}Tl scintigraphy and with coronary arteriography (2–11).

This study reports on our experience utilizing a single-detector SPECT camera with a dynamic continuous acquisition imaging protocol. In the continuous acquisition mode, the computer acquires data at each azimuth stop for a predetermined length of time and then continues to acquire data during the movement of the camera to the next azimuth position. This has the advantage of increasing sensitivity 25%–40%, depending on the camera's rotational "deadtime" without increasing the total time of study and is ideally suited for ^{99m}Tc -teboroxime with its rapid uptake and washout. We evaluated the efficacy, ease and practicality of performing ^{99m}Tc -teboroxime exercise studies in comparison to ^{201}Tl exercise studies.

METHODS

Seventeen patients (16 males and 1 female) with suspected or known coronary artery disease (CAD) were studied to assess the clinical efficacy of ^{99m}Tc -teboroxime in patients who were concomitantly being studied with ^{201}Tl stress and redistribution imaging.

The open label study was reviewed and approved by the University of Miami-Cedars Medical Center Investigational Review Board. All patients were 18 yr or older and were enrolled in the study after giving informed consent according to the following criteria. All patients had undergone ^{201}Tl exercise stress and redistribution exams within 2 wk of the ^{99m}Tc -teboroxime exercise and reinjection rest study. All patients underwent maximal symptom-limited exercise testing on a treadmill to comparable levels for both the ^{201}Tl and ^{99m}Tc -teboroxime study. No changes were known to have occurred in the patient's clinical status between the two studies.

At the peak of exercise, patients were injected intravenously with a 3.0–3.5-mCi dose of ^{201}Tl and exercise continued for 1 min. Approximately 5–10 min later, patients were imaged in the supine position with the head in toward the gantry utilizing

Received Dec. 24, 1991; revision accepted Feb. 20, 1992.
For reprints contact: Aldo N. Serafini, MD, University of Miami School of Medicine D-57, 1611 N.W. 12 St., Miami, FL 33136.

a single-headed tomographic camera (ADAC ARC 3000). Images were acquired with a low-energy high-resolution collimator with a 64 × 64 × 16 matrix. Thirty-two views were taken for 40 sec each over a 180° arc from the 45° right anterior oblique (RAO) position to the 45° left posterior oblique (LPO) position in a continuous acquisition mode. A series of transaxial slices were reconstructed with filtered backprojection. In the continuous step-and-shoot acquisition mode, one frame of the study equals the data acquired at each stop plus the data acquired during movement to the next stop. The last frame of the study consists of data acquired at the last azimuth stop for a predetermined length of time plus data acquired for an additional amount of time equal to the time of camera movement from one azimuth position to the next. Therefore, the acquisition duration of each frame in the study is identical. All images were reconstructed utilizing a Butterworth filter with a 0.4 cutoff frequency and a filter order of 5. Redistribution images were obtained 3–4 hr later using the same acquisition and reconstruction parameters. Patients' ECGs and vital signs were monitored before, during and after exercise.

Within a 2-wk period, a similar exercise protocol was performed for ^{99m}Tc-teboroxime imaging. Preadministration ECG, history and vital signs were recorded for each patient.

Teboroxime was supplied in lyophilized form as a single vial kit for reconstitution by the addition of approximately 100 mCi of ^{99m}Tc pertechnetate in 1 ml of 0.9% sodium chloride solution. Following heating in a thermal block or water bath for 15 min, the vial was allowed to cool to room temperature and analyses were performed to determine the percent free pertechnetate and reduced hydrolyzed technetium. Total preparation time, including quality assurance, averaged 40 min. Since the product is stable for approximately 6 hr, the contents could be used to provide both the exercise and rest doses. Our quality assurance testing confirmed a high labeling efficiency, with the average percentage bound being 94% ± 1.99% (Table 1).

Patients were injected with 13.5–26.0 mCi of ^{99m}Tc-teborox-

ime at maximal exercise following the same exercise protocol as in the ²⁰¹Tl study. Immediately after exercise, patients were imaged supine with the same tomographic scanner used in the ²⁰¹Tl study. Images were acquired utilizing a low-energy, high-resolution collimator with a 64 × 64 × 16 matrix. Thirty-two views were taken at 15 sec per view each over a 180° arc scan beginning in the 45° RAO position and ending in the 45° LPO position in a continuous acquisition mode.

Rest imaging was performed 1–2 hr later after a second injection of ^{99m}Tc-teboroxime. The patients were injected at rest after they were positioned supine on the examining table under the detector of the same tomographic camera. The dose range for the reinjection rest study was between 13.8–44.0 mCi. The total amount of ^{99m}Tc-teboroxime injected for both the stress and rest activity per patient did not exceed 60 mCi. Once again, images were acquired with a low-energy, high resolution collimator utilizing a matrix of 64 × 64 × 16. Thirty-two views were taken at 15-sec intervals over a 180° arc from the 45° RAO to the 45° LPO position in a continuous acquisition mode. All images were reconstructed utilizing a Butterworth filter with a 0.4 cutoff frequency and filter order of 5. As in the thallium study, the patients' ECGs and vital signs were monitored before, during and after exercise. All patients were assessed for the presence of any adverse reactions post-stress and rest injection of ^{99m}Tc-teboroxime.

Total examination times were recorded for both studies, including individual stress and rest imaging times for each agent as well as total patient study time for the procedure (Table 2).

Image Interpretation

All ²⁰¹Tl and ^{99m}Tc-teboroxime images were interpreted independently by at least two observers who were blinded to patient data. All stress and rest images were viewed side by side for each patient study with a high-resolution display/viewing station (ADAC-Viewpoint) with the same color code display ("Isocon-tour") for each agent.

The three tomographic views (short-axis, horizontal long-axis and vertical long-axis) were divided into the following myocardial segments:

Short-axis views (four segments): anterior, septal, lateral and inferior/posterior.

Horizontal long-axis views (three segments): apical, septal or anterior/posterior laterals.

Vertical long-axis views (three segments): anterior, apical and posterior myocardial segments.

Each ²⁰¹Tl and ^{99m}Tc-teboroxime study was subdivided into seven comparable myocardial segments. A total of 119 ²⁰¹Tl myocardial segments were compared to a similar number of ^{99m}Tc-teboroxime myocardial segments. Each segment was further categorized as being normal (N) or abnormal (Ab). Abnormal

TABLE 1
Radiopharmaceutical Quality Control (^{99m}Tc-Teboroxime)

| | %Bound | %Free | %Hydrolyzed | Total |
|----------|--------|-------|-------------|--------|
| | 96.93 | 2.70 | 0.37 | 100.00 |
| | 94.59 | 4.54 | 0.87 | 100.00 |
| | 95.04 | 4.68 | 0.28 | 100.00 |
| | 94.52 | 3.87 | 1.61 | 100.00 |
| | 93.04 | 6.52 | 0.44 | 100.00 |
| | 91.68 | 4.17 | 4.15 | 100.00 |
| | 95.51 | 4.26 | 0.23 | 100.00 |
| | 94.94 | 4.27 | 0.79 | 100.00 |
| | 96.16 | 3.58 | 0.26 | 100.00 |
| | 94.99 | 4.35 | 0.66 | 100.00 |
| | 92.80 | 3.90 | 3.30 | 100.00 |
| | 94.76 | 4.85 | 0.39 | 100.00 |
| | 95.03 | 4.36 | 0.61 | 100.00 |
| | 90.46 | 2.37 | 7.18 | 100.00 |
| | 95.40 | 4.48 | 0.12 | 100.00 |
| | 89.56 | 5.92 | 4.52 | 100.00 |
| | 93.17 | 6.37 | 0.47 | 100.00 |
| Average: | 94.03 | 4.42 | 1.54 | 100.00 |
| s.d. | 1.99 | 1.10 | 2.02 | 0.00 |
| C.V.(%) | 2.12 | 24.83 | 130.79 | 0.00 |

TABLE 2
Comparison of Examination Times

| | ²⁰¹ Tl | Teboroxime |
|--------------------------------|-------------------|-------------|
| Exercise and stress image time | 43 min | 17 min |
| Rest image time | 25 min | 8 min |
| Total exam time | 3 hr 55 min | 2 hr 28 min |

segments were further subcategorized as being ischemic (I), infarcted (X), ischemic and infarcted (P) or equivocal (E).

Image Evaluation

Each physician reviewed the ^{99m}Tc -teboroxime and ^{201}Tl images independently from each study and scored the uptake of ^{99m}Tc -teboroxime and ^{201}Tl in individual myocardial segments from 4 to 0 as follows:

Definitely Abnormal—A focal defect in the left ventricular wall or a definite asymmetry in wall uptake showing a substantial difference from a normal site.

Probably Abnormal—A focal defect in the left ventricular wall that was not a normal variant and occupied less than the outline of the left ventricle in one view or contained a definite asymmetry in wall uptake but with less of a difference from a normal site.

Equivocal—A focal defect that was clearly not a normal variant, but also was not definitely abnormal; or asymmetry in left ventricular wall uptake that was less different from normal sites, but somewhat more than that usually assigned to normal variation.

Probably Normal—A slight asymmetry of radioactivity in the left ventricular wall or a focal defect that could be a normal variant (i.e., apical thinning, high septal decrease due to the valve plane, etc.).

Normal—Left ventricular walls are well visualized without significant defects or asymmetries.

After completing the scoring of the individual segments, the reader concluded whether the imaging study was normal or abnormal using the following criteria:

Normal: Characterized by uniform distribution of radioactivity throughout the myocardium with exception of known variants (i.e., decreased radioactivity in the region of the cardiac apex—so called apical thinning).

Abnormal: Indicative of coronary disease—characterized by a significant decrease of radioactivity in the myocardial circumference.

Abnormal studies were further categorized on whether the involved segments were: redistributing (ischemic), fixed (infarcted) or a combination of both (partial redistribution).

Disagreements in the interpretation of the studies were resolved by consensus after review of the discordant studies.

The readers also assessed the acquired images for overall image quality and graded them according to the following guidelines:

Excellent: Low background activity, good contrast, myocardial image well defined.

Good: Moderate background activity, moderate contrast; myocardial image is adequate for diagnosis.

Poor: Excessive background activity, poorly defined myocardial image; not adequate for diagnostic use.

Correlation of Procedures with Supporting Data

The investigators correlated the ^{99m}Tc -teboroxime imaging results with the results of the ^{201}Tl scintigraphic images and determined if the ^{99m}Tc -teboroxime results agreed with the overall

clinical impression at the time of the exam, based upon accepted procedures used in the diagnosis of coronary disease as well as any other available supportive data.

Statistical Analysis

The statistical difference in mean values between the two groups for the paired exercise testing data was analyzed using the Student's t-test and for the concordant/discordant imaging results with the McNemar's chi-square test.

RESULTS

Patient Characteristics

All 17 patients successfully completed both studies. The mean age of the patients enrolled was 61 yr with a range of 46–83 yr. Prior myocardial infarction was present in seven patients for whom a wide variety of medications were being administered. Radiopharmaceutical preparation proved to be of consistently high quality with an average percent bound of 94.0%, percent free technetium 4.4% and percent hydrolyzed technetium 1.5% (Table 1).

Comparison of Exercise Protocol

All patients were able to successfully complete the exercise protocols for both studies without any complications. No patient had any serious adverse reaction as a result of injection of either radiopharmaceutical. The level of exercise achieved, the duration, hemodynamic response and the development of ECG changes or chest pain suggesting ischemia are summarized in Tables 3 and 4.

Paired analysis revealed a trend for the double product (peak heart rate times peak systolic blood pressure) to be slightly higher in the ^{201}Tl group. The other exercise-related variables (chest pain, ST-T segment depression on ECG and total exercise time) were not significantly different (Table 4).

One patient (BF) had discordant symptoms between the ^{201}Tl and ^{99m}Tc -teboroxime exercise studies. Chest pain was experienced by this patient during the ^{201}Tl exercise test but not during the ^{99m}Tc -teboroxime stress test. Electrocardiographic changes during exercise suggestive of ischemia were present in this patient in both studies as well as scintigraphic evidence of CAD.

All remaining patients demonstrated concordant symptoms and ECG findings for both studies. Technetium- ^{99m}Tc -teboroxime examinations could be completed within a shorter imaging time as compared to ^{201}Tl for both stress and rest (Table 2). The mean time for maximum exercise plus imaging was 17 min for stress ^{99m}Tc -teboroxime versus 43 min for stress ^{201}Tl . For rest studies, the mean SPECT imaging time was 8 min for ^{99m}Tc -teboroxime versus 25 min for ^{201}Tl . Total examination time for completion of the ^{99m}Tc -teboroxime study was 2.5 hr versus 4.0 hr for ^{201}Tl . The resulting teboroxime images were considered to be of good to excellent quality in 97% of studies with good correlation with standard SPECT thallium imaging.

TABLE 3
Exercise Parameters

| Patient | ²⁰¹ Tl | | Teboroxime | |
|----------|-------------------|---------------------|----------------|---------------------|
| | Double Product | Exercise Time (min) | Double Product | Exercise Time (min) |
| LE | 29450 | 7.00 | 25500 | 6.15 |
| KR | 32800 | 9.30 | 31920 | 8.21 |
| FM | 22560 | 5.04 | 19680 | 6.42 |
| MB | 15120 | 11.51 | 13910 | 10.59 |
| LL | 25950 | 8.01 | 16640 | 7.50 |
| IL | 36110 | 6.00 | 35650 | 4.53 |
| RP | 16380 | 8.59 | 14950 | 8.02 |
| PM | 27550 | 8.25 | 23970 | 8.51 |
| GP | 26690 | 8.00 | 27540 | 8.12 |
| MH | 22320 | 9.02 | 25020 | 5.44 |
| DD | 28800 | 9.22 | 27540 | 9.00 |
| JL | 27550 | 5.00 | 21920 | 6.04 |
| JS | 28190 | 2.01 | 17000 | 1.28 |
| PV | 23000 | 4.49 | 26640 | 4.17 |
| BF | 23560 | 12.00 | 21280 | 11.50 |
| SM | 23970 | 9.32 | 25020 | 12.48 |
| JC | 27680 | 11.00 | 27840 | 11.00 |
| Average: | 25746 | 7.90 | 23648 | 7.6 |
| s.d. | 5216 | 2.70 | 5941 | 2.9 |
| C.V.(%) | 20.3 | 34.00 | 25.1 | 38.3 |

Since teboroxime has a rapid washout, rest images could be initiated following reinjection as early as 45–60 min after completion of the stress images. SPECT imaging performed at this time was not affected by residual myocardial activity, so patients could have their total procedure completed within 90 min.

Comparison of ^{99m}Tc-Teboroxime and ²⁰¹Tl Myocardial Perfusion Scans

Overall, there was excellent correlation between ^{99m}Tc-teboroxime imaging and thallium scintigraphy for the diagnosis of normal or abnormal myocardial perfusion.

A comparison of findings on a per patient basis between ²⁰¹Tl and ^{99m}Tc-teboroxime in the study group revealed the following: three patients had concordant normal studies both for ²⁰¹Tl and ^{99m}Tc-teboroxime, thirteen patients

demonstrated abnormal findings in both studies and one patient showed discordant findings between the two studies. Concordance between the two studies for either normal or abnormal study was seen in 16/17 patients (94%) and discordance was seen in 1/17 patients (6%).

A total of 119 segments were available for analysis of both agents' ability to detect an abnormality. A comparison between ²⁰¹Tl and ^{99m}Tc-teboroxime on a segment by segment basis demonstrated the following findings: Both agents showed concordance in 107/119 segments (90%) and discordance in 12/119 segments (10%). Overall, in comparing the number of discordant segments when classifying the segments as either normal or abnormal, McNemar's test showed no statistically significant difference between ²⁰¹Tl and ^{99m}Tc-teboroxime (p = 0.7728).

The 12 discordant segments were seen in seven patients and showed no specific predisposition for any segment (Table 5). Further analysis revealed that ²⁰¹Tl scintigraphy showed six abnormal segments in five patients (LE, IL, RP, MH, JL), which were felt to be normal on ^{99m}Tc-teboroxime images. The remaining segments in these patients showed concordant findings with respect to being normal or abnormal. Technetium-99m-teboroxime was abnormal in six segments in three patients (SM, LL and JL) which were felt to be normal in the corresponding thallium segments. Five of the six discordant segments were fixed, nonreperfusing abnormalities in the teboroxime studies. Once again, concordant findings for abnormalities between ²⁰¹Tl and ^{99m}Tc-teboroxime studies were seen in other segments in Patients LL and JL, although in Patient SM, the ^{99m}Tc-teboroxime study was the only study

TABLE 4
Comparison of Exercise Testing in 17 Patients

| | ²⁰¹ Tl | Teboroxime | Paired t-statistic |
|--------------------------------------|-------------------|--------------|--------------------|
| Mean (±s.d.) exercise duration (min) | 7.9 ± 2.7 | 7.6 ± 2.9 | 2.237* |
| Double product (mmHg × heart rate) | 25746 ± 5216 | 23648 ± 5941 | 0.837 |
| Patients with chest pain | 3 | 2 | |
| Patients with ECG changes | 7 | 7 | |

* p < 0.05

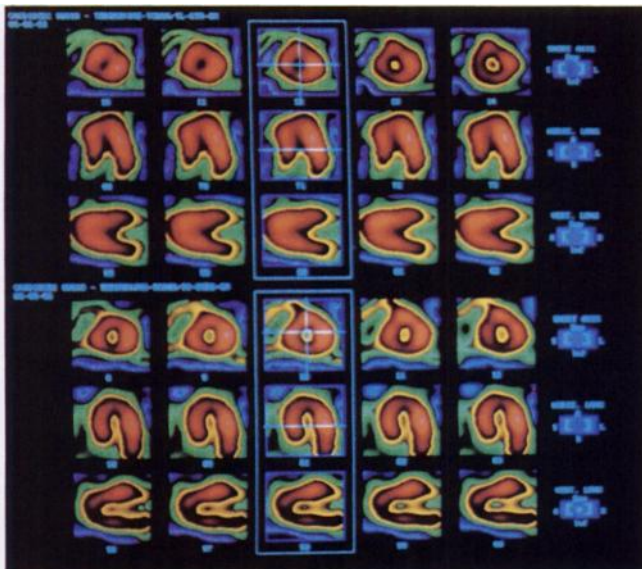


FIGURE 1. Patient PM, a 55-yr-old white male with a history of recent onset of chest pain, was referred for evaluation for CAD. Stress exercise testing performed for both ^{201}Tl and $^{99\text{m}}\text{Tc}$ -teboroxime showed no electrocardiographic or clinical evidence of ischemia. (Top) ^{201}Tl and (bottom) $^{99\text{m}}\text{Tc}$ -teboroxime myocardial perfusion scans. No evidence of ischemia was noted and both scans are felt to be normal. Both studies show good delineation of the normal left ventricular walls, with $^{99\text{m}}\text{Tc}$ -teboroxime showing better delineation of the right ventricle.

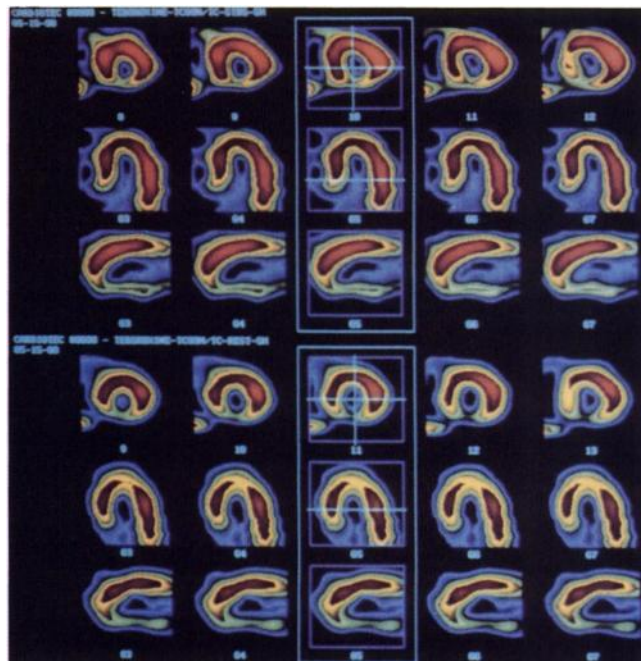


FIGURE 3. Patient IL, a 63-yr-old male with a history of hypertension and hypercholesterolemia, status post-MI and post-bypass graft 9 yr ago, who returned for evaluation. The teboroxime study shows fixed abnormalities in the inferior and posterior wall.

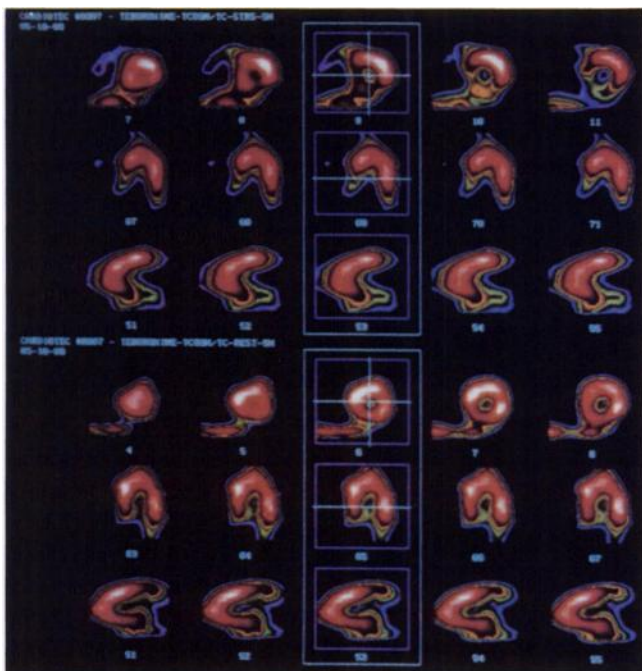


FIGURE 2. Patient LL, a 47-yr-old woman with recent onset of atypical chest pain, was referred for evaluation for CAD. Stress teboroxime study shows ischemia to septum, inferior and posterior walls (top), which fully reperfuses on the reinjected rest teboroxime study (bottom).

showing four abnormal segments. In this patient, who has a history of hypertension and hypercholesterolemia, no history of MI or CAD is known to be present.

Further analysis of the patients on a segment by segment basis demonstrated that both examinations independently detected an equal number of normal (77) and abnormal (42) segments (Table 6). Fourteen of 17 teboroxime studies with a total of 42 segments versus 13/17 thallium studies with a total of 42 segments were abnormal. Although there were an equal number of abnormal segments in the two studies, a difference in the type of abnormal lesions was noted (Table 7). When the abnormal classification is further subdivided into ischemic, infarct, infarct and ischemia and equivocal, some significant differences are revealed. There was no significant difference between ^{201}Tl and $^{99\text{m}}\text{Tc}$ -teboroxime in classifying either study as ischemic ($p = 0.5465$) or equivocal ($p = 0.2482$). In classifying infarct and infarct and ischemic, however, there were significant differences, with $p < 0.001$ in both cases.

Thallium-201 demonstrated 14 ischemic, 8 infarcted, 14 mixed (ischemic plus infarct) and 6 equivocal, while $^{99\text{m}}\text{Tc}$ -teboroxime demonstrated 11 ischemic, 28 infarcted, 0 mixed and 3 equivocal (Table 6). Analysis on a segment by segment basis in the 17 patients for the type of finding (normal, ischemic, infarcted, mixed or equivocal) showed concordance in 88 of 119 segments or 74% (71 were normal, 7 ischemic, 7 infarcted and 3 equivocal), while 31 of 119 or 26% were discordant (Table 7). In the seven patients with discordant (normal versus abnormal) find-

TABLE 5
Discordance

| Patient | Thallium abnormal— Tebo normal | Tebo abnormal— Thallium normal |
|---------|-----------------------------------|--|
| LE | Apex (I), ant (I) | — |
| IL | Septum (E) | — |
| RP | Septum (P) | — |
| MH | Anterior (I) | — |
| JL | Apex (P) | Post (X) |
| LL | — | Post Lat (I) |
| SM | — | Inf (X), Post Lateral (X), Posterior (X), Sep- tum (X) |

ings, ^{201}Tl , showed more ischemic segments (five versus one for teboroxime), while teboroxime showed more segments with fixed defects (five versus zero for ^{201}Tl) (Table 5). One discordant patient study (SM) revealed a persistent defect in four segments on the $^{99\text{m}}\text{Tc}$ -teboroxime study that was not apparent on the ^{201}Tl study.

DISCUSSION

Technetium-99m-teboroxime is a neutral lipophilic agent falling within the class of compounds known as boronic acid adducts of technetium oximes (BATO). These compounds are known to be extracted by the myocardium with a greater efficiency than ^{201}Tl or $^{99\text{m}}\text{Tc}$ -sestamibi over a broad range of flow rates. Technetium-99m-teboroxime has a rapid myocardial uptake with excellent myocardial visualization during the first minutes after injection. The myocardial clearance is also rapid, with biexponential half-time clearances of approximately 5.2 min and 3.8 hr representing approximately 66% and 33% of the myocardial activity. Thus, the first effective half-life for myocardial activity is approximately 11 min (10). The continuous SPECT technique utilized in our protocol starts within 2–3 min following injection and allows for completion of imaging within 8 min for both the stress and rest images. By utilizing a single-detector SPECT camera and a continuous step-and-shoot acquisition imaging protocol, teboroxime demonstrated comparable results to thallium when classifying lesions as normal or abnormal and ischemic or equivocal. The improved count statistics with the higher administered doses demonstrated a marked reduction in study time resulting in improved throughput and better

TABLE 6
Segmental Analysis of Abnormalities Found

| | ^{201}Tl | $^{99\text{m}}\text{Tc}$ -Teboroxime |
|---------------------------|-------------------|--------------------------------------|
| N = Normal | 77 | 77 |
| I = Ischemic | 14 | 11 |
| X = Infarcted | 8 | 28 |
| P = Ischemia + Infarction | 14 | 0 |
| E = Equivocal | 6 | 3 |
| Total | 119 | 119 |

TABLE 7
Comparison of Agreement of Type of Abnormality
 ^{201}Tl and $^{99\text{m}}\text{Tc}$ -Teboroxime According to Segment

| | | $^{99\text{m}}\text{Tc}$ -Teboroxime | | | | | |
|----------|---|--------------------------------------|----|----|---|---|-----|
| | | N | I | X | P | E | |
| Thallium | N | 71 | 1 | 5 | 0 | 0 | 77 |
| | I | 3 | 7 | 4 | 0 | 0 | 14 |
| | X | 0 | 1 | 7 | 0 | 0 | 8 |
| | P | 2 | 2 | 10 | 0 | 0 | 14 |
| | E | 1 | 0 | 2 | 0 | 3 | 6 |
| | | 77 | 11 | 28 | 0 | 3 | 119 |

N = normal; I = ischemic; X = infarct; P = infarct and ischemia; and E = equivocal.

patient acceptance. Discordance between the two agents was seen when classifying lesions as (fixed) infarct or (mixed) infarct plus ischemia. This was particularly common for lesions situated in the inferior or posterior segments. This small subset of discordant segments did not, however, limit the study in detecting abnormalities in other segments in the same patient.

The present study confirms previous reports performed with conventional planar and SPECT imaging regarding the diagnostic utility of $^{99\text{m}}\text{Tc}$ -teboroxime in the detection of CAD (2–15). Our study differs from previous reports in that we used $^{99\text{m}}\text{Tc}$ -teboroxime in conjunction with single-photon tomographic imaging using a continuous step-and-shoot SPECT acquisition protocol. This acquisition method shortens the scanning time while increasing the count statistics. Acquisition of data at each 15-sec azimuth stop as well as during the 4-sec movement of the camera to the next azimuth stop is possible (12).

The study demonstrated good correlation between ^{201}Tl and $^{99\text{m}}\text{Tc}$ -teboroxime in detecting CAD. There was a 94% agreement between studies on a per patient basis and 90% agreement on a per segment basis for showing an abnormality. When concordance between segments was evaluated as to the agreement between the specific type of abnormality (ischemia, mixed, fixed, equivocal), a 74% agreement between the two studies was seen. Both agents detected an equal number of abnormal segments. Fleming et al. recently published their results for 30 patients studied with SPECT utilizing a single-detector camera with a step-and-shoot technique. Those results showed a 77% concordance between thallium and teboroxime for demonstrating the presence or absence of disease (11).

Unlike Hendel et al. who reported findings of rapid resolution of ischemic type defects soon after exercise (2), our study showed a larger percentage of infarct or infarct and ischemic defects with $^{99\text{m}}\text{Tc}$ -teboroxime as compared to thallium. We demonstrated discordance in 12 of 119 segments (10%) between the two agents. This appeared to be more common in hypertensive patients. Kim et al. reported similar findings in a group of patients studied

with a triple-headed detector camera, but with a somewhat higher incidence (15). Ten of 32 vascular territories (31%) were either fixed or got worse between stress and reinjection teboroxime imaging.

Seldin et al. previously reported on the use of this agent in conjunction with planar imaging. They also showed a high percentage of fixed defects at rest with ^{99m}Tc -teboroxime (10). These were felt to be due to severe stenoses of the underlying artery. Other investigators have reported less than a 5% discordance between the two agents (10–14).

The etiology for the variations seen in the results between ^{99m}Tc -teboroxime and ^{201}Tl reported by us and others are not clearly understood (12,15). Various factors need to be considered as possible etiologies, including technical, patient-related, radionuclide characteristics and drug pharmacodynamics. Watson et al. using a phantom showed that significant SPECT reconstruction errors due to self-attenuation could occur with ^{99m}Tc myocardial imaging agents and that these often affected the posterior wall (16). Due to the lower count rate and higher scatter associated with ^{201}Tl , these may not be as easily appreciated in thallium imaging. Furthermore, fixed defects (especially in the inferior or posterior segments) could be artificially caused by computer overcorrection of scatter from the liver, which appears to be present to a greater degree in all technetium cardiac imaging studies.

Finally, that more fixed or fixed plus ischemic defects were seen on ^{99m}Tc -teboroxime images may be explained by the different times of imaging rest between ^{201}Tl and the ^{99m}Tc -teboroxime (2.5 hr versus 4 hr) and the difference in the pharmacokinetics between the two agents. This may be due to a persistence of ischemia in these segments even at rest or due to a faster washout post ischemia in myocardial segments distal to tightly stenotic lesions (17, 18). A rest study with ^{99m}Tc -teboroxime prior to the stress study may reduce the question of fixed defects and is currently being studied at a number of institutions. Similar findings have been reported with ^{99m}Tc -sestamibi studies when same-day stress and reinjected rest studies were compared to ^{201}Tl redistribution (19,20).

Links et al. have recently described the results utilizing computer simulations of the effects of differential (between normal and ischemic tissues) tracer washout during SPECT acquisition (22). By using animal data on ^{99m}Tc -teboroxime washout, they showed potential development of artifacts resembling defects when the imaging time exceeded 6 min when a "true" defect was present in another wall. Since in our study, however, discordance between ^{99m}Tc -teboroxime and ^{201}Tl was equally divided between normal ^{99m}Tc -teboroxime-abnormal ^{201}Tl and the reverse (Table 5), it is highly unlikely that our 8-min imaging protocol produced significant artifacts.

The continuous acquisition protocol used in this study shortens the imaging time and minimizes the effects from patient motion and varying tracer activity. Since the first

half-life of ^{99m}Tc -teboroxime in the myocardium is approximately 11 min and SPECT imaging was started within 2–3 min following injection and completed after 8 min of imaging for both the stress and rest images, no image distortion from varying tracer activity was seen in the studies. Because of the short imaging time and reduced overall total examination time for both stress and rest studies to be completed with the ^{99m}Tc -teboroxime there was faster throughput with excellent patient acceptance.

Since the ^{99m}Tc -teboroxime kit is designed with a long shelf half-life, it is available for immediate reconstitution for both routinely scheduled studies as well as for use on patients in an acute setting. The agent appears particularly promising for evaluation of washout kinetics. Since ^{99m}Tc -teboroxime has a rapid washout, early resting imaging performed 10–15 min following the postexercise image may provide quantitative washout curves similar to those currently obtained with ^{201}Tl . This may add additional important information in patients with underlying CAD and a balanced but reduced coronary circulation.

Our results using a single-detector SPECT camera with a continuous acquisition step-and-shoot protocol are similar to those reported by others using similar or variant techniques (10,11,13–15). The incidence of discordant segments reported by our group and by others is higher than that reported by other investigators and may limit the utility of this agent in assessing viability. Although the reason for this discordance is not clearly understood, differences in tracer kinetics may be a factor. Since published studies using a similar protocol, as well as more recent studies using a shortened acquisition time (21), show no trend toward an increased incidence of fixed defects using teboroxime, further investigation into the ability of teboroxime to distinguish between ischemic and infarcted myocardium is warranted.

ACKNOWLEDGMENT

Study support by Squibb Diagnostic, Princeton, NJ.

REFERENCES

1. Pohost GM, Zir LM, Moore RH et al. Differentiation of transiently ischemic from infarcted myocardium by serial imaging after a single dose of thallium-201. *Circulation* 1977;55:294–302.
2. Hendel RC, McSherry B, Karimeddini O, Leppo JA. Diagnostic value of a new myocardial perfusion agent, teboroxime (SQ30,217), utilizing a rapid planar imaging protocol: preliminary results. *J Am Coll Cardiol* 1990;16: 855–861.
3. Hendel RC, McSherry BA, Leppo JA. Teboroxime and thallium (with reinjection) scintigraphy for the detection of myocardial ischemia and infarction [Abstract]. *Circulation* 1990;82(suppl 3):320.
4. Kim SA, Akers MS, Faber TL, Corbett JR. Dynamic myocardial perfusion imaging with Tc-99m teboroxime in patients: comparisons with thallium-201 and arteriography [Abstract]. *Circulation* 1990;82(suppl 3):321.
5. Pieri P, Yasuda T, Ahmad M, et al. Relationship of changes in coronary artery flow to regional myocardial uptake of ^{99m}Tc teboroxime [Abstract]. *Circulation* 1990;82(suppl 3):320.
6. Gray W, Gewirtz H. ^{99m}Tc -teboroxime versus thallium for myocardial perfusion imaging in the presence of a coronary stenosis [Abstract]. *Circulation* 1990;82(suppl 3):322.

7. Stewart RE, O'Rourke RA, Heyl B, Miller DD. Myocardial Tc-99m teboroxime kinetics following occlusive (supply) and pacing induced (demand) ischemic stress [Abstract]. *Circulation* 1990;82(suppl 3):322.
8. Li QS, Solot G, Frank TL, Wagner HN, Becker LC. Serial rest and dipyridamole tomographic myocardial perfusion studies with rapidly clearing Tc-99m agent SQ 30217 [Abstract]. *J Nucl Med* 1988;92:938.
9. Herzog WR, Nys A, Cianci ML, Katz RJ, Reba RC, Wasserman AG. Planar and tomographic myocardial imaging with SQ 30217, a new technetium labeled agent [Abstract]. *J Am Coll Cardiol* 1989;13(suppl A): 98A.
10. Johnson LL, Seldin DW. Clinical experience with technetium-99m teboroxime, a neutral hypophilic myocardial perfusion imaging agent. *Am J Cardiol* 1990;66:63E-67E.
11. Fleming RM, Kirkeeide RL, Taegtmeyer H, et al. Comparison of technetium-99m teboroxime tomography with automated quantitative coronary arteriography and thallium-201 tomographic imaging. *J Am Coll Cardiol* 1991;17:1297-1302.
12. Serafini AN, Friden A, Topchik S, et al. Tomographic SPECT myocardial imaging in a comparative study between ^{99m}Tc-teboroxime and ²⁰¹Tl [Abstract]. *J Nucl Med* 1991;32:920.
13. Taillefer R, Freeman M, Greenberg D, et al. Detection of coronary artery disease: comparison between ^{99m}Tc-teboroxime and ²⁰¹Tl planar myocardial perfusion imaging (Canadian multicenter clinical trial) [Abstract]. *J Nucl Med* 1991;32:919.
14. Burns RJ, Fung A, Iles S, et al. Exercise Tc-99m teboroxime cardiac SPECT: results of a Canadian multicenter trial [Abstract]. *J Nucl Med* 1991;32:919.
15. Kim AS, Quaife RA, Akers MS, et al. Sequential tomographic myocardial perfusion with Tc-99m teboroxime in patients: comparisons with thallium-201 and arteriography [Abstract]. *J Nucl Med* 1991;32:919.
16. Watson DD, Smith WH, Sobezak M, et al. SPECT reconstruction error due to self-attenuation for Tc-99m myocardial imaging [Abstract]. *J Nucl Med* 1991;3:958.
17. Shea MJ, Wilson RA, de Landsheere CM, et al. Use of short- and long-lived rubidium tracers for the study of transient ischemia. *J Nucl Med* 1987;28:989-997.
18. Goldhaber SZ, Newell JB, Alpert NM, et al. Effect of ischemic-like insult on myocardial thallium-201 accumulation. *Circulation* 1983;67:778-787.
19. Taillefer R, Gagnon A, Gregoire J, et al. Same-day injections of Tc-99m methoxy isobutyl isonitrile (MIBI) for myocardial tomographic imaging: comparison between rest, stress and stress-rest injection sequences [Abstract]. *J Nucl Med* 1988;29:805.
20. Takahashi N, Tamaki N, Ohtani H, et al. Discordance of stress Tc-99m methoxyisobutyl isonitrile and thallium imaging [Abstract]. *Eur J Nucl Med* 1991;18:656.
21. Links JM, Frank TL, Becker LC. Effect of differential tracer washout during SPECT acquisition. *J Nucl Med* 1991;32:2253-2257.
22. Burns RJ, Wright L. Three-minute acquisition of exercise Tc-99m-teboroxime cardiac SPECT with a single-head detector [Abstract]. *J Nucl Med* 1991;32:929-930.