
Identification of Viable Myocardium in Patients with Chronic Coronary Artery Disease: Comparison of Thallium-201 Scintigraphy with Reinjection and Technetium-99m-Methoxyisobutyl Isonitrile

Alberto Cuocolo, Leonardo Pace, Bruno Ricciardelli, Massimo Chiariello, Bruno Trimarco, and Marco Salvatore

Departments of Nuclear Medicine, Internal Medicine and Cardiology, 2nd Medical School, Università degli Studi di Napoli Federico II, and National Cancer Institute, Napoli, Italy

We compared the results of ^{201}Tl reinjection and those of $^{99\text{m}}\text{Tc}$ -methoxyisobutyl isonitrile (MIBI) in identifying viable myocardium in 20 male patients with angiographically proven coronary artery disease (CAD) and left ventricular dysfunction (ejection fraction $30\% \pm 8\%$). All patients had irreversible defects on standard exercise-redistribution thallium imaging. Thallium was reinjected immediately after the redistribution study, and images were reacquired. The patients also underwent stress and rest $^{99\text{m}}\text{Tc}$ -MIBI myocardial scintigraphy (2-day protocol). A total of 300 myocardial regions were analyzed, of which 122 (41%) had irreversible thallium defects on redistribution images before reinjection. Of the 122 myocardial regions with irreversible defects on standard stress-redistribution thallium cardiac imaging, 65 (53%) did not change at reinjection and 57 (47%) demonstrated enhanced uptake of thallium after reinjection. Of the same 122 irreversible defects on stress-redistribution thallium, 100 (82%) appeared as fixed defects and 22 (18%) were reversible on $^{99\text{m}}\text{Tc}$ -MIBI myocardial scintigraphy. These data indicate that ^{201}Tl cardiac imaging with rest reinjection is superior to $^{99\text{m}}\text{Tc}$ -MIBI myocardial scintigraphy in identifying viable myocardium in patients with chronic CAD, suggesting that regions with severe reduction of $^{99\text{m}}\text{Tc}$ -MIBI uptake both on stress and rest images may contain viable myocardium.

J Nucl Med 1992; 33:505-511

In patients with coronary artery disease (CAD), the differentiation between severely ischemic, but potentially viable, myocardium from irreversibly infarcted tissue is clinically important, particularly when revascularization procedures are contemplated. Positron emission tomography

(PET) is now the most accurate method for the assessment of myocardial viability in patients with CAD and impaired left ventricular function (1-3). With PET imaging, it has been demonstrated that exercise-redistribution ^{201}Tl myocardial scintigraphy may underestimate the presence of ischemic but viable myocardium (4-6). Recent observations show that thallium reinjection following exercise-redistribution imaging may detect viable myocardium in regions with irreversible perfusion defects on conventional 3-4-hr delayed images (7-10). In particular, Bonow et al. (10) demonstrated that in myocardial regions with severe irreversible thallium defects on standard exercise-redistribution thallium imaging, thallium reinjection identified as viable or nonviable the same regions as metabolic PET imaging with ^{18}F -fluorodeoxyglucose (FDG). Technetium-99m-MIBI has demonstrated a myocardial uptake proportional to regional coronary blood flow, low lung uptake, and absence of toxicity (11,12). Recently, clinical studies have shown the utility of this new $^{99\text{m}}\text{Tc}$ -labeled compound in the diagnosis of coronary artery disease (13,14), and $^{99\text{m}}\text{Tc}$ -MIBI myocardial scintigraphy has been proposed as an alternative to ^{201}Tl cardiac imaging. However, the role of $^{99\text{m}}\text{Tc}$ -MIBI in the identification of viable myocardium in patients with chronic CAD has not yet been completely clarified. In this study, we directly compared the results of exercise ^{201}Tl scintigraphy with rest reinjection and those of $^{99\text{m}}\text{Tc}$ -MIBI cardiac imaging in patients with chronic CAD and left ventricular dysfunction.

METHODS

Patient Selection

Twenty patients with documented CAD and impaired left ventricular function who showed at least one irreversible perfusion defect on exercise-redistribution ^{201}Tl cardiac imaging were selected for this study. Physical examination, electrocardiography, ^{201}Tl and $^{99\text{m}}\text{Tc}$ -MIBI myocardial scintigraphy, radionuclide an-

Received Aug. 9, 1991; revision accepted Nov. 6, 1991.
For reprints contact: Alberto Cuocolo, MD, Via Posillipo 66, 80123 Napoli, Italy.

giography, and coronary arteriography were performed in all patients. CAD was determined based on significant narrowing ($\geq 50\%$ in luminal diameter) on coronary angiogram. Eleven patients had significant stenosis of all three major coronary vessels and nine patients had significant stenosis of two major coronary vessels. All patients were male, ranging in age from 40 to 76 yr, with a mean of 57 ± 10 yr. The mean left ventricular ejection fraction by radionuclide angiography was $30\% \pm 8\%$, ranging from 15% to 45%. All patients had a clinical history and electrocardiographic findings of previous myocardial infarction. However, no patient had suffered from acute myocardial infarction or unstable angina for the last 6 mo. Antianginal cardiac medications were withdrawn before ^{201}Tl and $^{99\text{m}}\text{Tc}$ -MIBI cardiac imaging in all patients. This protocol was approved by the Institutional Clinical Research Subpanel of our university and all patients gave informed consent.

Thallium-201 Cardiac Imaging Protocol

All patients underwent exercise ^{201}Tl myocardial scintigraphy as previously described (7,15). After an overnight fast, patients underwent bicycle exercise according to a standardized multistage exercise protocol, with continuous monitoring of heart rate and rhythm, blood pressure, and symptoms. At peak exercise, 2 mCi of ^{201}Tl were intravenously injected, and the patient continued to exercise for an additional 60 sec. Within 4 min of injection, planar images were acquired using a small field of view gamma camera (Starcam 300 A/M, General Electric) equipped with a low-energy, all purpose collimator. Data were recorded on a dedicated computer system (General Electric). Images were acquired for 10 min/view in the anterior, 45° left anterior oblique, and left lateral projections (collecting about 400,000 to 500,000 counts/image), using a 128×128 word matrix. Four hours later, redistribution images were obtained in the same predetermined projections for 10 min/view (about 200,000 to 300,000 counts/image). During the period between the exercise and redistribution acquisitions, patients were ambulatory and remained in the fasting state. Immediately after redistribution imaging, all patients received 1 mCi of ^{201}Tl at rest, and a third set of images were reacquired within 10–15 min of the second administered dose using the same imaging protocol.

Technetium-99m-MIBI Cardiac Imaging Protocol

The $^{99\text{m}}\text{Tc}$ -MIBI exercise study was performed in all patients within three days of the ^{201}Tl imaging. The patients were stressed to the same heart rate as in the ^{201}Tl study. At peak exercise, 20 mCi of $^{99\text{m}}\text{Tc}$ -MIBI were intravenously injected, and exercise was continued for another 60 sec. Imaging began 1 hr after stress, using the same gamma camera of the ^{201}Tl study. Data were recorded on a dedicated computer system (General Electric). Images were acquired for 10 min/view in the anterior, 45° left anterior oblique, and left lateral projections, using a 128×128 word matrix. The resting $^{99\text{m}}\text{Tc}$ -MIBI study was performed 24 hr after stress, and imaging was started 1 hr after repeat injection of 20 mCi of $^{99\text{m}}\text{Tc}$ -MIBI. Rest images were obtained in the same predetermined projections for 10 min/view. To minimize gallbladder activity, all patients were instructed to consume a light fatty meal after $^{99\text{m}}\text{Tc}$ -MIBI injection and before imaging.

Data Analysis

The ^{201}Tl exercise, redistribution and reinjection images, and the $^{99\text{m}}\text{Tc}$ -MIBI exercise and rest images were displayed side-by-side on the computer to review and score the distributions. Paired

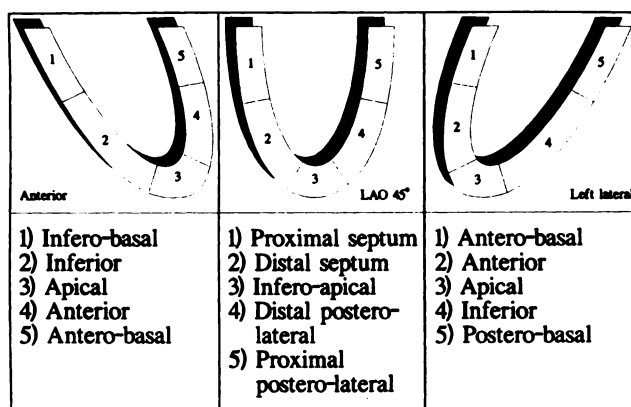


FIGURE 1. Diagram of the standard segmentation scheme used for scoring all thallium and $^{99\text{m}}\text{Tc}$ -MIBI images. The anterior view contains the inferobasal, inferior, apical, anterior and antero-basal segments; the 45° left anterior oblique (LAO 45°) view includes the proximal and distal septum, the inferoapical, and the distal and proximal posterolateral segments; the left lateral view contains the antero-basal, anterior, apical, inferior and postero-basal segments.

images were analyzed: ^{201}Tl exercise versus redistribution, ^{201}Tl exercise versus reinjection, and $^{99\text{m}}\text{Tc}$ -MIBI exercise versus rest. In all cases, the nuclear physician was unaware of which pair was being scored. Analysis of the regional ^{201}Tl and $^{99\text{m}}\text{Tc}$ -MIBI activities was performed by dividing each image into five segments (Fig. 1) for a total of 300 myocardial segments. Thallium-201 and $^{99\text{m}}\text{Tc}$ -MIBI uptake in each segment were scored by consensus by two experienced nuclear physicians using a five-point grading system (0 = absent to 4 = normal), without the knowledge of clinical, electrocardiographic, or angiographic data.

For both the ^{201}Tl and $^{99\text{m}}\text{Tc}$ -MIBI study, each segment was classified as demonstrating normal perfusion, redistribution or a persistent defect by qualitative, visual assessment. A segmental redistribution assignment required an increase of ≥ 1 grade on the redistribution or reinjection images for the ^{201}Tl study and on resting $^{99\text{m}}\text{Tc}$ -MIBI images when compared to the correspondent exercise images. Segmental redistribution was classified as complete normalization when the uptake score became 3 or 4 on ^{201}Tl redistribution or reinjection images and on $^{99\text{m}}\text{Tc}$ -MIBI resting images. Partial normalization was defined when the increase in the uptake score was ≥ 1 , but did not become 3 or 4 on the redistribution or reinjection images nor on the $^{99\text{m}}\text{Tc}$ -MIBI resting images.

Statistical Analysis

Values are reported as mean \pm s.d. Differences between the hemodynamic parameters and the uptake scores recorded under control conditions and during exercise were compared using Student's t-test for paired data. Chi-square analysis was used to assess difference between proportions. Probability values < 0.05 were considered significant.

RESULTS

Exercise Tests

The hemodynamic parameters recorded under control conditions and during exercise are presented in Table 1. There were no significant differences in the exercise test results performed before ^{201}Tl and $^{99\text{m}}\text{Tc}$ -MIBI injection.

TABLE 1
Hemodynamic Parameters Recorded Under Control Conditions and During Exercise Tests

| | ²⁰¹ Tl | ^{99m} Tc-MIBI |
|--|-------------------|------------------------|
| Heart Rate (bpm) | | |
| Control Conditions | 75 ± 10 | 72 ± 12 |
| Peak Exercise | 128 ± 15 | 128 ± 15 |
| Systolic Blood Pressure (mmHg) | | |
| Control Conditions | 131 ± 17 | 129 ± 15 |
| Peak Exercise | 165 ± 25 | 168 ± 19 |
| Diastolic Blood Pressure (mmHg) | | |
| Control Conditions | 82 ± 7 | 82 ± 9 |
| Peak Exercise | 97 ± 10 | 99 ± 11 |
| Duration of Exercise (min) | 7 ± 2 | 7 ± 2 |
| Exercise Workload (watts) | 78 ± 23 | 78 ± 23 |
| Double Product (bpm × mmHg × 10 ³) | 21.1 ± 4 | 21.2 ± 3 |

No adverse clinical or hemodynamic consequences resulted from exercise testing. After injection of ^{99m}Tc-MIBI, four patients (20% of the total) described a transient metallic taste. This was more pronounced after injections made at rest. However, no patient experienced nausea or emesis, and the metallic taste cleared in approximately 5 min.

Segmental Analysis

On the basis of the standard exercise-redistribution thallium studies (Fig. 2), 154 of the 300 myocardial segments (51%) were considered normal and 24 (8%) had perfusion defects during exercise that were reversible. The remaining 122 myocardial segments (41% of the total) had thallium defects during exercise that were irreversible on the redistribution study. The analysis of the thallium reinjection studies (Fig. 2) showed 154 (51% of the total) normal myocardial segments, 81 (27%) with perfusion defects during exercise that were reversible ($p < 0.001$ compared to standard exercise-redistribution thallium imaging), and 65 (22%) irreversible perfusion defects ($p < 0.001$ compared to standard exercise-redistribution thallium imaging).

On the basis of the exercise-rest ^{99m}Tc-MIBI studies (Fig. 2), 154 of the 300 myocardial segments (51%) were considered normal, 43 (15%) had perfusion defects during

TABLE 2
Mean Regional Uptake Score on ²⁰¹Tl and Rest ^{99m}Tc-MIBI Cardiac Imaging

| | Mean Regional Uptake Score | |
|----------------------------------|----------------------------|---------------------------------|
| | Total segments (n = 300) | All perfusion defects (n = 146) |
| ²⁰¹ Tl exercise | 2.3 ± 1.4 | 0.97 ± 0.71 |
| ^{99m} Tc-MIBI exercise | 2.3 ± 1.4 | 0.97 ± 0.82 |
| ²⁰¹ Tl redistribution | 2.4 ± 1.4 [†] | 1.2 ± 0.9 [†] |
| ²⁰¹ Tl reinjection | 2.8 ± 1.2 | 1.9 ± 1.2 |
| ^{99m} Tc-MIBI rest | 2.5 ± 1.4 [†] | 1.4 ± 1.2 [†] |

[†] p < 0.01 versus ²⁰¹Tl reinjection uptake score.
[†] p < 0.01 versus ²⁰¹Tl redistribution uptake score.

exercise that were reversible on the rest study ($p < 0.001$ compared to both standard exercise-redistribution and reinjection thallium imaging). The remaining 103 myocardial segments (34% of the total) had perfusion defects during exercise that were irreversible on the rest study ($p < 0.001$ compared to both standard exercise-redistribution and reinjection thallium imaging).

To further analyze the differences between ²⁰¹Tl and ^{99m}Tc-MIBI cardiac imaging, we compared the regional uptake score on the ²⁰¹Tl exercise, redistribution, and reinjection images and on the ^{99m}Tc-MIBI exercise and rest images (Table 2). In particular, ²⁰¹Tl and ^{99m}Tc-MIBI exercise uptake scores were not statistically different both in total myocardial segments and in all regions with perfusion defects. On the other hand, the ²⁰¹Tl reinjection uptake score was significantly higher than the ²⁰¹Tl redistribution and resting ^{99m}Tc-MIBI uptake score, both in total segments and in all regions with perfusion defects. Moreover, the resting ^{99m}Tc-MIBI uptake score was significantly higher than that of ²⁰¹Tl redistribution in myocardial segments with perfusion defects (Table 2).

Evidence for Viable Myocardium in Irreversible Thallium Defects

The results of thallium reinjection in the 122 myocardial segments with irreversible thallium defects on redistribu-

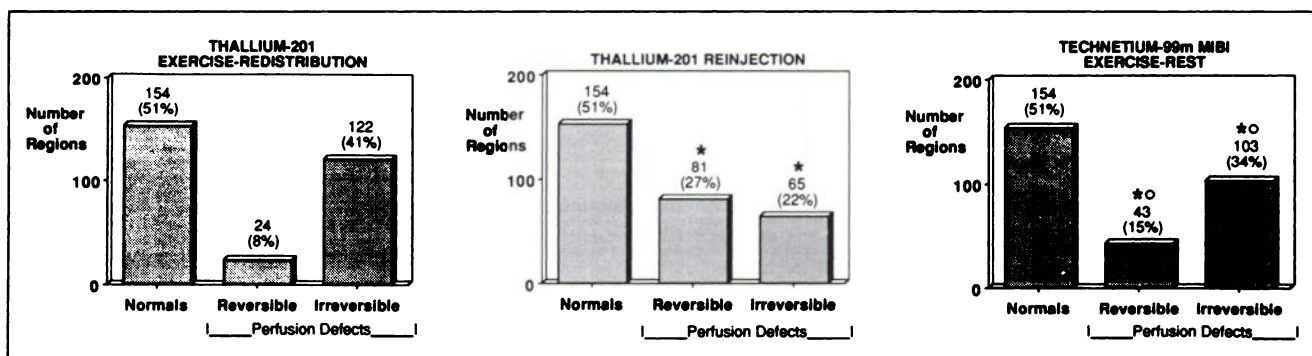


FIGURE 2. Segmental analysis of myocardial perfusion on ²⁰¹Tl exercise-redistribution, ²⁰¹Tl reinjection, and ^{99m}Tc-MIBI exercise-rest myocardial scintigraphy. * $p < 0.001$ when thallium reinjection and ^{99m}Tc-MIBI are compared to standard exercise-redistribution thallium myocardial scintigraphy. ° $p < 0.001$ when ^{99m}Tc-MIBI is compared to thallium reinjection.

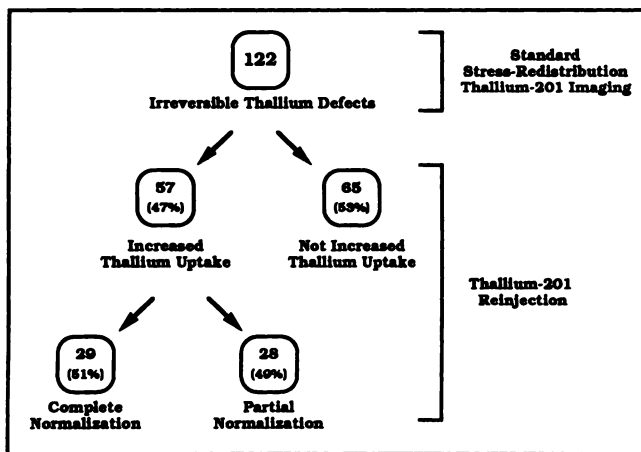


FIGURE 3. Nomogram of thallium uptake after rest reinjection in 122 myocardial segments with irreversible thallium perfusion defects on redistribution imaging.

tion images are presented in Figure 3. Increased thallium activity after thallium reinjection was evident in 57 of the 122 segments (47%). In particular, of these 57 segments with enhanced thallium uptake, 29 (51%) showed complete normalization and 28 (49%) had partial normalization after thallium reinjection. The remaining 65 segments (53%) did not change after reinjection.

The results of the ^{99m}Tc -MIBI exercise-rest studies in the same 122 myocardial segments with irreversible thallium defects on redistribution imaging are shown in Figure 4. Twenty-two of the segments (18%) appeared as reversible perfusion defects on the ^{99m}Tc -MIBI stress-rest myocardial scintigraphy ($p < 0.001$ compared to thallium reinjection). In particular, of these latter 22 segments, 13 (59%) showed complete normalization and 9 (41%) had partial normalization on resting ^{99m}Tc -MIBI imaging. The remaining 100 segments (82%) were classified as irreversible defects on the ^{99m}Tc -MIBI studies ($p < 0.001$ compared to thallium reinjection).

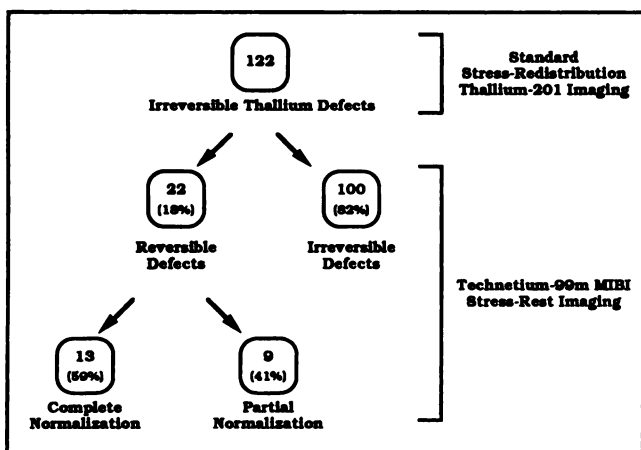


FIGURE 4. Nomogram of ^{99m}Tc -MIBI stress-rest cardiac imaging in 122 myocardial segments with irreversible thallium perfusion defects on redistribution imaging.

A comparison of regional uptake score of ^{201}Tl and ^{99m}Tc -MIBI cardiac imaging in the 122 myocardial segments with irreversible perfusion defects on standard exercise-redistribution thallium study is shown in Table 3. In particular, the mean uptake score was not different between ^{201}Tl exercise and ^{99m}Tc -MIBI exercise, while the ^{201}Tl reinjection uptake score was significantly higher than the resting ^{99m}Tc -MIBI uptake score. Furthermore, the improvement in uptake score with ^{201}Tl reinjection (expressed as thallium reinjection score – thallium exercise score) was significantly higher than that with the resting ^{99m}Tc -MIBI (expressed as MIBI rest score – MIBI exercise score) (Table 3).

Two representative cases of discordance of thallium reinjection and ^{99m}Tc -MIBI data are shown in Figures 5 and 6.

DISCUSSION

Severely ischemic or hibernating myocardium may induce left ventricular dysfunction at rest in many patients with CAD (16–18). It has been demonstrated that revascularization interventions may determine an improvement in left ventricular function in the affected regions when perfusion is restored (3,19). Therefore, the distinction between severely ischemic, but potentially viable, myocardium from myocardial fibrosis is clinically important, especially when revascularization procedures for myocardial salvage are contemplated.

The conventional imaging techniques are often inaccurate in differentiating ischemic but viable myocardium from irreversibly infarcted tissue (10). Previous studies demonstrate that in some patients with irreversible perfusion defects on exercise-redistribution ^{201}Tl imaging after revascularization normal thallium uptake and improved left ventricular function at rest may be observed (20–21). These observations suggest that standard exercise-redistribution ^{201}Tl cardiac imaging may underestimate the presence of ischemic but still viable myocardium because of

TABLE 3
Mean Regional Uptake Score on ^{201}Tl and ^{99m}Tc -MIBI in 122 Myocardial Segments with Irreversible Perfusion Defects on Thallium Redistribution Imaging

| | Mean Regional Uptake Score |
|--|------------------------------|
| ^{201}Tl exercise | 0.94 ± 0.71 |
| ^{99m}Tc -MIBI exercise | 0.93 ± 0.81 |
| ^{201}Tl reinjection | 1.7 ± 1.1 |
| ^{99m}Tc -MIBI rest | 1.2 ± 1.0 |
| Δ Score ^{201}Tl | 0.72 ± 0.87 |
| Δ Score ^{99m}Tc -MIBI | 0.27 ± 0.25 [†] |

[†] Δ Score ^{201}Tl indicates change of thallium uptake after reinjection (expressed as thallium reinjection score—thallium exercise score); Δ Score ^{99m}Tc -MIBI indicates change in MIBI uptake at rest (expressed as MIBI rest score—MIBI exercise score).

[†] $p < 0.01$ versus ^{201}Tl reinjection and versus Δ Score ^{201}Tl , respectively.

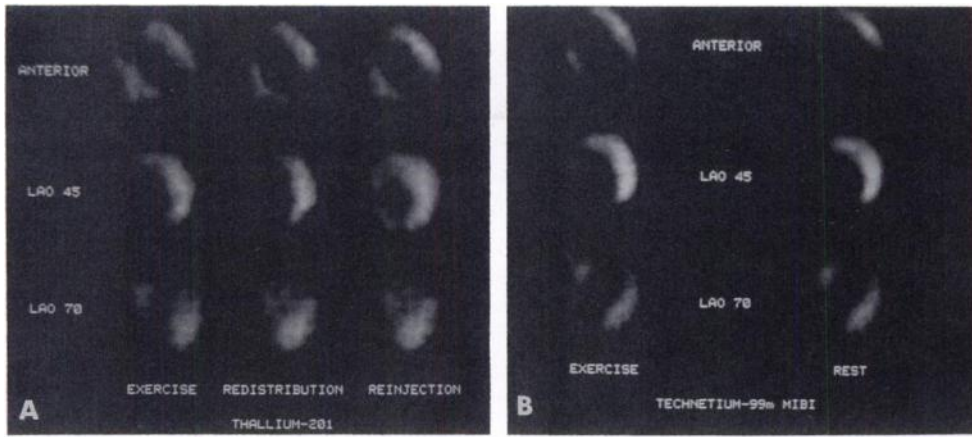


FIGURE 5. Cardiac imaging showing discordance of thallium reinjection and ^{99m}Tc -MIBI data in one patient. (A) Standard ^{201}Tl exercise-redistribution study demonstrates irreversible perfusion defects involving the apical, septal and anterior regions. Thallium reinjection shows partial normalization in the septal region. (B) Exercise-rest ^{99m}Tc -MIBI study demonstrates irreversible perfusion defects involving the apical, septal and anterior regions. LAO 45= 45° left anterior oblique view; LAO 70= 70° left anterior oblique view.

the limitation of the persistent perfusion defects on 3–4-hr delayed images as a marker of nonviable myocardium. On the other hand, PET imaging represents the most accurate technique for the assessment of myocardial viability in patients with CAD and impaired left ventricular function (1–3). It has been demonstrated that 38%–47% of myocardial regions with irreversible perfusion defects on exercise-redistribution ^{201}Tl scintigraphy are metabolically active, and hence viable, with PET (4–6). However, recent studies show that reinjection of ^{201}Tl at rest, immediately after redistribution imaging, may accurately identify viable myocardium by demonstrating thallium uptake in regions with apparently irreversible defects (7–10). In particular, Bonow et al. (10) demonstrated that in myocardial regions with severe thallium defects on standard exercise-redistribution thallium imaging, thallium reinjection identifies as viable or nonviable the same regions as metabolic PET imaging with ^{18}F -FDG.

Although ^{201}Tl has excellent physiologic characteristics for imaging myocardial perfusion, its low energy (68 to 80

keV) is suboptimal for scintillation camera imaging, and its relatively long half-life (73 hr) results in suboptimal radiation dosimetry (22). To circumvent these limitations, new myocardial perfusion agents, labeled with ^{99m}Tc , have been recently developed (23). Myocardial perfusion studies with ^{99m}Tc isonitriles, particularly ^{99m}Tc -MIBI, have clear advantages over ^{201}Tl , including onsite availability, shorter acquisition times, and higher quality images (24).

Technetium-99m-MIBI has demonstrated a myocardial uptake proportional to regional coronary blood flow, low lung uptake, and absence of toxicity (11,12). Recently, clinical studies have shown the utility of this ^{99m}Tc -labeled compound in the diagnosis of CAD (13,14), and ^{99m}Tc -MIBI myocardial scintigraphy has been proposed as an alternative to ^{201}Tl cardiac imaging. With respect to the assessment of myocardial viability, previous papers demonstrated excellent agreement between standard exercise-redistribution ^{201}Tl and exercise-rest ^{99m}Tc -MIBI myocardial scintigraphy (13,25). With a two-day protocol, exact segmental agreement for normal, reversible and nonre-

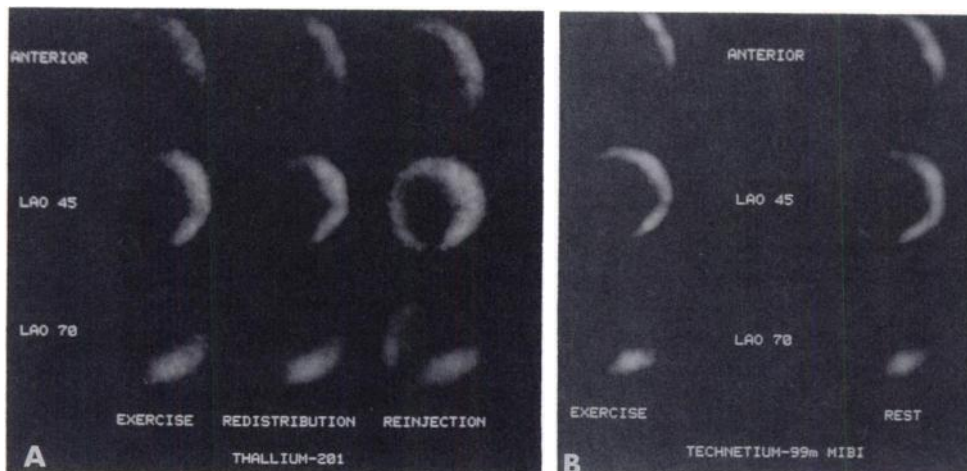


FIGURE 6. Cardiac imaging showing discordance of thallium reinjection and ^{99m}Tc -MIBI data in another patient. (A) Standard ^{201}Tl exercise-redistribution study demonstrates irreversible perfusion defects involving the inferior, septal, anterior and apical regions. Thallium reinjection results in enhanced thallium uptake in the septal and anterior regions. (B) Exercise-rest ^{99m}Tc -MIBI study demonstrates partially reversible perfusion defect of the anterior region and irreversible perfusion defects involving the inferior, septal and apical regions. LAO 45= 45° left anterior oblique view; LAO 70= 70° left anterior oblique view.

versible segments was observed in 92% of the total analyzed myocardial segments (22). In addition, evidence of irreversible defects with ^{99m}Tc -MIBI was seen in only 1% of patients with reversible defects with ^{201}Tl (22). However, these comparisons have been made only with standard exercise-redistribution thallium imaging protocols. Thus, the precise role of ^{99m}Tc -MIBI in the identification of viable myocardium in patients with chronic CAD has not yet been completely clarified.

This study directly compares the results of exercise ^{201}Tl scintigraphy with rest reinjection and those of stress-rest ^{99m}Tc -MIBI cardiac imaging for the identification of viable myocardium in patients with chronic CAD and left ventricular dysfunction. Our results indicate that in myocardial segments with irreversible perfusion defects on standard exercise-redistribution imaging, thallium reinjection provides information regarding myocardial viability that is superior to that provided by exercise-rest ^{99m}Tc -MIBI myocardial scintigraphy. Similar to the findings of previously published series (7-10), we identified enhanced thallium uptake after reinjection in 47% of segments demonstrating irreversible thallium defects on redistribution images. The results with exercise-rest ^{99m}Tc -MIBI cardiac imaging in the same myocardial segments showing irreversible perfusion defects on standard exercise-redistribution thallium imaging were significantly different: only 18% of these regions were identified as viable, while 82% of them appeared as irreversible perfusion defects. As further evidence of the differences between thallium reinjection and ^{99m}Tc -MIBI myocardial scintigraphy in identifying viable myocardium, the improvement of ^{99m}Tc -MIBI regional uptake score after rest injection (expressed as rest uptake score - exercise uptake score) was significantly lower than that of ^{201}Tl after reinjection (expressed as reinjection uptake score - exercise uptake score). Thus, ^{99m}Tc -MIBI identified as viable less myocardial segments than thallium reinjection.

Although previous observations (26,27) suggest that ^{99m}Tc -MIBI permits detection of coronary occlusion at rest, its relation to markers of potential viability in patients with CAD is less clear. Recently, Rocco and coworkers (28) compared ^{99m}Tc -MIBI uptake on a regional basis to left ventricular wall motion in patients with chronic CAD. The results of their study demonstrated that some myocardial regions with reduced perfusion at rest can have viability as evidenced by retained contraction. These authors hypothesized that some regions of reduced resting ^{99m}Tc -MIBI uptake may contain viable but abnormally perfused myocardium. In addition, more recent preliminary observations (29) showed that resting SPECT ^{99m}Tc -MIBI cardiac imaging underestimated viable myocardium in patients with chronic CAD and left ventricular dysfunction compared to metabolic FDG imaging with PET. The results of the present study support this hypothesis, demonstrating that regions with severe reduction of ^{99m}Tc -MIBI uptake both on stress and rest images show enhanced

thallium uptake after reinjection and thus may contain viable myocardium. Moreover, although ^{201}Tl and ^{99m}Tc -MIBI uptake score were similar on the exercise images, both in total segments and in all segments with perfusion defects, a statistically significant difference was found in uptake scores when ^{201}Tl reinjection was compared to resting ^{99m}Tc -MIBI images. In particular, the resting ^{99m}Tc -MIBI uptake score was significantly lower than the ^{201}Tl reinjection uptake score. This suggests that rest injection of ^{99m}Tc -MIBI and reinjection of ^{201}Tl are not equivalent. On the other hand, it has been recently demonstrated that reinjection of thallium immediately after standard exercise-redistribution cardiac imaging is not the same as the rest-reinjection thallium study (30).

There are limitations of the present study on identifying viable myocardium. Our data were obtained in patients with chronic CAD and, thus, may not apply to the evaluation of patients with acute ischemic syndromes, especially those patients undergoing thrombolytic therapy or revascularization procedures in whom the distinction between stunned and necrotic myocardium may be an important clinical issue. Our series also consisted of a relatively small number of patients, and, given this sample size, conclusions regarding the overall efficacy of ^{99m}Tc -MIBI cardiac imaging compared with thallium reinjection in predicting improvement in regional and global ventricular function after revascularization require further study in a larger series. Another limitation of this study is the use of planar acquisition techniques. Data that assess the potential role of ^{99m}Tc -MIBI with SPECT compared to thallium reinjection are clearly required. Finally, the data analysis performed in the present study was based on qualitative segmental scoring. Comparison of quantitative analysis as well as the potential incremental value of such analysis must be addressed in future studies.

Our analysis involved a wide range of ventricular dysfunctions and a large number of myocardial segments with a variety of thallium perfusion defects. Our findings demonstrate that thallium scintigraphy with reinjection is superior to ^{99m}Tc -MIBI cardiac imaging in identifying viable myocardium in patients with chronic CAD and left ventricular dysfunction. These data suggest that myocardial regions with severe reduction of ^{99m}Tc -MIBI uptake both at stress and rest images may contain viable myocardium and such reduced perfusion should not necessarily be considered evidence of myocardial fibrosis. Technetium- ^{99m}Tc -MIBI appears to be primarily a perfusion and not a viability tracer and, therefore, inferences regarding myocardial viability based on qualitative analysis of regional ^{99m}Tc -MIBI uptake on planar images should be made with caution.

ACKNOWLEDGMENTS

The authors thank Antonio Nappi, MD and Emanuele Nicolai, MD for technical assistance for performing the ^{201}Tl and ^{99m}Tc -MIBI studies. Supported in part by a grant from the Italian

REFERENCES

- Schelbert HR, Phelps ME, Hoffman E, Huang SC, Kuhl DE. Regional myocardial blood flow, metabolism, and function assessed noninvasively with positron emission tomography. *Am J Cardiol* 1980;80:1269-1277.
- Marshall RC, Tillisch JH, Phelps ME, et al. Identification and differentiation of resting myocardial ischemia and infarction in man with positron computed tomography, F-18-labeled fluorodeoxyglucose and N-13 ammonia. *Circulation* 1983;67:766-778.
- Tillisch JH, Brunken R, Marshall R, et al. Reversibility of cardiac wall motion abnormalities predicted by positron emission tomography. *N Engl J Med* 1986;314:884-888.
- Brunken R, Schwaiger M, Grover-McKay M, Phelps ME, Tillisch J, Schelbert HR. Positron emission tomography detects tissue metabolic activity in myocardial segments with persistent thallium perfusion defects. *J Am Coll Cardiol* 1987;10:557-567.
- Tamaki N, Yonekura Y, Yamashita K, et al. SPECT thallium-201 tomography and positron tomography using N-13 ammonia and F-18 fluorodeoxyglucose in coronary artery disease. *Am J Cardiac Imaging* 1989;3:3-9.
- Brunken RC, Kottou S, Nienaber CA, et al. PET detection of viable tissue in myocardial segments with persistent defects at Tl-201 SPECT. *Radiology* 1989;65:65-73.
- Rocco TP, Dilsizian V, McKusick KA, Fischman AJ, Boucher CA, Strauss HW. Comparison of thallium redistribution with rest "reinjection" imaging for the detection of viable myocardium. *Am J Cardiol* 1990;66:158-163.
- Dilsizian V, Rocco TP, Freedman NMT, Leon MB, Bonow RO. Enhanced detection of ischemic but viable myocardium by the reinjection of thallium after stress-redistribution imaging. *N Engl J Med* 1990;323:141-146.
- Tamaki N, Ohtani H, Yonekura Y, et al. Significance of fill-in after thallium-201 reinjection following delayed imaging: comparison with regional wall motion and angiographic findings. *J Nucl Med* 1990;31:1617-1623.
- Bonow RO, Dilsizian V, Cuocolo A, Bacharach SL. Identification of viable myocardium in patients with chronic coronary artery disease and left ventricular dysfunction. Comparison of thallium scintigraphy with reinjection and PET imaging with F-18 fluorodeoxyglucose. *Circulation* 1991;83:26-37.
- Okada RD, Glover D, Gaffney T, Williams S. Myocardial kinetics of technetium-99m-hexakis-2-methoxy-2-methylpropylisotrile. *Circulation* 1988;77:491-498.
- Li QS, Frank TL, Franceschi D, Wagner HN, Becker LC. Technetium-99m-methoxyisobutyl isonitrile (RP30) for quantification of myocardial ischemia and reperfusion in dogs. *J Nucl Med* 1988;29:1539-1548.
- Kiat H, Maddahi J, Roy LT, et al. Comparison of technetium-99m methoxyisobutyl isonitrile and thallium-201 for evaluation of coronary artery disease by planar and tomographic methods. *Am Heart J* 1989;117:1-11.
- Kahn JK, McGhie I, Akers MS, et al. Quantitative rotational tomography with Tl-201 and Tc-99m 2-methoxy-isobutyl-isonitrile. A direct comparison in normal individuals and patients with coronary artery disease. *Circulation* 1989;79:1282-1293.
- Cuocolo A, Esposito S, Acampora C, Squame G. Diagnosis of coronary artery disease in hypertensive patients. Comparison of exercise radionuclide ventriculography and thallium-201 myocardial scintigraphy. *Radiol Med* 1988;75:160-165.
- Rahimtoola SH. Coronary bypass surgery for chronic angina—1981: a perspective. *Circulation* 1982;65:225-241.
- Braunwald E, Rutheford JD. Reversible ischemic left ventricular dysfunction: evidence for "hibernating" myocardium. *J Am Coll Cardiol* 1986;8:1467-1470.
- Rahimtoola SH. The hibernating myocardium. *Am Heart J* 1989;117:211-215.
- Dilsizian V, Bonow RO, Cannon RO, et al. The effect of coronary artery bypass grafting on left ventricular systolic function at rest: evidence for preoperative subclinical myocardial ischemia. *Am J Cardiol* 1988;61:1248-1254.
- Brundage DH, Massie BM, Botvinick EH. Improved regional ventricular function after successful surgical revascularization. *J Am Coll Cardiol* 1984;3:902-908.
- Rozanski A, Berman DS, Gray R, et al. Use of thallium-201 redistribution scintigraphy in the preoperative differentiation of reversible myocardial asynergy. *Circulation* 1981;64:936-944.
- Berman DS. Technetium-99m myocardial perfusion imaging agents and their relation to thallium-201. *Am J Cardiol* 1990;66:1E-4E.
- Jones AG, Davison A, Abrams MJ, et al. Biological studies of a new class of technetium complexes: the hexakis(alkylisotrile) technetium(I) cations. *Int J Nucl Biol* 1984;11:225-234.
- Jones RH, Borges-Neto S, Potts J. Simultaneous measurement of myocardial perfusion and ventricular function during exercise from a single injection of technetium-99m sestamibi in coronary artery disease. *Am J Cardiol* 1990;66:68E-71E.
- Iskandrian AS, Heo J, Kong B, Lyons E, Marsch S. Use of technetium-99m isonitrile (RP-30A) in assessing left ventricular perfusion and function at rest and during exercise in coronary artery disease, and comparison with coronary arteriography and exercise thallium-201 SPECT imaging. *Am J Cardiol* 1989;64:270-275.
- Boucher CA. Detection of myocardial infarction using technetium-99m sestamibi imaging at rest. *Am J Cardiol* 1990;66:32E-35E.
- Dilsizian V, Rocco TP, Strauss HW, Boucher CA. Technetium-99m isonitrile myocardial uptake at rest. I. Relation to severity of coronary artery stenosis. *J Am Coll Cardiol* 1989;14:1673-1677.
- Rocco TP, Dilsizian V, Strauss HW, Boucher CA. Technetium-99m isonitrile myocardial uptake at rest. II. Relation to clinical markers of potential viability. *J Am Coll Cardiol* 1989;14:1678-1684.
- Altehofer C, Doerr R, Buell U, et al. Glucose uptake in resting myocardial perfusion defects and wall motion abnormality: a combined quantitated Tc-99m MIBI SPECT/F-18 DOG PET study in patients [Abstract]. *J Nucl Med* 1991;32:1037.
- Dilsizian V, Freedman NMT, Smeltzer WR, Quyyumi AA, Bonow RO. Reinjection of thallium after stress-redistribution imaging is not the same as rest injected thallium study [Abstract]. *J Am Coll Cardiol* 1991;17:78A.

Editor's Note: A companion editorial to this article by Bonow and Dilsizian will appear in the May issue of the *Journal*.