

# Bone Scintigraphy in Preschool Children with Lower Extremity Pain of Unknown Origin

Emanuela E. Englaro, Michael J. Gelfand, and Harriet J. Paltiel

*Department of Radiology, Children's Hospital Medical Center, Cincinnati, Ohio; Radioisotope Laboratory, University of Cincinnati, Cincinnati, Ohio; Istituto di Medicina Nucleare, Ospedale S. Maria della Misericordia, Udine, Italy*

Small children often cannot describe the location of bone pain for parents or physicians. Bone scans were performed in 56 children under five years of age with lower extremity pain and/or gait abnormalities of unknown etiology. Patients with fever, and those known to have infection, child abuse, malignancy, and/or radiographic abnormalities were excluded. Thirty patients had abnormal bone scans. Abnormalities included evidence of hip synovitis (4), femoral head avascularity (2), various proximal femoral abnormalities (3), knee synovitis (3), toddler's fracture (1), various tibial or fibular abnormalities (4), and various abnormalities of the tarsal bones (16). Tarsal bone abnormalities included four with abnormal calcaneal uptake and nine with abnormal uptake in or adjacent to the cuboid bone. Correlative imaging studies were available for 26 sites, and focal bone findings were noted at only five locations. Tarsal bone abnormalities accounted for over half of the scintigraphic abnormalities in these preschool children with gait abnormalities. Abnormal uptake in or adjacent to the cuboid bone was common and probably represented stress injury.

**J Nucl Med 1992; 33:351-354**

The preschool child with a limp is frequently unable to describe the location and nature of the pain. If the gait abnormality is secondary to trauma, the injury may not have been witnessed by an adult. As a result, the historical information available to the clinician is limited and physical examination may not elucidate the site of pathology.

Bone scintigraphy has been used in children with occult gait disturbances and normal radiographs (1,2). In order to determine the utility of bone scintigraphy in preschool children, we reviewed bone scans performed in children of this age group who presented with lower extremity pain or gait abnormalities.

## MATERIALS AND METHODS

We reviewed the bone scans of all preschool children at our hospital who presented between August 1988 and May 1990 with

limp, refusal to walk and/or lower extremity pain. Children with fever, neoplasm, and known child abuse were excluded, as were those who had abnormal radiographs of the lower extremities prior to scintigraphy. The final study group included 56 children under 5 yr of age (range: 1 yr 2 mo to 4 yr 10 mo; mean 3 yr 3 mo). Fifteen girls and 41 boys were studied. The most frequent symptom in the study group was limping, sometimes with pain in the lower extremities. Localized swelling was occasionally present. Patients who were able to describe the site of their pain stated that they had pain at a variety of locations, including the knee, ankle and foot. Sometimes the only presenting complaint was an antalgic gait or refusal to walk (Table 1). The duration of the symptoms varied from 2 days to 1 yr. The onset of symptoms followed a witnessed fall in only two patients.

Each child received 0.185 mCi/kg of <sup>99m</sup>Tc-medronate (MDP) by intravenous injection. In each case, blood-pool images of the symptomatic region and delayed whole-body bone images were performed. In children with suspected hip lesions, delayed pin-hole images of the hips were obtained, usually in internal and external rotation. Forty-three plain radiographic, one MRI and two hip ultrasound examinations were available for comparison.

## RESULTS

### Abnormal Bone Scans

Thirty children had abnormal bone scans, which are summarized in Tables 1 and 2. Four patients each had two abnormalities in the lower extremities, and one had three for a total of 36 abnormal findings on bone scan. Bone scan abnormalities were present in approximately the same location as the patient's signs and/or symptoms in 16 of 30 cases (Table 1).

### Hip Abnormalities

Two children had decreased uptake in the femoral head. In one, the decreased uptake involved most or all of the affected femoral head. A radiograph before the bone scan showed questionable evidence of Legg-Perthes disease, and a repeat radiograph 4 mo later showed typical changes of Legg-Perthes disease. The second child had a small area of decreased uptake in the central-superior portion of the femoral head. A radiograph showed a joint effusion and an MRI study demonstrated effusion, without changes of avascular necrosis. The child remained well after three months of follow-up.

Four children had a diffuse increase in blood-pool and/or bone activity at the hip, consistent with synovitis. For

Received Jun. 21, 1991; revision accepted Oct. 21, 1991.

For reprints contact: Michael J. Gelfand, MD, Department of Radiology, Children's Hospital Medical Center, Cincinnati, OH 45229-2899.

**TABLE 1**  
Signs and Symptoms in 30 Children with Abnormal Bone Scans

Sign and/or symptom	Number of children	Number with signs or symptoms at same site as bone scan abnormality
Hip or groin pain	6	6
Knee pain	3	3
Ankle pain	1	1
Localized pain and swelling	3	3
Not walking	4	0
Limp	5	0
Limp with pain or tenderness	7	3
Unknown, history of fall	1	0
<b>Total</b>	<b>30</b>	<b>16</b>

one of these four children, no correlative studies were available. The other three children had normal x-rays, and in two of the three, sonography demonstrated intra-articular fluid.

#### Proximal Femoral Abnormalities

Three children had abnormal uptake in the proximal femur. Radiographs were available in two of these patients and were normal in one. In the other child, the original x-ray was normal, but a focal lucency in the proximal femur was subsequently noted on radiographs 2 mo after

the bone scan. The radiographic lucency showed gradual evidence of healing and no diagnostic pathological specimen was obtained.

#### Knee Abnormalities

Three children had scintigraphic evidence of knee synovitis on blood-pool and/or bone images manifested as a diffuse increase in uptake in the distal femoral and proximal tibial epiphyses. In one child, the bone scan was ordered in an attempt to confirm a questionable x-ray finding of a Salter I fracture, but there was no scintigraphic evidence of this type of lesion. The second child had a normal x-ray.

#### Tibial and Fibular Abnormalities

Four bone scan abnormalities in the tibia and one in the fibula were demonstrated. Two patients had scintigraphic patterns consistent with tibial stress injuries, but radiographs were normal in both cases. One child had a pattern of extensive mid-tibial periosteal reaction on a follow-up plain radiograph that was consistent with a toddler's fracture. A distal fibular uptake abnormality corresponded to and was consistent with a possible Salter II fracture on x-ray. One distal tibial bone scan abnormality in an area that was radiographically normal remains unclassified.

#### Tarsal Bone Abnormalities

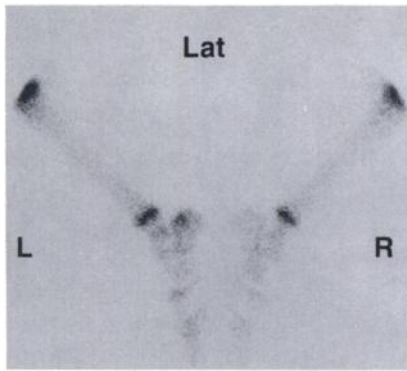
Sixteen patients had tarsal bone abnormalities, one in the talo-tibial joint, four in the calcaneus (Fig. 1), nine in or at the margins of the cuboid bone (Fig. 2), and two in multiple tarsal bones. Although all patients had radio-

**TABLE 2**  
Focal Bone Scan Abnormalities in 30 Children with Lower Extremity Pain, Refusal to Walk and/or Gait Abnormalities

Bone scan finding	Number of abnormal bone scans	Other imaging studies available	Other imaging studies abnormal	Initial radiograph of wrong site
<b>Hip (9)</b>				
Femoral head avascularity	2	2	2	0
Synovitis	4	3	2	0
Abnormal proximal femur uptake	3	3	1	0
<b>Knee (3)</b>				
Synovitis	3	2	1*	0
<b>Lower leg (5)</b>				
Tibial stress injury	2	2	0	0
Fibular injury	1	1	1*	0
Toddler's fracture of tibia	1	1	1	0
Other distal tibial abnormality	1	1	0	0
<b>Foot and ankle (16)</b>				
Abnormal calcaneal uptake	4	4	1	2
Abnormal talo-tibial joint uptake	1	1	0	0
Abnormal cuboid uptake	9	9	0	5
Multiple tarsal bone abnormalities	2	2	0	0
<b>Total</b>	<b>33†</b>	<b>31†</b>	<b>9</b>	<b>7</b>

\* Questionably abnormal finding on radiographs.

† Includes patients with multiple abnormalities on bone scan.



**FIGURE 1.** Increased uptake is noted in the postero-superior aspect of the left calcaneus. A later radiograph demonstrated a stress fracture in this location.

graphs of some portion of the lower extremities, radiographs of the feet were available for correlation in only nine cases. All four radiographs of the cuboid were negative. In one patient with a focal posterior calcaneal abnormality, radiographs demonstrated a stress fracture. One patient with an anterior calcaneus abnormality and both patients with multiple tarsal bone abnormalities had normal radiographs.

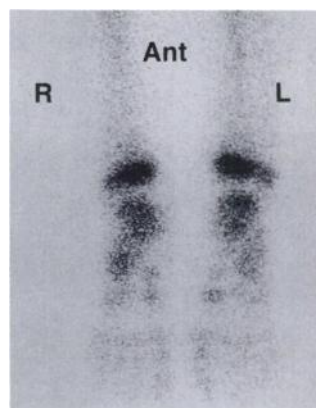
Children with calcaneal abnormalities ranged in age from 2 yr 6 mo to 4 yr 2 mo (median 2 yr 9 mo), and patients with cuboid bone abnormalities ranged in age from 1 yr 7 mo to 4 yr 5 mo (median 3 yr 3 mo).

#### Other Findings

Three patients had a non-focal diffuse asymmetry in radiopharmaceutical uptake in the lower extremities. Radiographs in one patient showed increased widening of the hip joint space that became normal on a follow-up examination, and a second patient's radiographs were negative.

#### DISCUSSION

When lower extremity pain is present in the preschool child, the child may be unable to adequately describe the location and nature of the symptoms. As a result, the child often simply refuses to bear weight or limps. The child's



**FIGURE 2.** Increased uptake is noted in the area of the right cuboid bone. An initial radiograph and a follow-up x-ray 1 mo later were both normal.

limited ability to communicate then poses a problem for the clinician. In order to diagnose and document the problem, radiographs are usually ordered first. If radiographs are negative and the symptoms are persistent or severe, bone scintigraphy may also be performed.

Although bone scintigraphy has been advocated as a diagnostic imaging modality in children with occult skeletal pain and gait disturbances, relatively little attention has been paid to the preschool age group. We have reviewed the bone scan findings in 56 preschool children who were referred for bone scintigraphy because of occult lower extremity pain. In this series, more than half of the bone scans were abnormal, and about half of the abnormalities were in the feet. The number of foot abnormalities was surprising to us. Several years ago Starshak et al. and more recently Moss and Carty reported that calcaneal stress fractures occur in this age group, and that these stress injuries are associated with a positive bone scan (3,4). Rapid resolution of symptoms was described by the authors in both series (3,4). However, of the 16 foot abnormalities in our series, only 4 were in the calcaneus.

Of particular interest was the large number of abnormalities in or adjacent to the cuboid bone. Nine children had uptake in this location. Because foot trauma was not suspected prior to scintigraphy, only four of these nine children had radiographs of the feet, and all were normal. From the patient charts that we reviewed, it appeared that symptoms often were not prolonged, and that, in a number of cases, the children were once again ambulating normally before a follow-up radiograph could be obtained. We were uncertain of the exact nature of the cuboid bone pathology until the recent report of Blumberg and Patterson, who reported that compression fractures of the cuboid occur in toddlers, with the radiographic injury located close to the articular surface of the cuboid with the calcaneus (5). Although none of the injuries that they described was witnessed by an adult or could be described by the child, they postulated that this type of injury might be caused by forced plantar hyperflexion of foot. One of the injuries in our series was witnessed by a parent, who stated that the child's forefoot became caught in a floor grate, with continued forward motion against the inadvertently immobilized forefoot. This presumably caused the type of hyperflexion injury postulated by Blumberg and Patterson.

Tibial injuries have also been described in this age group (6,7). A tibial toddler's fracture, a spiral fracture of the mid-tibia, was seen in only one child and was confirmed by an abnormal radiograph. Minor stress fractures may also occur in the tibia in slightly older preschool children, and two such abnormalities were seen in this series (1).

The small number of positive radiographs in our study is similar to the results of Blatt et al. who studied 84 preschool children with acute gait disturbance and normal physical examinations. Eighty-one (97%) of the 84 children had normal radiographs (8). Our results differ from the large radiographic study by Oudjhane et al. (9). They

reviewed 500 radiographic examinations of acutely limping preschool children. The authors concentrated upon traumatic lesions and found 100 fractures, two in the pelvis, 30 in the femur, 56 in the tibia and fibula and 12 in the foot. Foot fractures included one calcaneal and eleven metatarsal fractures. The fractures in their study were distributed quite differently from the suspected and proven traumatic lesions in our study, probably because they represent fractures that are easily detected radiographically. When radiographs are normal, our experience indicates that traumatic abnormalities in feet, particularly in the cuboid and calcaneus, are a frequent cause of the gait abnormality. Radiographic examination is less likely to miss tibial and fibular trauma.

Evidence of synovitis in the knees and hips was present in several patients. Four patients had a diffuse increase in uptake in the hip suggestive of synovitis, and three additional patients with normal bone scans had radiographs that demonstrated widening of the hip joint space that suggested hip effusion. When there is evidence of hip joint involvement on physical examination, the presence or absence of effusion should first be documented, as synovial fluid under increased pressure in the hip joint may compromise blood flow to the femoral head. Effusion is most commonly diagnosed by radiography, although a recent investigation has shown ultrasound to be more sensitive than the plain radiograph in the detection of fluid in the hip joint (10). If fluid is present in the hip joint, it may be aspirated and cultured, and, if there is evidence of septic arthritis, adequate provision may be made for drainage of the hip joint. In patients with clinical evidence of hip synovitis, the bone scan should be performed after plain radiography and/or sonography have been performed to exclude significant hip effusion. Although the bone scan may demonstrate evidence of hip synovitis, it is usually performed to evaluate femoral head perfusion and to exclude trauma, infection and neoplasm in the femur and pelvis. Bone scintigraphy has been extremely accurate in the early diagnosis of Legg-Perthes disease (11,12). Only a small percentage of patients with apparent absent femoral

uptake do not go on to develop radiographic Legg-Perthes disease, perhaps representing a forme fruste of this disease (11,13).

## CONCLUSION

Preschool children with lower extremity pain and gait abnormalities often have abnormal bone scans. Bone scan abnormalities in the feet are common and are frequently related to calcaneal or cuboid trauma.

## ACKNOWLEDGMENT

Presented at International Pediatric Radiology, '91, Stockholm, Sweden, May 27-31, 1991.

## REFERENCES

1. Sty R, Wells RG, Smith WB. The child with acute leg pain. *Semin Nucl Med* 1988;18:137-158.
2. Park HM, Rothschild PA, Kernek CB. Scintigraphic evaluation of extremity pain in children: its efficacy and pitfalls. *AJR* 1985;145:1079-1084.
3. Starshak RJ, Simons GW, Sty JR. Occult fracture of the calcaneus—another toddler's fracture. *Pediatr Radiol* 1984;14:37-40.
4. Moss EH, Carty H. Scintigraphy in the diagnosis of occult fractures of the calcaneus. *Skeletal Radiol* 1990;19:575-577.
5. Blumberg K, Patterson RJ. The toddler's cuboid fracture. *Radiology* 1991; 179:93-94.
6. Miller JH, Sanderson RA. Scintigraphy of toddler's fracture. *J Nucl Med* 1988;29:2001-2003.
7. Park HM, Kernek CB, Robb JA. Early scintigraphic findings of occult femoral and tibial fractures in infants. *Clin Nucl Med* 1988;13:271-275.
8. Blatt SD, Rosenthal BM, Burnhart DG. Diagnostic utility of lower extremity radiographs of young children with gait disturbances. *Pediatrics* 1991; 87:138-140.
9. Oudjhane K, Newman B, Oh KS, et al. Occult fractures in preschool children. *J Trauma* 1988;28:858-860.
10. Foster JL, Babcock DS, Oestreich AE, et al. Hip pain in children: comparison of sonography and arthrocentesis in detecting joint fluid. Presented at the 32nd Annual Meeting of the Society for Pediatric Radiology, San Antonio, Texas, April 6-9, 1989.
11. Sutherland AD, Savage JP, Paterson DC, Foster BK. The nuclide bone scan in the diagnosis and management of Perthes' disease. *J Bone Joint Surg* 1980;62B:300-306.
12. Calver R, Venugopal V, Dorgan J, et al. Radionuclide scanning in the early diagnosis of Perthes' disease. *J Bone Joint Surg* 1981;63B:379-382.
13. Gelfand MJ, Ball WS, Oestreich AE, et al. Transient loss of femoral head Tc-99m-diphosphonate uptake with prolonged maintenance of femoral head architecture. *Clin Nucl Med* 1983;8:347-354.