

# Technetium-99m-DTPA Aerosol and Gallium-67 Scanning in Pulmonary Complications of Human Immunodeficiency Virus Infection

J. Rosso, J. M. Guillon, A. Parrot, M. Denis, G. Akoun, Ch. Mayaud, M. Scherrer, and M. Meignan

Hôpital Henri Mondor, Service de Médecine Nucléaire, Créteil, France; and Hôpital Tenon, Centre de Pneumologie et de Réanimation Respiratoire, Paris, France

We retrospectively compared the results of  $^{67}\text{Ga}$  chest scans and  $^{99\text{m}}\text{Tc}$ -DTPA aerosol clearance measurements with those of fiberoptic bronchoscopy in 88 patients infected with the human immunodeficiency virus. Of 100 investigations, a pulmonary infection was diagnosed in 39, mainly *Pneumocystis carinii* pneumonia and a noninfectious disorder was found in 42, mainly Kaposi's sarcoma and lymphocytic alveolitis. Gallium scans and DTPA clearance were abnormal respectively in 74% and 92% of infectious complications, and in 12% and 60% of noninfectious disorders. In 10 cases, DTPA clearance was accelerated, while chest x-ray, arterial blood gases and even gallium scanning were normal. A value of DTPA clearance  $>4.5\% \cdot \text{min}^{-1}$  was both sensitive and specific for the diagnosis of *Pneumocystis carinii* pneumonia. The gallium scan was always normal in bronchopulmonary Kaposi's sarcoma. We conclude that in symptomatic patients: (1) DTPA clearance measurements are useful for detecting lung disease when chest x-ray and/or  $\text{PaO}_2$  are normal and (2) a gallium scan is indicated to distinguish progressive Kaposi's sarcoma from a superimposed second process when radiological abnormalities of pulmonary Kaposi's sarcoma are present.

J Nucl Med 1992; 33:81-87

The spectrum of pulmonary disorders associated with the human immunodeficiency virus (HIV) infection includes both infectious and noninfectious diseases. *Pneumocystis carinii* pneumonia is still the most common HIV-related pulmonary infection in the United States and in Europe. Pyogenic bacterial pneumonia, typical or atypical tuberculosis, cytomegalovirus infections occur with less frequency (1). The differential diagnosis of a suspected pulmonary infection includes several noninfectious HIV-related complications such as Kaposi's sarcoma, non-Hodgkin's lymphoma, lymphocytic alveolitis and lymphocytic interstitial pneumonitis (2). Because each pulmonary

disorder requires specific therapy, a definite diagnosis should be made each time a complication occurs. Most of the time, this definite diagnosis requires fiberoptic bronchoscopic biopsy, bronchial brushing or washing or even open-lung biopsy (1). In view of the many kinds of pulmonary disorders that may occur during the course of HIV infection, a patient may be faced with the prospect of repeated invasive procedures. This emphasizes the need to select from among symptomatic patients those who really require exhaustive pulmonary diagnostic evaluation. This selection is often difficult since symptoms are often constitutional or nonspecific (3), examination of the chest and chest x-ray may be normal (1) and measurement of lung volumes and spirometry lacks both sensitivity and specificity for detecting pulmonary disease (4). Two nuclear medicine tests have been used to help determine the patients for whom it is necessary. Gallium scanning was the first and has been used primarily to identify the presence of *Pneumocystis carinii* pneumonia (5-11). Subsequently, several studies showed that  $^{67}\text{Ga}$  lung imaging is a sensitive mean of detecting HIV-related pulmonary infections, particularly in the absence of clear-cut localizing symptoms or signs (12-16). Recently,  $^{99\text{m}}\text{Tc}$ -DTPA aerosol scanning, which studies the permeability characteristics of the lung parenchyma, has been proposed as the indirect diagnostic test of choice for diagnosing *Pneumocystis carinii* pneumonia (17-19). This paper reports our experience with these two tests in patients infected with HIV to assess their respective diagnostic value in various pulmonary disorders.

## PATIENTS AND METHODS

### Patients

One hundred  $^{99\text{m}}\text{Tc}$ -DTPA aerosol and  $^{67}\text{Ga}$  chest scans were performed on 88 patients infected with HIV. These examinations were done in 69 patients because of fever and/or respiratory symptoms and in 31 asymptomatic patients either because their chest radiograph was abnormal (5 patients) or because they gave informed consent to participate in a prospective study about their immunologic lung status (26 patients). Seventy-four patients were homosexual males, 7 were Haitian and 7 were intravenous drug abusers. Thirteen subjects were sero-positive healthy carriers, 18

Received Feb. 21, 1991; revision accepted Jul. 24, 1991.  
For reprints contact: Pr. Michel Meignan, Service de Médecine Nucléaire, Hôpital Henri Mondor, 51, avenue du Maréchal de Lattre de Tassigny 94010 Créteil, France.

had a prolonged generalized lymphadenopathy, 19 had ARC and 38 had full-blown AIDS according to the Centers for Disease Control classification of HIV disease. Twenty-nine patients were smokers but 16 of them smoked less than 10 cigarettes per day or had stopped smoking at least 3 mo before examination. Six of the 13 heavy smokers had pulmonary disorders identified by bronchoscopy. In order to avoid bias due to cigarette smoking, we excluded the results of their DTPA clearance rate from the study. Blood samples were taken from all patients for serology, culture (viral and bacterial) as well as for arterial blood gas measurement. A chest radiograph was performed in all patients and interpreted by a pneumologist who did not have access to scan results. He reported the chest x-ray as abnormal when either of the following abnormalities were present: diffuse or localized parenchymal infiltrate, pleural thickening or free pleural fluid, or mediastinal adenopathy. Patients underwent fiberoptic bronchoscopy within 5 days before or after the scans. Several specimens were systematically collected (bronchoalveolar washings, bronchial brushings and bronchial biopsies), and routinely processed for cytopathologic and bacteriologic examination. Cell composition of lavage fluid have been systematically analyzed. Alveolar lymphocytes were subtypes and tested for cytotoxicity against autologous macrophages when either the percentage or absolute number was increased in bronchoalveolar lavage and no infection or malignancy was identified. Transbronchial lung biopsies or open lung biopsies were done if the other procedures failed to give a definite diagnosis.

#### Measurement of $^{99m}\text{Tc}$ -DTPA Aerosol Transfer

The transfer of  $^{99m}\text{Tc}$ -DTPA from the air-space to blood may be measured using the technique of  $^{99m}\text{Tc}$ -DTPA aerosol scanning. As previously described, supine subjects inhaled an aerosol of  $^{99m}\text{Tc}$ -DTPA produced by a VENTICIS II nebulizer delivery system (20,21) for 3 min. This system delivers a heterodisperse aerosol 0.6 micron in mass median diameter and a standard geometric deviation of 1.7. The regional radioactivity has been followed for 20 min in a posterior view with a gamma camera (Sopha Medical, Buc, France) linked to a minicomputer. Time-activity curves were derived from the radioactivity computed in a region of interest (ROI) drawn on the entire lung fields that were fitted with a monoexponential line by regression analysis for the first 7 min of the study, as described by Rinderknecht et al. (22).

The pulmonary  $^{99m}\text{Tc}$ -DTPA clearance rate was calculated from negative slope of the regression line and expressed in term of percentage decrease of the radioactivity per minute ( $\% \cdot \text{min}^{-1}$ ). A clearance rate was considered as increased if it was higher than two standard deviations from the mean value of the normal nonsmoking subject in the laboratory ( $1.1 \pm 0.34\% \cdot \text{min}^{-1}$ ,  $n = 10$ ).

The clearance rates of each lung were combined to give a mean value. By computing the clearance on the first 7 min, we minimized a possible effect on our results of the mucociliary clearance and of radioactivity contained in the chest wall. The mucociliary transport is relatively slow (23) and thus has little influence on the measurements performed over a short period of time. Moreover, in all patients we verified by visual inspection of the scans the absence of any central airway impaction of the aerosol which could have been cleared by a mucociliary mechanism. At the end of the experiments, we also measured the radioactivity in a ROI drawn around the hila and between the lungs and confirmed the absence of a central accumulation of radioactivity which would

have indicated the involvement of mucociliary clearance. The radioactivity cleared from the alveoli accumulates in the blood and results in a progressive increase of the background due to the activity contained in pulmonary blood volume and chest walls. This phenomenon, which can be negligible in normal subjects, might lead to an underestimation of the clearance when permeability is increased. Many techniques of blood background corrections have been proposed (24). However, we used the computation of clearance during the first 7 min to minimize the effect of this phenomenon (22,25,26).

The last cause of error might be due to the presence of free pertechnetate ( $\text{TcO}_4$ ) eluted from the  $^{99m}\text{Tc}$ -DTPA secondary to the oxidizing breakdown of the molecule during nebulization. This leads to an overestimation of clearance rate since this small molecule ( $\text{PM} = 145$  days) crosses the membrane rapidly (clearance rate of 5% per minute in the normal subjects) (22). Chromatography on the solution left in the nebulizer after the end of the inhalation verified that the proportion of free  $\text{TcO}_4$  in our experiments was less than 5% of the inhaled quantity.

#### Gallium Scanning

After performing DTPA clearance measurements, patients received an intravenous injection of 185 MBq (5 mCi) of  $^{67}\text{Ga}$ -citrate. The lung gallium scan was performed in anterior and posterior views 48 hr after injection with a medium-energy collimator, using 20% energy windows set on the gallium photopeaks. A total of 500,000 counts per view were acquired. Results were expressed according to Coleman et al. (9). The scans were graded visually by two observers from 1 (normal) to 4 (diffuse lung uptake, the intensity of which is greater than the liver uptake) by comparing the relative gallium uptake of lungs, liver and adjacent soft tissues.

#### Statistical Analysis

DTPA clearance values are expressed as mean  $\pm$  s.d. Comparison between groups was done using Student's two-tailed t-test for unpaired data. Significant levels were accepted as p values less than 0.05 (two-tailed). A StatView 512 statistical package on a Macintosh personal computer was used for analysis.

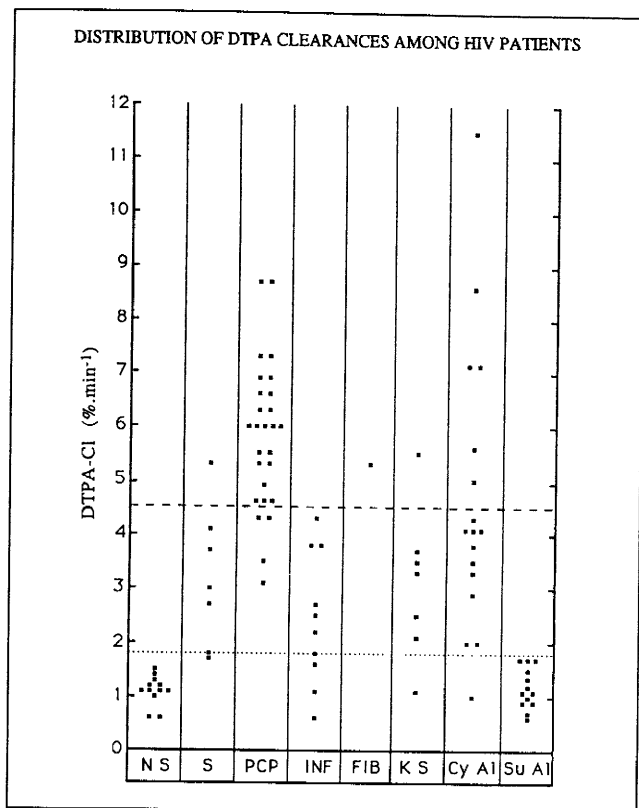
The optimal value of DTP clearance, in terms of sensitivity and specificity for the diagnosis of *Pneumocystis carinii* pneumonia, was determined by a receiver operating curve analysis (ROC).

## RESULTS

#### Fiberoptic Bronchoscopy

Based on the findings of fiberoptic bronchoscopy or open-lung biopsy, three groups of patients were identified. Group I consisted of 19 patients whose fiberoptic bronchoscopy did not reveal any tumoral or infectious process and whose lavage fluid had normal composition. Twelve patients were nonsmokers and seven smoked 10–40 cigarettes per day.

Group II consisted of 39 patients whose fiberoptic bronchoscopy or serology were positive for an infectious agent. *Pneumocystis carinii* was identified in most of these patients (27 cases). Of the 12 other infectious agents, cytomegalovirus was documented in 4, mycobacterium in 4, pyogenic bacterium in 2, *Cryptococcus neoformans* in 1, and parainfluenza virus in 1.



**FIGURE 1.** . . . . Lower limit of abnormal DTPA clearance rate ( $1.8\% \cdot \text{min}^{-1}$ ). ---- Cut point determined by ROC analysis ( $4.5\% \cdot \text{min}^{-1}$ ). Definition of abbreviations: NS = control nonsmokers; S = control smokers; PCP = pneumocystis carinii pneumonia; INF = other infections; KS = Kaposi's sarcoma; Cy AI = cytotoxic alveolitis; and Su AI = suppressive alveolitis.

Group III consisted of 42 patients whose pathological condition was related to a noninfectious origin; the main pathological condition was represented by lymphocytic alveolitis (33 cases). Among these, cytotoxicity assays and lymphocytic subtyping identified 19 cytotoxic alveolitis and 14 suppressive alveolitis. Other noninfectious diseases included Kaposi's sarcoma in seven cases and post-*Pneumocystis carinii* pneumonia interstitial fibrosis in two cases.

Among the heavy smokers whose fiberoptic bronchos-

copy revealed a pulmonary disorder, two had a cytomegalovirus pneumonitis, one had a post-*Pneumocystis carinii* pneumonia fibrosis, one had a suppressive alveolitis and two had a cytotoxic alveolitis. Their corresponding DTPA clearance rates were excluded from DTPA analysis.

### Chest Radiograph and Arterial Blood Gases

Chest x-rays and arterial blood gases were normal in Group I patients (smokers and nonsmokers). Chest radiographs were abnormal in 27 out of 39 (69%) in Group II and in 18 out of 42 (43%) in Group III. Hypoxemia  $<90$  mmHg was detected in 20 patients (51%) in Group II and in 14 patients (33%) in Group III.

### Technetium-99m-DTPA Clearance Measurements

The distribution of DTPA clearance values is shown in Figure 1. The mean  $^{99\text{m}}\text{Tc}$ -DTPA clearance rate associated with each pulmonary disorder is reported in Table 1.

*Group I.* In nonsmoking HIV+ patients, all individual values of clearance rate were within the normal range of our laboratory. The mean value ( $1.12 \pm 0.29\% \cdot \text{min}^{-1}$ ) was not significantly different from that seen in nonsmoking HIV- subjects. By contrast, the mean value of HIV+ smokers clearance rate ( $3.2 \pm 1.29\% \cdot \text{min}^{-1}$ ) was significantly higher.

*Group II.* The clearance rate was accelerated in 34 of 37 infectious diseases (92%). More rapid clearance rates were seen in *Pneumocystis carinii* pneumonia (mean value:  $5.85 \pm 1.34\% \cdot \text{min}^{-1}$ ). The other causes of pneumonia induced moderately accelerated clearance rate which were indistinguishable from each other (mean value:  $2.46 \pm 1.24\% \cdot \text{min}^{-1}$ ).

*Group III.* The clearance rate was accelerated in 23 out of 38 noninfectious disorders (60%). DTPA clearance rate was always normal in suppressive alveolitis (mean value:  $1.19 \pm 0.38\% \cdot \text{min}^{-1}$ ), moderately accelerated in Kaposi's sarcoma (mean value:  $3.14 \pm 1.39\% \cdot \text{min}^{-1}$ ), and moderately to highly accelerated in cytotoxic alveolitis (mean value:  $4.73 \pm 2.67\% \cdot \text{min}^{-1}$ ).

Results of statistical comparison between the mean clearance of the different disorders are shown in Table 1.

**TABLE 1**  
DTPA Clearance in HIV Pulmonary Complications Mean and Standard Deviation ( $\% \cdot \text{min}^{-1}$ )

	Group I		Group II		Group III		
	HIV+ nonsmokers (n = 12)	HIV+ smokers (n = 7)	P.C. pneumonia (n = 27)	Other infections (n = 10)	Kaposi sarcoma (n = 7)	Cytotoxic alveolitis (n = 17)	Suppressive alveolitis (n = 13)
Mean	1.12 <sup>†</sup>	3.20 <sup>*†</sup>	5.83 <sup>*</sup>	2.46 <sup>*†</sup>	3.14 <sup>*†</sup>	4.73 <sup>*</sup>	1.19 <sup>†</sup>
s.d.	0.29	1.29	1.35	1.24	1.39	2.67	0.38

P.C. = *Pneumocystis carinii*.

\*  $p < 0.001$  as compared with Group I non-smokers (Student's t-test).

†  $p < 0.001$  as compared with *Pneumocystis carinii* pneumonia (Student's t-test).

In patients with *Pneumocystis carinii* pneumonia, the mean DTPA clearance rate was significantly higher than that observed in Group I patients (smokers and non-smokers). Moreover, a significant increase was found in all disorders except suppressive alveolitis when compared to Group I nonsmokers.

### Gallium Scanning

Gallium scans were always normal for Group I patients. Twenty-nine scans in Group II (74%) and 5 scans in Group III (12%) demonstrated abnormalities.

*Group II.* 24 of 29 abnormal scans showed a diffuse pattern of increased lung uptake. The most common infection associated with this diffuse pattern (22 cases) was *Pneumocystis carinii* pneumonia. In two other cases, cytologic examination and culture of bronchoalveolar lavage cells demonstrated cytomegalovirus pneumonia. In five scans, gallium accumulation was localized either within the lung (one bacterial pneumonia, one mycobacterial infection) or at the site of a lymph node group (three mycobacterial infections).

*Group III.* The five abnormal scans showed a diffuse intrapulmonary gallium accumulation. Correlating cytotoxic alveolitis was documented in four cases and post-*Pneumocystis carinii* pneumonia fibrosis in one case.

### Comparison Between Gallium Scan and <sup>99m</sup>Tc-DTPA Scan in Pulmonary Diseases with Normal Chest X-ray and Arterial Blood Gases

Of the 81 pulmonary diseases, both normal chest radiography and a normal PaO<sub>2</sub> were observed in 27. The most common disorder associated with these normal tests was suppressive lymphocytic alveolitis (11 cases). Corresponding DTPA clearance and gallium scans were always normal. Other associated pathological conditions included six cases of *Pneumocystis carinii* pneumonia, two cytomegalovirus pneumonia, one cryptococcosis, three bronchial Kaposi's sarcoma and four cytotoxic alveolitis. Of these 16 cases, the DTPA clearance rate was distinctly elevated in 15, as gallium uptake was abnormal only in 6 (Table 2).

### Comparison Between Gallium Scan and <sup>99m</sup>Tc-DTPA Scan in the Diagnosis of *Pneumocystis Carinii* Pneumonia

Of the 39 infectious pulmonary complications revealed by fiberoptic bronchoscopy, *Pneumocystis carinii* pneumonia was diagnosed in 27. DTPA clearance was increased in all of them as gallium uptake was normal in five (Table 3). Two of these normal gallium scans were observed in association with normal chest x-ray and arterial blood gases, as reported above (Cases 20 and 22). Two additional scans were associated with only minimally disturbed tests. Mildly increased interstitial markings alone were observed in one (Case 18) and a minimal hypoxemia alone was

**TABLE 2**  
Results of Gallium Scan and DTPA Scan in Pulmonary Complications with Normal Chest X-ray and Arterial Blood Gases

	No cases	No cases with abnormal DTPA-Cl	No cases with abnormal gallium scan
Suppressive alveolitis	11	0	0
Other complications			
P.C. pneumonia	6	6	4
CMV pneumonia	2	2	1
Cryptococcosis	1	1	0
Kaposi's sarcoma	3	3	0
Cytotoxic alveolitis	4	3	1
Total	16	15	6

DTPA-Cl = DTPA clearance and P.C. = *Pneumocystis carinii*.

present in another (case 25). The last normal gallium scan had both a correlative chest radiography with a definite interstitial infiltrate and a correlative moderate hypoxemia (case 14). Thus, the sensitivity and specificity of diffuse gallium lung uptake for the diagnosis of *Pneumocystis carinii* pneumonia is 81% and 89%, respectively. For its part, respective sensitivity and specificity of accelerated clearance rate is 100% and 45%. The optimal value, as determined by ROC analysis is 4.5%·min<sup>-1</sup>. When a clearance rate >4.5%·min<sup>-1</sup> is considered, the DTPA scan is 85% sensitive and 87% specific for the diagnosis of *Pneumocystis carinii* pneumonia.

### DISCUSSION

Pulmonary complications in patients infected with HIV are a frequent problem (1,2). Most of the patients will have several pulmonary complications during the course of HIV disease. Because each complication requires a specific therapy, an accurate diagnosis is necessary (1). Fiberoptic bronchoscopy, which is often needed for a definitive diagnosis, may be not only unpleasant but also have severe side effects (as may be the case in transbronchial lung biopsy) (27). Tests that are safe and noninvasive may help to select from among symptomatic patients those whose tests are abnormal and who therefore require further invasive diagnostic evaluation.

This study shows that DTPA scan seems to be the most sensitive scan procedure in detecting pulmonary disorder related to HIV infection. The sensitivity of an increased clearance rate is in fact 92% for infectious pulmonary complications and 60% for noninfectious pulmonary complications as arterial blood gases, chest x-ray and gallium scans had a sensitivity of respectively 46%, 69% and 72% for the detection of infectious diseases and 33%, 43% and 14% for the detection of noninfectious disorders. However, the 60% sensitivity of a DTPA scan observed in the group of noninfectious disorders appears rather moderate. This is mainly due to the inclusion in our series of a large

**TABLE 3**  
**Characteristics of Patients in the 27 Cases of PCP**

Case no.	Tobacco	Symptoms	Chest x-ray	PO <sub>2</sub>	PcO <sub>2</sub>	(cells/mm <sup>3</sup> )	B.A.L.			DTPA-CI (%·min <sup>-1</sup> )	Gallium (score)
							M(%)	L(%)	P+E(%)		
1	0	c,dysp	dDIO	59	31	199	54	41	5	5.33	4
2	0	dysp	DIO	ND	ND	800	46	54		6.00	3
3	0	c,dysp,f	DIO	70	38	130	68	29	3	7.30	3
4	0	c,dysp,f	DIO	54	30	210				6.30	4
5	0	c,dysp,f	DIO	49	31	600	36	29	35	5.33	4
6	0	c,f	dDIO	94	30	154	30	52	18	6.30	2
7	0	f	DIO	80	35	ND				4.30	3
8	0	c,f	DIO	110	40	95	80	20		4.60	2
9	0	dysp,f	DIO	54	39	766	45	50	5	3.55	4
10	0	c,dysp	DIO	56	30	180	90	10		4.62	4
11	0	c,f	DIO	100	38	51	67	26	7	4.95	3
12	0	c,f	DIO	103	43	158	64	34	2	6.02	3
13	<10	c,f	dDIO	100	40	300	57	38	5	6.93	3
14	<10	c,dysp	DIO	48	27	435	75	23	2	6.02	1
15	0	c,dysp,f	DIO	66	33	205	37	54	9	6.93	2
16	0	dysp,f	DIO	62	31	68	34	28	38	7.29	3
17	0	c	dDIO	113	35	ND				6.60	3
18	<10	f	dDIO	129	33	330	82	18		4.30	1
19	0	c	dDIO	98	37	179	77	17	6	4.62	2
20	<10	f	N1	110	31	169	23	73	4	8.66	1
21	0	c,dysp,f	N1	63	37	506	40	35	25	8.66	4
22	0	c,f	N1	104	31	250	63	33	4	3.15	1
23	<10	c,f	N1	100	35	84	87	8	5	6.02	3
24	0	f	N1	100	38	220	59	12	29	5.54	3
25	0	f	N1	91	33	128	26	71	3	5.54	1
26	0	c,f	N1	102	36	25	63	24	13	6.60	3
27	<10	c	N1	100	38	217	36	28	36	6.02	3

B.A.L. = bronchoalveolar lavage; DTPA-CI = DTPA clearance; M = macrophages; L = lymphocytes; P+E = polymorphonuclear and eosinophilic cells; <10 = tobacco intoxication less than 10 cigarettes per day; c = cough; dysp = dyspnea; f = fever; dDIO = discrete diffuse interstitial opacities; N1 = normal results; and ND = not done.

number of suppressive alveolitis in which the DTPA clearance is always normal. The question remains, in fact, as to the nature of this entity. The most striking pathological finding is an increase in both the percentage and absolute number of lymphocytes present in the lavage of these patients. Subtyping has shown that most of these lymphocytes are phenotypically suppressor T-lymphocytes (28). Nevertheless this alveolitis seems to have no deleterious effect on the lungs. In our study, patients had no respiratory symptoms and their chest x-rays and arterial blood gases were normal in the majority of cases. Thus, alveolitis, which is associated with advanced immunologic depression, may not be an actual pulmonary complication. If it is excluded from the group of noninfectious pulmonary complications, the sensitivity of a DTPA scan improves to 92% for the diagnosis of noninfectious pulmonary complications.

In addition, our data suggest that the DTPA scan is particularly useful to detect pulmonary disorders in patients with normal x-ray and arterial blood gases because, apart from suppressive alveolitis, DTPA clearance was accelerated in all but one case.

Concerning the diagnosis of pulmonary complications, this high sensitivity means that a normal DTPA clearance rate virtually excludes an intrathoracic pathology. Thus, the major interest of this scan is to help direct the investigations away from the chest when the clearance rate is normal.

The high sensitivity of the technique in detecting HIV pulmonary disorders is not surprising. Technetium-99m-DTPA is indeed a sensitive marker of the changes of the permeability characteristics of the lung parenchyma. It has been used to investigate the epithelial permeability in different physiological conditions (20,21,30) in subjects who smoke (30) and in various non-HIV pulmonary disorders (22,25,26,31,32). Alveolar damage is probably the main reason why DTPA transfer is increased in HIV pulmonary diseases, at least in *Pneumocystis carinii* pneumonia and cytotoxic alveolitis, which are associated with the highest clearance rates (18,33). Clearly, histological studies of *Pneumocystis carinii* pneumonia show that, from the early stages, the trophozoites attach to the alveolar lung epithelium resulting in foci of cell necrosis and denuded underlying basal laminae (34). Alveolar barrier

alterations have not been documented in cytotoxic alveolitis but either the HIV-specific cytotoxic T-lymphocytes or the targeted macrophages may release mediators such as interleukin 1, intracellular enzymes, free radicals, or tumor necrosis factor, some of them having been claimed to be responsible for alveolar damages (35-37).

Unfortunately, the technique does lack some specificity. A moderately increased clearance rate, in particular, cannot help to distinguish the various pulmonary disorders from each other nor from cigarette smoking.

By contrast, we found that a fast clearance rate is highly suggestive of *Pneumocystis carinii* pneumonia. A value higher than  $4.5\% \cdot \text{min}^{-1}$  is in fact 85% and 87% specific for the diagnosis of *Pneumocystis carinii* pneumonia. Of course, this value is to be considered with caution because it is linked to the type of pulmonary disorders and to the number of patients included in the study. However, our results are similar to those obtained by others in patients with *Pneumocystis carinii* pneumonia. Mason et al. have reported high clearance rates in 12 patients with AIDS and *Pneumocystis carinii* pneumonia (17). Moreover, O'Doherty et al. found that the value of the clearance rate and the shape of the transfer curve could readily distinguish *Pneumocystis carinii* pneumonia from other causes of infectious pulmonary involvement in HIV-positive patients and from tobacco intoxication (19). In that study, *Pneumocystis carinii* pneumonia was characterized by a biphasic rapid transfer time as other causes of pneumonia were not. Biphasic curves were not observed in our study because data were obtained only from the first 7 min of the test. This is of minimal practical importance since the value of the clearance rate alone can individualize *Pneumocystis carinii* pneumonia with a good specificity.

Nevertheless, the DTPA clearance scan cannot be used alone to make this diagnosis. First, some high clearance rates are due to cytotoxic alveolitis which most of the time do not require treatment. Second, trimethoprim-sulfamethoxazole and pentamidine, used for the treatment of *Pneumocystis carinii* pneumonia, may cause toxic reactions (38). Therefore, we believe that in the setting of high DTPA clearance rate a histologic diagnosis of *Pneumocystis carinii* pneumonia is needed before instituting a treatment with either of these drugs.

Compared to the DTPA scan, the gallium scan is less sensitive in the detection of pulmonary diseases. This lower sensitivity is particularly obvious in Group III. Only 5 of the 42 noninfectious disorders were associated with an abnormal gallium scan, resulting in a 12% sensitivity which contrasts sharply with the 60% sensitivity of DTPA scan. Even when the suppressive alveolitis is excluded from this group, the sensitivity of the gallium scan only reaches 18%. Thus, it is not surprising that we found the gallium scan to also have a poor sensitivity for the detection of pulmonary complications with normal chest x-ray and arterial blood gases since, apart from suppressive alveolitis, almost half of these complications are of a noninfectious

origin. We also found that the gallium scan was always normal in bronchial and pulmonary Kaposi's sarcoma, even when chest x-ray demonstrated alveolo-interstitial opacities (14,16). This finding is of importance for the work-up of patients with known bronchopulmonary Kaposi's sarcoma and worsening of their clinical and/or radiological status. Progressive Kaposi's sarcoma is often difficult to distinguish from superimposed second process. As Kaposi's sarcoma does not label with gallium, a positive gallium scan strongly suggests a second disease process and indicates further diagnostic evaluation. It is noticeable that from the five positive scans observed in Group III, 4 were associated with cytotoxic lymphocytic alveolitis. A similar pattern has been described in association either with lymphoid interstitial pneumonitis (an AIDS-defining complication of HIV infection) (39,40) or with nonspecific interstitial pneumonitis (41). These similarities raise the question of the nature of cytotoxic lymphocytic alveolitis, a recently investigated pathology (42,44), and the relationship between the presence and activities of the abnormal lymphocyte populations in the bronchoalveolar fluid and the clinically defined disorder of lymphoid interstitial pneumonitis and nonspecific interstitial pneumonitis.

Most of the positive scans were seen in association with a pulmonary infection. An abnormal uptake of gallium-citrate in patients with AIDS has been reported by numerous authors, and the gallium scan is usually considered to be a sensitive means for detecting infection, especially in the case of *Pneumocystis carinii* pneumonia (5-16). In our study, the gallium scan failed to detect 5 of 27 *Pneumocystis carinii* pneumonia, leading to an 81% overall sensitivity for the diagnosis of *Pneumocystis carinii* pneumonia. In particular, two of the five negative scans were seen in patients whose conventional diagnostic tests were also normal. Therefore, that DTPA scan was the only means in which to detect *Pneumocystis carinii* pneumonia. The sensitivity we found in our study is lower than that reported in other publications (9-11,13,16,45). It is probably due to the high number of patients with moderately disturbed or normal conventional screening tests. These patients were at the early stage of *Pneumocystis carinii* infection in which no or only occasional minimal alveolar-septal inflammation is found (46). On the other hand, we found the gallium scan specificity to be somewhat higher than that reported in other studies (9,11,14,16). This increased specificity may be due to the small number of patients with non-*Pneumocystis carinii* pneumonia pulmonary infection. Moreover, in contrast to other reports, no abnormal gallium uptake was found in HIV smokers free of pulmonary disease (47).

In view of our results, we think that the diagnostic algorithm for AIDS patients with fever and/or respiratory symptoms proposed by Kramer should be modified, at least for nonsmokers. When a patient has a normal lung chest x-ray, DTPA aerosol scanning should be performed first. In addition to its higher sensitivity, DTPA scanning

offers several advantages in comparison with gallium imaging. It is readily available, less expensive, rapid to perform, and the results allow for faster analysis. If DTPA clearance is normal, then etiologic investigations should be directed away from the chest. If the DTPA clearance is accelerated, a gallium scan may be indicated to guide the clinician to an appropriate site for biopsies (lung versus lymph nodes).

When a patient has known pulmonary Kaposi's sarcoma with an abnormal chest x-ray, a gallium scan should be done alone. As gallium rarely accumulates in Kaposi's sarcoma lesions, a positive scan should prompt to perform further invasive diagnostic procedures.

## REFERENCES

- Murray JF, Mills J. Pulmonary infectious complications of human immunodeficiency virus infection. *Am Rev Respir Dis* 1990;141:1356-1372.
- White DA, Matthay RA. Noninfectious pulmonary complications of infection with the human immunodeficiency virus. *Am Rev Respir Dis* 1989;140:1763-1787.
- Hopewell PC, Luce JM. Pulmonary involvement in the acquired immunodeficiency syndrome. *Chest* 1985;87:104-112.
- Stover DE. Pulmonary function tests. *Clin Chest Med* 1988;9:473-479.
- Liebman R, Ryo UY, Bekerman C, Pinsky SM. Ga-67 scan of a homosexual man with *Pneumocystis carinii* pneumonia. *Clin Nucl Med* 1982;7:480-481.
- Parthasarathy KL, Bakshi SP, Bender MA. Radiogallium scan in *P. carinii* pneumonia. *Clin Nucl Med* 1982;7:71-74.
- Levin M, McLeod R, Young Q, et al. Pneumocystis pneumonia: importance of gallium scan for early diagnosis and description of a new immunoperoxidase technique to demonstrate *Pneumocystis carinii*. *Am Rev Respir Dis* 1983;128:182-185.
- Moses SC, Baker SR, Seldin MF. Diffuse pulmonary gallium accumulation with a normal chest radiogram in a homosexual man with *Pneumocystis carinii* pneumonia. A case record. *Clin Nucl Med* 1983;8:608-609.
- Coleman DL, Hattner RS, Luce JM, Dodek PM, Golden JA, Murray JF. Correlation between gallium lung scans and fiberoptic bronchoscopy in patients with suspected pneumocystis carinii pneumonia and the acquired immune deficiency syndrome. *Am Rev Respir Dis* 1984;130:1166-1169.
- Tuazon CU, Delaney MD, Simon GL, Witorsch P, Varma VM. Utility of gallium-67 scintigraphy and bronchial washings in the diagnosis and treatment of *Pneumocystis carinii* pneumonia in patients with acquired immunodeficiency syndrome. *Am Rev Respir Dis* 1985;132:1087-1092.
- Barron TN, Birnbaum N, Shane L, Goldsmith SJ, Rosen MJ. *Pneumocystis carinii* pneumonia studied by gallium-67 scanning. *Radiology* 1985;154:791-793.
- Bach MC, Bagwell SP, Masur H. Utility of gallium imaging in the diagnosis of *Mycobacterium aviumintracellulare* infection in patients with the acquired immunodeficiency syndrome. *Clin Nucl Med* 1986;11:175-177.
- Skarzynski JJ, Sherman W, Lee HK, Berger H. Patchy uptake of gallium in the lungs of AIDS patients with atypical mycobacterial infection. *Clin Nucl Med* 1987;12:507-509.
- Kramer EL, Sanger JJ, Garay SM, et al. Gallium-67 scans of the chest in patients with acquired immunodeficiency syndrome. *J Nucl Med* 1987;28:1107-1114.
- Bitran J, Beckerman C, Weinstein R, Bennett C, Ryo U, Pinsky S. Patterns of gallium-67 scintigraphy in patients with acquired immunodeficiency syndrome and the AIDS related complex. *J Nucl Med* 1987;28:1103-1106.
- Woolfenden JM, Carrasquillo JA, Larson SM, et al. Acquired immunodeficiency syndrome: Ga-67 citrate imaging. *Radiology* 1987;162:383-387.
- Mason GR, Duane GB, Mena I, Effros RM. Accelerated solute clearance in *Pneumocystis carinii* pneumonia. *Am Rev Respir Dis* 1987;135:864-868.
- Picard C, Meignan M, Rosso J, Cinotti L, Mayaud C, Revuz J. Technetium-99m-DTPA aerosol and gallium scanning in acquired immune deficiency syndrome. *Clin Nucl Med* 1987;12:501-506.
- O'Doherty MJ, Page CJ, Bradbeer CS, et al. The place of lung <sup>99m</sup>Tc-DTPA aerosol transfer in the investigation of lung infections in HIV-positive patients. *Respir Med* 1989;83:395-401.
- Meignan M, Rosso J, Leveau J, et al. Exercise increases the lung clearance of inhaled technetium-99m-DTPA. *J Nucl Med* 1986;27:274-280.
- Meignan M, Rosso J, Robert R. Lung epithelial permeability to aerosolized solutes: relation to position. *J Appl Physiol* 1987;62:902-911.
- Rinderknecht J, Shapiro L, Krauthammer M, et al. Accelerated clearance of small solutes from the lungs in interstitial lung disease. *Am Rev Respir Dis* 1980;121:105-117.
- Morrow PE, Gibb FR, Gazioglu KM. A study of particulate clearance from the human lung. *Am Rev Respir Dis* 1967;96:1209-1221.
- Coates G, O'Brodovich H. Extrapulmonary radioactivity in lung permeability measurements. *J Nucl Med* 1987;28:903-906.
- Braude S, Nolop KB, Hughes JMB, Barnes PJ, Royston D. Comparison of lung vascular and epithelial permeability indices in the adult respiratory distress syndrome. *Am Rev Respir Dis* 1986;133:1002-1005.
- Jefferies AL, Coates G, O'Brodovich H. Pulmonary epithelial permeability in hyaline-membrane disease. *N Engl J Med* 1984;311:1075-1080.
- Broaddus VC, Dake MK, Stulberg MS, et al. Bronchoalveolar lavage and transbronchial biopsy for the diagnosis of pulmonary infections in the acquired immunodeficiency syndrome. *Ann Intern Med* 1985;102:747-752.
- Joly P, Guillon JM, Mayaud C, et al. Cell-mediated suppression of HIV-specific cytotoxic effector cells. *J Immunol* 1989;143:193-201.
- Marks JD, Luce JM, Lazar NM, et al. Effect of increases in lung volume on clearance of aerosolized solute from human lung. *J Appl Physiol* 1985;59:1242-1248.
- Mason GR, Ulzer JM, Effros RM, Reid E. Rapid reversible alteration of pulmonary epithelium permeability induced by smoking. *Chest* 1983;83:6-11.
- Huchon GL, Russel JA, Barritault LG, Lipavsky A, Murray JF. Chronic air-flow limitation does not increase respiratory epithelial permeability assessed by aerosolized solute, but smoking does. *Am Rev Respir Dis* 1984;130:457-460.
- Dusser DJ, Collignon MA, Stanislas-Leguern G, Barritault LG, Chretien J, Huchon GJ. Respiratory clearance of <sup>99m</sup>Tc-DTPA and pulmonary involvement in sarcoidosis. *Am Rev Respir Dis* 1986;134:493-497.
- Meignan M, Guillon JM, Denis M, et al. Increased lung epithelial permeability in HIV-infected patients with isolated cytotoxic T-lymphocytic alveolitis. *Am Rev Respir Dis* 1990;141:1241-1248.
- Lanken PN, Minda M, Pietra GG, Fishman AP. Alveolar response to experimental *Pneumocystis* pneumonia in the rat. *Am J Pathol* 1980;99:561-588.
- Martin WJ, Gadek JE, Hunninghake GW. Oxidant injury of lung parenchymal cells. *J Clin Invest* 1981;68:1277-1288.
- Cochrane CG, Spragg R, Revak SD. Pathogenesis of the adult respiratory distress syndrome: evidence of oxidant activity in bronchoalveolar lavage fluid. *J Clin Invest* 1983;71:754-761.
- Tracey KJ, Lowry SF, Cerami A. Cachetin/TNF- $\alpha$  in septic shock and septic adult respiratory distress syndrome. *Am Rev Respir Dis* 1988;138:1377-1379.
- Mitsuyasu R, Groopman J, Volberding P. Cutaneous reaction to trimethoprim-sulfamethoxazole in patients with AIDS and Kaposi's sarcoma. *N Engl J Med* 1983;308:1535-1536.
- Schiff RG, Kabat L, Kamani N. Gallium scanning in lymphoid interstitial pneumonitis in children with AIDS. *J Nucl Med* 1987;28:1915-1919.
- Zuckier LS, Ongseng F, Goldbarb CR. Lymphocytic interstitial pneumonitis: a cause of pulmonary gallium-67 uptake in a child with acquired immunodeficiency syndrome. *J Nucl Med* 1988;29:707-711.
- Ognibene FP, Masur H, Rogers P, et al. Nonspecific interstitial pneumonitis without evidence of pneumocystis carinii in asymptomatic patients infected with human immunodeficiency virus (HIV). *Ann Intern Med* 1988;109:874-879.
- Autran B, Mayaud CM, Raphael M, et al. Evidence for a cytotoxic T-lymphocyte alveolitis in human immunodeficiency virus-infected patients. *AIDS* 1988;2:179-183.
- Guillon JM, Autran B, Denis M, et al. Human immunodeficiency virus-related lymphocytic alveolitis. *Chest* 1988;94:1264-70.
- Plata F, Autran B, Martins LP, et al. AIDS virus-specific cytotoxic T-lymphocytes in lung disorders. *Nature* 1987;328:348-351.
- Ganz W, Serafini AN. The diagnostic role of nuclear medicine in the acquired immunodeficiency syndrome. *J Nucl Med* 1989;30:1935-1945.
- Price RA, Hughes WT. Histopathology of pneumocystis carinii infestation and infection in malignant disease in childhood. *Human Pathol* 1974;5:737-752.
- Stafianakis GN, Jabir AM, Beach R, et al. Increased gallium-67 pulmonary activity in human immunodeficiency virus (HIV) positive non-AIDS, non-ARC, non-iv drug abusers: correlation with tobacco smoking. *J Nucl Med* 1989;29:829.