NUCLEAR MEDICINE ADVANCING TO FACE EPIDEMIC OF AIDS

Nuclear imaging modalities have proven themselves as clinical mainstays in managing opportunistic infections. Will they also find a clinical role in managing AIDS dementia?

NUCLEAR MEDICINE HAS gained prominence in the clinical management of AIDS. The virulence of secondary AIDS infections and the non-specific signs until they are staunchly established redoubles the urgency for early detection and diagnosis so that doctors can hasten appropriate treatment. Nuclear techniques have an edge; they detect early physiological changes, which occur well before structural lesions can be seen in anatomical studies. Gallium-67 (^{67}GA) scintigraphy, for example, is a mainstay for reliable and sensitive detection of Pneumocystis carinii pneumonia (PCP), tuberculosis, and other infections common with AIDS.

"We have enormous confidence in our contribution to diagnosis of opportunistic infection," says Elissa L. Kramer, MD, assistant director of nuclear medicine at Tisch Hospital/Bellevue Hospital Center in New York City and associate professor of clinical radiology at the New York University School of Medicine. "We can look at a gallium scan and say this is what needs to be done now." Recent findings offer largely untapped promise from other nuclear modalities, such as indium-111 leukocyte imaging. One of the foremost challenges for nuclear medicine, however, will be tailoring PET and SPECT for clinically useful imaging of AIDS dementia complex.

An Indispensable Scan

In 1985, *Newsline* reported nuclear physicians' hopes that more institutions would adopt gallium scans for routine use in PCP detection and follow-up. Today the gallium scan is "indispensable" when the patient's condition affords the 48 to 72 hours needed to obtain the results, says infectious disease specialist Tobias C. Samo, MD. "If you get a gallium scan and the chest lights up, then it's PCP until proven otherwise," says Dr. Samo, an assistant clinical professor in the department of internal medicine, Baylor College of Medicine, Houston, Texas. A negative scan rules out PCP and the need for invasive bronchoscopy. Exhaustive reviews of the use of ^{67}Ga scintigraphy in AIDS treatment have shown the scan to be much more sensitive to lung inflammation and infection than x-rays.

Gallium has proven worthy in practice. "It's a way of shortcutting the whole diagnostic procedure" and directing biopsy, says NYU's Dr. Kramer. She and other doctors interviewed find whole-body gallium scans useful in guiding diagnosis of patients with non-specific symptoms such as low-grade fever. "It makes sense to do a whole body gallium scan," says Dr. Kramer. "If you're going to expose the patient to radiation, you might as well get as much information as you can." Dr. Kramer takes SPECT images of the chest along with the whole-body scan to help interpret findings.

Since 1984, Dr. Kramer has observed changes in the typical patterns of gallium scans of AIDS patients. "It used to be that PCP always looked diffuse," she says, "but not anymore." Patterns of patchy, localized uptake are now common. The new patterns likely result from the widespread preventative use of aerosolized pentamidine. The patchy patterns reveal crannies of the lungs not reached by the pentamidine.

Gallium shows no uptake in Kaposi's sarcoma, a common AIDS affliction, but this potential drawback proves useful when coordinated with x-ray results, Dr. Kramer points out. When a patient yields a positive or irregular x-ray, but a negative gallium scan, pulmonary Kaposi's sarcoma is a likely conclusion that can then be confirmed with biopsy.

Indium vs. Gallium

A complementary study to gallium imaging is the indium-111 white blood cell (^{111}In WBC) scan, a promising technique too often neglected, in the opinion of Christopher J. Palestro, MD, associate professor at Mt. Sinai School of Medicine, New York City. "Indium doesn't enjoy a very wide use," he says, "I think it's underutilized. The patient with AIDS suffers from a variety of afflictions not limited to the respiratory tract. We need the optimal diagnostic techniques for the variety of infections."

The ^{111}In WBC scan requires only 24 hours, less time than a gallium scan, and has higher specificity for infection than gallium, and unlike gallium shows no uptake by the normal bowel, making it useful in assessing abdominal infection, according to Stanley J. Goldsmith, MD, director of the deparment of physics-nuclear medicine, professor of radiology and clinical medicine, Mt. Sinai Medical Center in New York, in a recently published book chapter on nuclear medicine in the immunocompromised host *(1)*.

Dr. Palestro presented data from a study comparing the sensitivity of the two scans in over 100 patients at The Society of Nuclear Medicine's annual meeting in June. He concluded that while ^{67}Ga imaging is most useful for detecting PCP and tuberculosis, ^{111}In scintigraphy is superior to ^{67}Ga in the detection of virtually all non-lung infections that afflict AIDS patients, including sinusitis and

colitis, which is the malady second only to respiratory infection in frequency among AIDS patients.

"If the patient is presenting with respiratory signs, clearly the procedure of choice is gallium scintigraphy," says Dr. Palestro. "However, in the absence of respiratory signs, or if bacterial pneumonia is suspected, then the procedure of choice is indium-111 white blood cells." Dr. Samo says, "It's an emerging technique — I don't have a good feel for it yet," but his group at Methodist Hospital in Houston is increasingly using ^{111}In leukocytes "as a hunting expedition" in patients with fever of unknown origin.

Others are less enthusiastic about ^{111}In leukocytes. Dr. Kramer sees little need for the ^{111}In WBC scan when ^{67}Ga scintigraphy yields such useful results. "Gallium scanning is extremely cost-effective — in our view the indium scan is not cost effective and it's not as consistently good in the lungs as gallium," she says. "That's my bias, a lot of these infections are in the lungs." As for bacterial lung infections for which ^{111}In WBC scans are more sensitive, she says x-rays are usually enough to detect bacterial pneumonia.

Courtesy of Christopher J. Palestro, MD

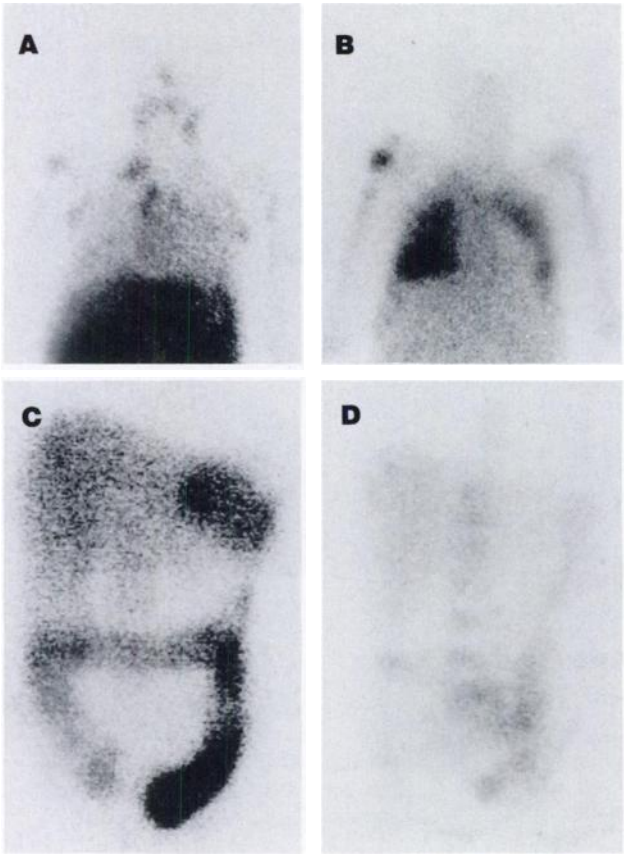

Anterior ^{111}In leukocyte image (A) of an HIV positive male shows no abnormal pulmonary uptake of labeled cells, while the ^{67}Ga image (B) of the same patient shows intense, diffuse bilateral pulmonary parenchymal uptake. Biopsy confirmed PCP. A ^{111}In leukocyte image (C) of a different HIV positive male shows intense colonic activity, while the ^{67}Ga image (D) shows no abnormal accumulation of radiotracer in the large bowel. Biopsy confirmed the presence of CMV colitis. **(C and D reprinted from *Clinical Nuclear Medicine*)**

Dr. Palestro stresses that the two studies are complementary (see figure on this page). "We're not suggesting that indium white blood cell scintigraphy replace gallium, or that it even be used as frequently as gallium, but that it has an important role." He says reluctance to handle HIV infected blood looms large in the lack of enthusiasm for ^{111}In WBC scans. Dr. Kramer cited blood handling as a problem with indium scans. The technique involves drawing blood, isolating white cells, labeling these cells, and then reinjecting them. "Admittedly, contact with HIV infected blood is to be avoided," says Dr. Palestro. "But our responsibility is to provide the optimal health care that we can."

Dr. Goldsmith believes that the cost factor turns more physicians away from ^{111}In than the necessity of handling blood. The ^{111}In technique is time-consuming and costs three times as much as ^{67}Ga scintigraphy. "Gallium is pretty good so most people are satisfied with it and are not aware of the incremental advantages of indium," he says.

"When you're dealing with infections that are characterized by polymorphonuclear leukocyte response, indium white blood cell imaging is superior to gallium, particularly in chronically ill patients," says Dr. Goldsmith. "When dealing with infections, such as PCP, that are characterized by a macrophage response, gallium scintigraphy is superior, as would be expected from the pharmacokinetics of the two agents."

Aerosol Clearance

Encouraging results with Technetium-99 DTPA aerosol are building a case for the advantages of this technique, which like ^{111}In WBC has gained limited use. The clearance of DTPA as a marker of alveolar capillary permeability may be a more sensitive, though less specific marker of lung infections than ^{67}Ga scintigraphy, according to Dr. Goldsmith. A recent French study on 88 HIV positive patients showed DTPA clearance measurements to be just that. Dr. J. Rosso, Hopital Henri Mondor, Creteil, France, presented the data at SNM's annual meeting in June.

The French researchers performed 100 scans and clearance measures. In ten cases DTPA clearance was accelerated while chest x-ray, arterial blood gases, and even ^{67}Ga scans were normal. Dr. Rosso suggests the test will find use in directing care for patients with very mild symptoms and normal x-ray. Dr. Goldsmith points out that radioaerosol imaging has been used to evaluate the efficacy of aerosol delivery systems of drugs like pentamidine for PCP.

None of the physicians interviewed for this report routinely perform DTPA clearance measurements on AIDS patients. "The aerosol would be a quick test to see if a patient has something going on in the lungs," says Dr. Kramer. "But it's nonspecific and you don't get the advantage of the other information yielded

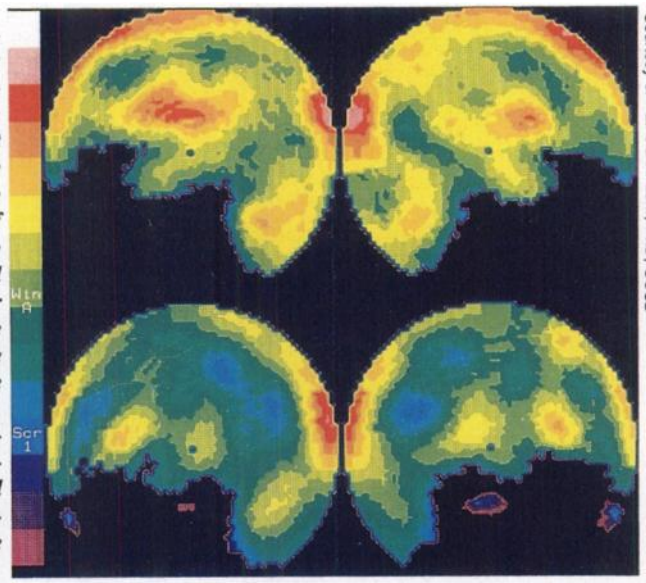

Courtesy of Patricia P. Lehr, PhD, UCSD

SPECT IMP brain images reveal differences between a control subject (top panels) and an HIV positive subject (bottom panels). The images display the outer cortical layer of each hemisphere of the brain as if peeled and flattened. The further the color is toward the white end of the scale (left), the greater the uptake of I-123 IMP. The HIV positive subject shows more variability in uptake, and overall decreased uptake compared to the control.

by a gallium scan." Dr. Rosso also notes the nonspecifity of the test and adds that results will be abnormal in the lungs of cigarette smokers.

Imaging Dementia

The nuclear imaging modalities have seized the forefront in looking for opportunistic infections brought on by HIV, but not in scanning the brain for HIV's two-pronged attack on the central nervous system. HIV effects the brain indirectly by unleashing a host of opportunistic infections and tumors, and by direct infection of nerve cells. This direct HIV action is thought to cause AIDS dementia complex, a condition that leads to patterns of severe motor function and cognitive abnormalities.

Computed tomography (CT) and magnetic resonance imaging (MRI) are used more frequently than nuclear imaging in assessing the secondary consequences of HIV — infections and tumors. But nuclear scans hold the most promise for dealing with AIDS dementia complex, according to Ronald L. Van Heertum, MD, chief of nuclear medicine at St. Vincent's Hospital and Medical Center in New York City and professor of clinical radiology, New York Medical College. As more studies are completed, a significant role for nuclear scans is taking shape, he says, especially in correlation with anatomic studies, either CT or MRI.

PET, SPECT Reveal Changes Earlier

The presentation of AIDS dementia can be so subtle as to defy early diagnosis. The symptoms typically run from mental fatigue, loss of attention span and interest in work, to paranoid ideation. But early diagnosis may well be possible with positron emission tomography (PET) and single-photon emission computed tomography (SPECT).

Dr. Van Heertum and collegues have used SPECT to detect AIDS dementia complex. His group finds SPECT helpful in staging HIV positive patients with and without signs of dementia. "In our experience with SPECT there has been a good correlation between cortical and white matter abnormalities and cognitive and motor-sensory abnormalities, and excellent correlation between cortical and white matter abnormalities and clinical severity of the illness," he says. "The SPECT scan really tells us in some great detail what's actually going on with the patient — it is a good marker to follow patients as they are treated." Further studies are needed, he notes, to affirm the role of SPECT.

Many hopes for SPECT and PET hinge on the resolution of one question: can these modalities detect signs of dementia in asymptomatic but HIV positive patients before psychological tests can? "The results to date are promising," says Dr. Van Heertum, "but I don't think that can be stated definitively." Affirmation would clear the way for routine clinical use of SPECT and PET in managing AIDS dementia.

Tantalizing Findings

"Maybe functional brain imaging will be more sensitive in the early stages than neuropsychometric testing," says Dr. Kramer. "It's too early to tell." There are a number of tantalizing findings.

One recent cross-sectional study of 48 patients tentatively concludes that SPECT scans reveal brain abnormalities before clinical signs appear (see figure on this page), and that these abnormalities may be reversible with zidovudine (AZT). "We're very excited about it," says Renee M. Dupont, MD, assistant professor of psychiatry at the University of California, San Diego, and staff physician at San Diego Veterans Administration Medical Center, who

Many hopes for SPECT and PET hinge on the resolution of one question: can these modalities detect signs of dementia in asymptomatic but HIV positive patients before psychological tests can?

"There are a number of studies in progress assessing the use of PET clinically, but it's too early to say that there is a clear-cut role in managing AIDS dementia."

completed the study along with Samuel Halpern, MD; Guy Lamoureux, MD, PhD; Igor Grant, MD; and Patricia P. Lehr, PhD. Dr. Dupont presented the results at SNM's annual meeting in June.

The linking of AZT therapy to normalized SPECT scans could prove quite important, if longitudinal follow-up shows that cognitive deficits are reversed by AZT in parallel with reversal of SPECT abnormalities. Says Dr. Dupont: "If normalization of scans is due to adequate doses of AZT and AZT leads to clinical improvement, then SPECT could be used to determine adequate dosages of AZT."

Definitive Studies Needed

The preliminary study draws its conclusions from cross-sectional analysis of 48 patients. Patients who had been treated with AZT for more than six months yielded relatively normal scans. Patients at similar disease stage but fewer months on AZT showed more abnormalities, that is, significantly reduced mean cortical uptake of iodine-123 iodoamphetamine (IMP). This study and others have shown that HIV positive patients without evidence of clinically significant cognitive impairment show reduced IMP uptake. Dr. Dupont and colleagues plan to follow the same 48 patients for the next five years to see if brain abnormalities detected prior to starting AZT improve. Dr. Dupont believes this longitudinal study will help determine the clinical worth of SPECT in assessing treatment of AIDS dementia.

SPECT studies of AIDS dementia rely on a chain of assumptions that make some investigators uneasy. "We hope that the decreases in IMP uptake are reflecting decreases in perfusion, which in turn indicate decreases in brain function," says Dr. Dupont. It's possible, however, that HIV more directly interferes with blood perfusion or the biodistribution of IMP. Nevertheless, researchers see promise in SPECT for differential diagnosis of AIDS dementia and predicting outcomes, that is, finding typical SPECT patterns that indicate which patients will likely develop dementia.

Like SPECT, PET remains a clinical research tool in studying AIDS dementia. "There are a number of studies in progress assessing the use of PET clinically, but it's too early to say that there is a clear-cut role in managing AIDS dementia," says PET investigator David A. Rottenberg, MD, chief neurologist at the Minneapolis Veterans Administration Medical Center and professor of neurology at the University of Minnesota.

A patient's history and examination are more sensitive than PET in detecting signs of AIDS dementia, Dr. Rottenberg says. But he and his colleagues are testing the hypothesis that there are PET measures, which can be used as prognostic indicators, that precede neuropsychometric indicators.

Metabolic Potholes

PET scans showing uptake of fluorine-18 fluorodeoxyglucose (FDG) in HIV positive patients yield two kinds of results, according to Dr. Rottenberg. The first are diffuse, non-specific abnormalities in glucose metabolism — Dr. Rottenberg calls them "metabolic potholes." The metabolic potholes probably reflect multifocal infarctions from secondary infections rather than any direct viral infection. A second type of pattern, however, Dr. Rottenberg believes can be used to define the metabolic fingerprint of AIDS dementia. "We think these things are specific for AIDS dementia and correlate with neuropsychology findings," he says.

The AIDS dementia pattern begins with early accelerated metabolism across subcortical brain structures, the basal ganglia and thalamus. This early hypermetabolism gives way to hypometabolism in both cortical and subcortical regions. "This pattern exists to variable extent in relation to the severity of the dementia," says Dr. Rottenberg. An index he has developed to weigh the PET patterns shows that the hypothesized metabolic fingerprints of AIDS dementia correlate snugly with neuropsychology tests.

These preliminary findings suggest that certain PET patterns might be useful for following therapy, or marking patients at

(continued on page 28N)

An index developed to weigh PET patterns shows that the hypothesized metabolic fingerprints of AIDS dementia complex correlate snugly with neuropsychology tests.

Tetalman

(continued from page 22N)

approaches that are used today. Several of her published papers on the radiation dosimetry of labeled compounds remain standard references.

Dr. Kearfott continues to pursue better protocols for PET. She is most interested in developing ways for doctors to scan and sample to get information they want. She believes that these protocols will be crucial to the role PET will play in a clinical setting. "It's exciting to see an imaging technique go from research to making a difference in hospitals concerned with diagnosing diseases. And to watch it grow from childhood to a healthy adolescence in only ten years. . ."

Dr. Kearfott was born in Oakland, California in 1956. She took a master's degree in nuclear engineering at the University of Virginia and a doctorate at M.I.T. After her work at Sloan-Kettering, she came to Arizona State University, moving from assistant to associate professor in 3 years. With limited resources, she designed a biomedical engineering program located between the main campus and the medical school.

Sought-After Speaker

Dr. Phelps says that Dr. Kearfott is a sought-after keynote speaker at conferences. "I've always been impressed when I watch her give a presentation," he says, "she is a person of great integrity and honesty. She knows what's what. She's able to present rigorous scientific information in a way that captures the audience's attention. She also helps the public see the good in nuclear medicine so that they are no longer afraid of it."

Several doctors who recommended Dr. Kearfott for the Tetalman award noted her talent in securing funds for large projects. She has succeeded in finding many forms of support, from NIH to commercial companies to private contributors.

Dr. Kearfott is the eleventh winner of the Tetalman award, which commemorates Dr. Marc Tetalman, a highly respected clinician and researcher who was killed in a robbery at an annual SNM meeting in 1979. Every year the prize is given to the nuclear medicine investigator under the age of 36 who is judged "most promising."

Dr. Kearfott says she is spending most of her time lately teaching and developing a radiological engineering training program based at Georgia Tech and roughly one-quarter working on quantitative SPECT and planning a new PET facility with a radiation protection design at Emory University.

"Dr. Kearfott has a tremendous belief in and passion for what she does," Dr. Phelps says. "She will always find a way — she's very self-reliant."

Alysa L. Zelman

Facing AIDS

(continued from page 20N)

high risk for developing dementia. "If there is a pattern that would indicate risk, then you might start patients on as vigorous a treatment as possible," says Dr. Rottenberg. "We don't even know yet what the risk factors are for developing dementia other than the infection itself."

Although cautious, Dr. Rottenberg is enthusiastic about the potential of PET. Experimental results thus far have yielded insights into the way HIV causes dementia. "There is a lot of dispute about how AIDS produces the dementia," says Dr. Rottenberg. "We believe the virus itself is important." Researchers have proposed that toxic products of the infection, or the body's own immunologic reactions to the virus, rather than viral invasion and replication, are responsible for AIDS dementia complex. Evidence against direct viral action comes from examination of brain tissue from AIDS victims. "You don't see all that much evidence of viral infection," says Dr. Rottenberg. The PET evidence, however, indicates that the virus somehow subverts cellular metabolism, he says. "We don't know the biochemical details, but the PET patterns we've pulled are consistent with viral infection."

It's also possible that the virus, the immune system, toxic byproducts, and other factors conspire to cause dementia. "There are probably multiple etiologies," says UCSD's Dr. Dupont. PET or SPECT may prove clinically useful in distinguishing these etiologies. Both techniques, however, remain far from clinically useful in managing AIDS patients, she and other researchers agree, until more studies are completed.

Anti-Retroviral Probes

Even farther from clinical application is the use of radiolabeled probes for the presence of the virus itself. Dr. Rottenberg and colleagues are developing what he called an "anti-retroviral probe" to visualize the primary infection. He declined to give further details of the project because the work is in a very preliminary stage. Such a probe might, for example, allow researchers to correlate PET and SPECT images of presumed viral effects on brain metabolism with images of the actual viral distribution.

Despite these promising, forward-looking studies, for practical purposes, reminds Dr. Kramer of NYU, "A physical neuropsychometric exam is still a lot cheaper than PET — although it may not be as pretty or elegant." Nuclear medicine scans have attained critical importance in the management of AIDS related opportunistic infections. Perhaps, she allows, functional brain imaging of AIDS dementia will as well.

J. Rojas-Burke

Sources

(1) Masur, Parillo, Pizzo, Shellhamer: *Respiratory Disease in the Immuno-Compromised Host.* Philadelphia, J.B. Lippencott, 1991.