

## Liver Uptake with Phytate Colloid in Normal Subjects and Patients with Cirrhosis: A Possible Alternative to Extrahepatic Measurements

**TO THE EDITOR:** We have read with great interest the article of D. Picard et al. (1) and would like to comment upon it.

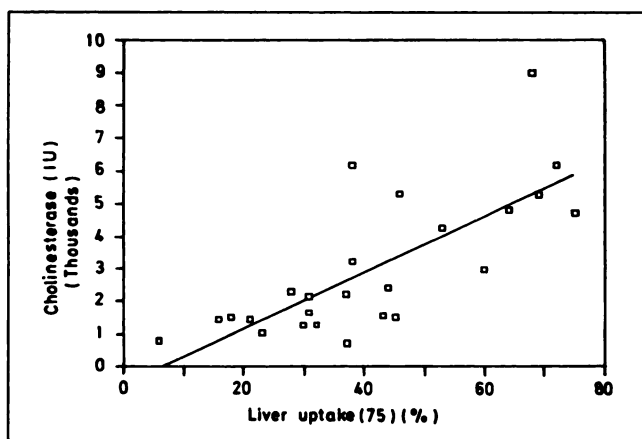
We also use  $^{99m}\text{Tc}$ -phytate colloid for liver scintigraphy to assess parenchymal function, in that these images are easier to interpret than sulfur colloid for extrahepatic uptake. We have employed an analysis similar to that of Huet et al. (2).

In order to see if we could improve our assessment, we carried out an experiment with quantification of liver uptake, correlating it to biochemical function tests, two of which were used in the Pugh score (3). Ten normal subjects (eight males and two females, mean age  $\pm$  s.d.  $42 \pm 26$  yr, range: 15–86) and 15 patients with liver cirrhosis (nine males and six females, mean age  $59 \pm 12$  yr, range: 40–72) were included in the study. After clinical evaluation, ultrasound was performed to obtain the distance from skin-to-center of the right lobe for use in attenuation correction. The patients then underwent liver scintigraphy with 7–12 mCi of  $^{99m}\text{Tc}$ -phytate colloid in a gamma camera with a high-resolution collimator (Ohio 410, Sigma) and computer (PDP 11/34). The dose and residual activity in the syringe measured in a dose calibrator were used to calculate the net administered radioactivity. The site of injection was monitored to rule out extravascular radioactivity.

Thirty minutes after tracer injection, regular images of the liver were obtained in the camera. The anterior view was stored in the computer for quantification. After the liver scan acquisition, a 1-mCi dose of  $^{99m}\text{Tc}$  in a plane-sensitivity phantom (4), placed on the camera detector, also was acquired. A region of interest (ROI) was drawn on the liver and a second rectangular ROI above the first was used as background. The counts in the liver ROI were corrected for decay, subtracted from background, and finally corrected for attenuation as follows:

$$\text{Corr. Counts} = \frac{\text{Non-Corr. Counts}}{-0.153 * 0.75 * d}$$

where, Corr = corrected; d = skin-to-center of right lobe distance in cm; and 0.153 = linear attenuation coefficient of  $^{99m}\text{Tc}$  in soft tissue.



**FIGURE 1.** Liver uptake and plasma cholinesterase correlation. The regression equation was  $y = -534 + 86x$  ( $r = 0.75$ ;  $p < 0.0001$ ) (see text).

Because the shape of the liver is irregular, with the left lobe more anterior, 75% of the depth value was arbitrarily employed for attenuation correction. Otherwise, values above 100% for liver uptake are obtained in some normal patients. The activity registered from the phantom ROI was used to calibrate the injected dose in terms of camera counts. Liver uptake was expressed as percentage of the administered counts (mean  $\pm$  s.d.).

The mean liver uptake in normals was  $58\% \pm 14\%$  and in the patients with cirrhosis it was  $29\% \pm 11\%$  ( $p < 0.0001$ ). The regression equation between liver uptake and cholinesterase for the whole group was  $y = -534 + 86x$  ( $r = 0.75$ ;  $p < 0.0001$ ) (Fig. 1). The correlation coefficient between liver uptake and serum albumin was  $r = 0.72$  ( $p = 0.00001$ ) and  $r = 0.69$  ( $p = 0.001$ ) for prothrombin.

Our results demonstrate a good correlation between reticulo-endothelial uptake and polygonal cell function tests. We believe that although the latter generally represents parenchymal function more adequately, the former may also be of value to assess functional reserve in chronic liver disease, which would be in agreement with Dr Picard's conclusions. Perhaps such an index could also be of good utility for the evaluation of prognosis in liver cirrhosis.

Liver scans can complement uptake quantification, thus making the exam more objective. In this way, a direct index of liver uptake can be determined, rather than an indirect one, such as extrahepatic colloid uptake, spleen/liver ratio, or right-to-left hepatic lobe ratio that other researchers have reported (5, 6).

Certainly this approach may be not as accurate as that published by Herzog et al. (7), but it is easier to do and can be improved in the future, e.g., combining it with tomographic techniques.

## REFERENCES

1. Picard D, Infante-Rivard C, Villeneuve JP, Chartrand R, Picard M, Carrier L. Extrahepatic uptake of technetium-99m-phytate: a prognostic index in patients with cirrhosis. *J Nucl Med* 1990;31:436–440.
2. Huet PM, Chartrand R, Marleau D. Extrahepatic uptake of Tc-99m-phytate: its mechanism and significance in chronic liver disease. *Gastroenterology* 1980;78:76–80.
3. Pugh RNH, Murray-Lyon IM, Dawson JL, Pietroni MC, Williams R. Transsection of the esophagus for bleeding oesophageal varices. *Br J Surg* 1973;60:646–649.
4. International Atomic Energy Agency. IAEA-TECDOC-317. *Quality control of nuclear medicine instruments*. Vienna: IAEA;1984:151.
5. Shreiner DP, Barlai-Kovach M. Diagnosis of alcoholic cirrhosis with the right-to-left hepatic lobe ratio: concise communication. *J Nucl Med* 1981;22:116–120.
6. Preston DF, Smith MA, Hayes D, et al. Identifying hepatocellular disease by measuring spleen/liver ratios [Abstract]. *J Nucl Med* 1986;27:1012.
7. Herzog H, Spohr G, Notohamiprodjo G, Feinendegen LE. Absolute quantification of pharmacokinetics distribution of RES colloids in individuals with normal liver function. *Nucl Med Commun* 1987;8:157–175.

Patricio Gonzalez  
 Pamela Humeres  
 Alejandro Arroyo  
 Clinical Hospital, University of Chile  
 Santiago, Chile

**REPLY:** We agree with Gonzalez et al. that the determination of a direct quantitative index of liver uptake may be of value to assess liver functional reserve. However, in our experience, determination of the extra-hepatic uptake (EHU) index was very reproducible between observers. In fact, the maximum difference