

Radiation Injury from Interstitial Injection of Iodine-131-Iodocholesterol

TO THE EDITOR: A 44-yr-old man was investigated for recurrent Cushing's disease. An adrenal gland scan was initiated with injection of 34-MBq of ^{131}I -iodocholesterol over a 5-min interval. Prior to injection, blood was withdrawn into the hub of the syringe to ensure correct i.v. placement. At the conclusion of the injection, the patient volunteered that the injection had been the least painful i.v. entry he had experienced. Seven days later, imaging failed to detect any radioactivity in the field of view centered on the adrenal glands. Monitoring of the injection site demonstrated essentially complete retention of the radiopharmaceutical at the site.

The patient returned 13 days later (i.e., 20 days after the injection) to inquire about the tender pruritic and erythematous patch at the injection site at which time the photograph in Figure 1 was taken. At the injection site, he had an erythematous patch

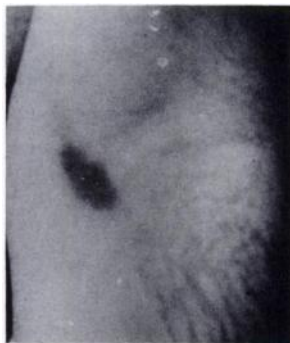

FIGURE 1
Radiation burn evident by inspection 20 days after injection.

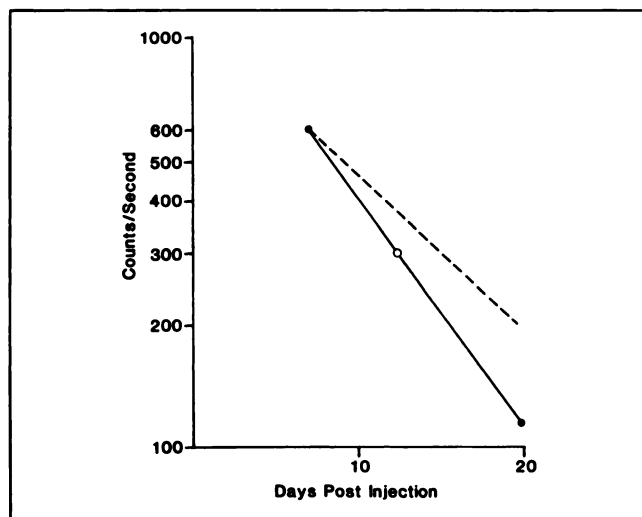


FIGURE 2. Retention of ^{131}I -iodocholesterol at the site of interstitial injection. The solid points (•) represent measurement of radioactivity over the site. The open circle (○) represents one half-time from the first measurement. The dotted line represents the decay of ^{131}I .

measuring approximately 2 cm × 1 cm. Monitoring of the site demonstrated retention of ^{131}I (Fig. 2). On the basis of serial counts, the half-time was 5.5 days at the i.v. injection site.

The absorbed dose delivered to the overlying skin cannot be precisely calculated because it has a very strong inverse dependence on the interstitial volume occupied by the injectate, and this volume is not accurately known. The absorbed dose can be estimated by treating the interstitial volume occupied by the injectate as a disk of the same area as the erythematous patch; the thickness of this volume can be roughly estimated. The volume of distribution was assumed to remain constant over time since the injectate is not water-soluble. The absorbed dose in this volume can be calculated by the method of Johns and Cunningham (1). Because the model assumes no activity outside the volume, the absorbed dose in the region adjacent to this volume within the range of the beta particles (i.e., the skin) can be estimated to be half the dose inside the volume. Using interstitial volumes with thicknesses of 0.5 cm and 1 cm, the dose to the skin was calculated as 490 Gy and 245 Gy, respectively. However, the most sensitive cells of the deepest dermal layer will not have been uniformly within the range of the beta particles. Only the deepest cells in the rete pegs will have been irradiated to the dose calculated from the model. The result of this microscopic scale inhomogeneity will be to decrease the average skin dose by an indeterminate factor.

This experience demonstrates a nonstochastic radiation injury from a diagnostic dose of ^{131}I -iodocholesterol. Moreover, the importance of administering a totally i.v. injection of this water-insoluble radiopharmaceutical is emphasized.

REFERENCE

1. Johns HE, Cunningham JR. *Physics of radiology*, third edition. Springfield, IL: Charles C. Thomas; 1969:570.

S.L. Breen
A.A. Driedger
Victoria Hospital
London, Ontario, Canada

Cardiac Clinical Utility of Fluorinated Deoxyglucose

TO THE EDITOR: The position of The Society of Nuclear Medicine (SNM) and of the American College of Nuclear Physicians (ACNP) on PET-FDG cardiac studies was recently reviewed in *JNM* by Alazraki (1).

The issue as discussed by Dr. Alazraki is whether FDG has efficacy for detecting coronary artery disease and for determining myocardial viability. Incidentally, there must have been a communication problem with this assertion since perfusion tracers, not FDG, are the ones used for detection of coronary stenoses.

The issue of the efficacy of FDG to determine myocardial viability is complex and is far from resolved. From this standpoint alone, the positions of the SNM and of the ACNP need revision.