
Thallium-201 Scintigraphy in Differentiated Thyroid Cancer: Comparison with Radioiodine Scintigraphy and Serum Thyroglobulin Determinations

Lalitha Ramanna, Alan Waxman, and Glenn Braunstein

Department of Nuclear Medicine and Department of Medicine, Cedars-Sinai Medical Center, Los Angeles, California

The role of thallium-201 (^{201}Tl) scintigraphy in the follow-up evaluation of differentiated thyroid carcinoma (DTC) is controversial. Desirable characteristics of ^{201}Tl scintigraphy including the potential for no thyroid hormone withdrawal, immediate imaging postinjection, and low radiation burden relative to iodine-131 (^{131}I) suggests it is logistically superior to ^{131}I scintigraphy. Fifty-two patients with DTC were evaluated with ^{201}Tl and ^{131}I neck and chest images, and serum thyroglobulin measurements. In post-thyroidectomy and pre- ^{131}I ablation therapy patients, very little ^{201}Tl accumulation was noted within the thyroid bed, with discordantly increased ^{131}I activity and normal serum thyroglobulin measurements. Twenty-nine percent of patients evaluated after ^{131}I ablative therapy had elevated serum thyroglobulin levels and localized neck and chest abnormalities on ^{201}Tl scan that were not seen on ^{131}I studies. Our data suggest that ^{201}Tl is more sensitive than ^{131}I diagnostic (5 mCi) studies for detection of DTC, while ^{131}I is more sensitive in detecting normal residual thyroid tissue postoperatively.

J Nucl Med 1991; 32:441-446

Despite some controversies, the treatment of differentiated thyroid cancer (DTC) includes removal of thyroid tissue by a combination of surgery and iodine-131 (^{131}I) ablation therapy followed by replacement thyroid hormone. This approach is associated with decreased recurrence rate of carcinoma and probably increased survival (1-5).

Radioiodine scintigraphy is widely used and recommended for follow-up evaluation of DTC patients to detect residual, recurrent, or metastatic disease. Radioiodine scintigraphy has several disadvantages, including the need for thyroid hormone withdrawal which results in a finite period of hypothyroidism. In addition, ^{131}I localization in the thyroid bed is not specific for tumor.

Following the development of radioimmunoassay techniques for serum thyroglobulin (Tg) determinations, there have been several reports regarding the role of serum Tg in the follow-up and management of patients with DTC (6-21). It is generally accepted that significant elevations in Tg usually reflect the presence of recurrent or metastatic thyroid carcinoma (6-21).

The use of thallium-201 (^{201}Tl) has been reported in the follow-up evaluation of DTC (22-24) with conflicting results. Thallium scintigraphy theoretically has several advantages over ^{131}I . The examination does not require thyroid hormone withdrawal and can be performed immediately after injection requiring less than one hour of study time. Radiation exposure is acceptably small (25).

The purpose of the present study is to evaluate ^{201}Tl scintigraphy independently and in conjunction with serum Tg determinations and compare the results to ^{131}I diagnostic studies in patients with DTC and to determine if ^{201}Tl scintigraphy has a role in the follow-up evaluation of thyroid carcinoma patients.

MATERIALS AND METHODS

Fifty-two patients with DTC had 72 sets of ^{131}I studies, serum Tg determinations, and ^{201}Tl scans. The patient population consisted of 34 females and 18 males ranging in age from 16-76 yr. Histologically, 37 had predominant papillary carcinoma, 7 had predominant follicular elements, and the remaining 8 had a mixed pattern. In 21 patients, ^{131}I and thallium scans were obtained prior to ^{131}I ablation therapy 4-6 wk following a near total thyroidectomy. Thirty-one patients were studied with ^{131}I and thallium 8-12 mo following ^{131}I ablative therapy.

Surgical Considerations

All patients underwent a total thyroidectomy with lymph node sampling when possible. Surgical information was obtained from the surgeon directly regarding outcome of the procedure, including incomplete resection of tumor.

Radioiodine Scans

Scans were obtained 48 hr following oral administration of 5 mCi of ^{131}I using a state-of-the-art Anger camera with a

Received Dec. 17, 1989; revision accepted Sept. 12, 1990
For reprints contact: Lalitha Ramanna, MD, Cedars-Sinai Medical Center, Department of Nuclear Medicine, 8700 Beverly Blvd., Room A042, Los Angeles, CA 90048.

high-energy collimator. Ten-minute spot images were obtained of the head, neck, chest, abdomen, and pelvis. All thyroid medications were discontinued 6 wk prior to the scan and replaced by triiodothyronine. Two weeks prior to the scan study, triiodothyronine was stopped. It has been previously demonstrated that this protocol results in near maximal endogenous TSH elevations (26–28). TSH measurements were done in all cases prior to therapy, patients were treated if TSH values were >35 uU/ml.

Thyroglobulin Measurements

Blood samples for serum Tg assays were drawn prior to any radiotracer administration while the patients were off their thyroid hormone therapy. The Tg levels were determined by a sensitive radioimmunoassay by Endocrine Sciences Laboratory (29). The sensitivity of the assay is 2 ng/ml with prior screening of serum for anti-thyroglobulin antibodies.

Thallium-201 Scans

Two minutes following an i.v. administration of 3 mCi ²⁰¹Tl, two 15-min anterior neck and chest images were obtained consecutively followed by a 10-min posterior image of the chest and a repeat 15-min anterior neck/chest image 60 min postinjection. An image with markers placed at the level of suprasternal notch and chin was also obtained for the purpose of defining the thyroid bed. A large field of view state-of-the-art Anger camera with a 3/8-in. sodium iodide crystal and a low-energy all purpose collimator was used.

In all patients, the thallium study was performed while the patients were still on full thyroid hormone replacement therapy. In the 31 postablation patients, ²⁰¹Tl scans were done 6 wk prior to the diagnostic ¹³¹I studies. In the 21 postsurgical, non-ablated patients, ²⁰¹Tl scans were done 1–4 days prior to the ¹³¹I study.

Interpretation of Results

Thallium-201 and ¹³¹I scans were visually read as positive when increased focal activity was present with respect to background activity. Serum Tg levels were considered abnormal in these thyroidectomized patients if the values were >10 ng/ml (21).

RESULTS

Serum Tg and scan results in 21 patients who had studies following thyroidectomy but prior to ¹³¹I ablation therapy are summarized in Table 1. Six of these patients, had no detectable ²⁰¹Tl activity despite marked focal ¹³¹I accumulation within the thyroid bed. An example is shown in Figure 1. Tg evaluations in this group were less than 10 ng/ml. Seven patients in this group demonstrated mild diffuse thallium activity in

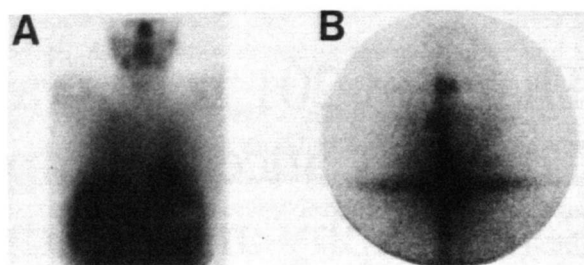


FIGURE 1

A 3-mCi ²⁰¹Tl study (A) and a 48-hr 5-mCi ¹³¹I study (B) in a patient 4 wk following “total” thyroidectomy for differentiated thyroid cancer. Note the lack of significant ²⁰¹Tl accumulation within the neck and the markedly increased ¹³¹I accumulation. This discordant pattern was present in 13 of 21 patients who had undergone “total” thyroidectomy and had not yet received ablative ¹³¹I therapy.

the neck, which appeared markedly discordant from ¹³¹I studies where marked focal ¹³¹I accumulation within the thyroid bed was present. Two of these patients had Tg values >10 ng/ml. In eight patients, focal areas of ²⁰¹Tl accumulations were concordant with marked accumulation noted on ¹³¹I studies. Three of these patients had serum Tg values >10 ng/ml. Patients were known to have DTC residual following surgery. Figure 2 is an example of a patient with markedly elevated serum Tg. (Tg = 990 ng/ml).

In a separate sub-group of 31 patients who had prior total thyroidectomies followed by ¹³¹I ablation therapy at least 8–12 mo prior to the current studies, 51 follow-up examinations were performed. The results of ²⁰¹Tl, ¹³¹I, and serum Tg determinations are summarized in Table 2 and Figure 3. The striking finding in this group was the large number of discordant studies (19/51) in which ²⁰¹Tl examinations detected neck/chest accumulations that were not seen with 5-mCi ¹³¹I diagnostic scans. An example is shown in Figure 4. Three of these patients underwent biopsy and demonstrated DTC. The

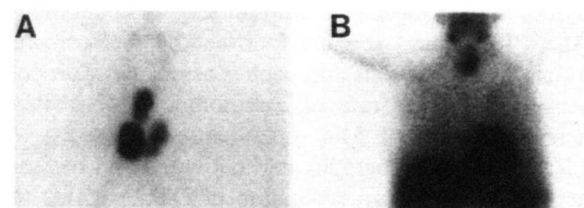


FIGURE 2

A 48-hr 5-mCi ¹³¹I scan (A) and a ²⁰¹Tl neck and chest study (B) in a patient 4 wk following total thyroidectomy demonstrates focal accumulations in the thyroid bed on both studies. The patient’s serum Tg levels were markedly elevated (990 ng/ml). The patient had known residual thyroid cancer following surgery and the studies demonstrate a concordant pattern in which both thallium and thyroglobulin were positive. This pattern was noted in 8 of 21 patients. Three of the eight patients had either known residual thyroid cancer left in the neck or markedly elevated Tg levels.

TABLE 1

Correlation of ²⁰¹Tl and ¹³¹I Diagnostic Scans and Serum Tg Values in DTC Patients Following Surgery but Prior to ¹³¹I Ablation Therapy

No. of pts.	²⁰¹ Tl uptake	¹³¹ I uptake	Serum Tg ng/ml (No. of pts)
6	0	Focal	<10 (6)
7	Mild diffuse	Focal	>10 (2)
8	Focal	Focal	>10 (3)

TABLE 2
Correlation of ^{201}Tl , ^{131}I , and Serum Tg Studies in Follow-up Evaluation of Thyroid Carcinoma in Patients Previously Treated with High-Dose ^{131}I

	Tl+ Tg+	Tl+ Tg-	Tl- Tg+	Tl- Tg-
$^{131}\text{I}+$	3	14	0	4
$^{131}\text{I}-$	16	3	4	7

serum Tg values in the 19 discordant patients ranged from 28-100 ng/ml (nl <10 mg/ml), suggesting a high likelihood for tumor.

Seven patients in the 19 patient discordant group underwent 100-150-mCi ^{131}I therapy because of markedly elevated serum Tg levels (>500 ng/ml). Five of these patients demonstrated accumulation of ^{131}I outside the thyroid bed (lung, mediastinal, and cervical lymph nodes) on the post- ^{131}I therapy scans consistent with metastatic disease. An example is shown in Figure 4. There is also additional metastasis in the lungs not detected with ^{201}Tl .

Fourteen patients who were ^{131}I and ^{201}Tl positive but Tg negative had activity confined to the area of the thyroid bed. An additional four patients demonstrated a positive ^{131}I scan and no ^{201}Tl uptake. All four had normal Tg levels and a low-level uptake of ^{131}I limited to the thyroid bed, suggesting the presence of residual normal thyroid tissue.

DISCUSSION

Iodine-131 scintigraphy has played an integral role in the management of patients with DTC. The patients generally are treated with therapeutic doses of ^{131}I until

ablation of iodine-avid tissue is achieved using diagnostic ^{131}I scans. The ^{131}I studies are especially important in the early phases of patient management so that clinicians can determine the extent of disease, including distant metastasis as well as initial therapeutic response to large doses of ^{131}I .

Many problems exist in performing the radioiodine studies. They are inconvenient to most patients in that a period of symptomatic hypothyroidism occurs. Thyroid hormonal withdrawal programs are generally required to raise the endogenous TSH levels in order to stimulate residual iodine-avid tissue, including metastasis, for optimal ^{131}I uptake and detection. It has been suggested that elevated TSH levels may stimulate thyroid carcinoma (30). The test requires at least two patient visits to the examination facility and is accompanied by a modest radiation burden. Iodine-131 cannot differentiate between normal residual thyroid tissue within the neck and DTC. The scan results are also dependent on a number of factors including dose of ^{131}I used, instrumentation, imaging time, biologic factors influencing the stimulation of residual tissue, and a number of other parameters which affect sensitivity of the scan results (31).

The possibility of utilizing other tests such as serum Tg and thallium have recently been studied with conflicting and, therefore, controversial results (22-24). Hoefnagel et al. states that thallium is a highly sensitive indicator of DTC, although not specific and, when employed in conjunction with serum thyroglobulin, the sensitivity for detection of DTC is better than that for ^{131}I . Brendel et al. in a recent report stated that thallium imaging cannot be recommended as the only modality for the follow-up of patients with DTC since ^{131}I scin-

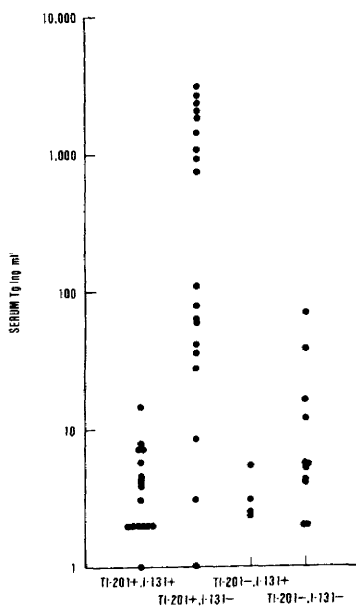


FIGURE 3
Comparison of serum Tg levels with ^{201}Tl and 48-72-hr 5-mCi ^{131}I scintigraphy in follow-up evaluation of DTC. Note the large number of patients who had ^{201}Tl positive and ^{131}I negative studies with significant elevations of thyroglobulin.

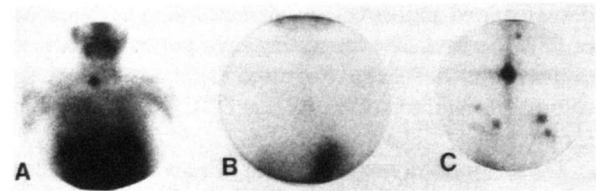


FIGURE 4
A patient with papillary carcinoma of the thyroid who had a solitary focus of ^{201}Tl accumulation in the neck (A) associated with a markedly elevated serum Tg level (>3,000 ng/ml). A 5-mCi ^{131}I diagnostic study done after thyroid hormone treatment was normal (B). Following a 150-mCi therapeutic dose of ^{131}I , multiple focal areas of increased activity were noted within the neck as well as lungs bilaterally (C).

tigraphy done with 100–150 mCi is far more sensitive (23).

In our series, there were two distinctly different patient populations. Those who had studies post-thyroidectomy, but prior to high-dose ^{131}I therapy, and those who were studied post-thyroidectomy and returned for follow-up studies 8–12 mo following at least one course of ablative ^{131}I therapy, (100–150 mCi). In the patient group who underwent ^{201}Tl scintigraphy post-thyroidectomy, but prior to ^{131}I therapy, a large percentage (13/21 = 62%) demonstrated an unexpected discordant imaging pattern with little or no ^{201}Tl accumulation seen in the thyroid bed, but marked focal accumulations present on the ^{131}I studies. This group was evaluated by competent, experienced surgeons who felt that following surgery there was no bulk tumor remaining. Tissue that was left was considered to be residual normal thyroid approximating 0.25–1.0 g in the thyroid bed. Using 5 mCi of ^{131}I , the normal residual thyroid tissue was exceptionally well demonstrated with extremely high target/non-target ratios and relatively high photon yields for purposes of scanning. In contrast, the ^{201}Tl studies in this group demonstrated minimal to no activity except in patients where there was a high suspicion of significant residual tumor based upon incomplete removal of the tumor surgically or high Tg levels. Since the normal thyroid concentrates ^{201}Tl less avidly than ^{131}I , the discordance noted between the results with the two agents may simply reflect differences in the quantity of normal tissue remaining after surgery and marked differences in tissue-to-background ratios.

In the post-thyroidectomy, post- ^{131}I ablation follow-up group (31 patients), the assumption was that very little if any normal residual thyroid tissue remained. In this group, 16 of 51 studies demonstrated focal accumulations of ^{201}Tl along with elevated serum Tg values, but normal findings on 5-mCi ^{131}I scans. In 3 of the 16 patients, direct evidence for DTC was confirmed by biopsy. An additional seven patients were given 100–150 mCi of ^{131}I and five demonstrated activity outside the thyroid bed, where ^{201}Tl was positive and 5-mCi ^{131}I was negative. These areas were considered as highly probable to contain DTC, and in three patients CT demonstrated abnormalities corresponding to the areas of ^{201}Tl increase. The remaining eight patients were not evaluated further, but as discussed they had elevated Tg values, raising the probability that DTC was responsible for increased ^{201}Tl activity.

These findings suggest that ^{201}Tl studies are more sensitive than 5-mCi ^{131}I diagnostic studies in detecting residual DTC in the post-ablative patient, but they are not more sensitive when compared to therapeutic (100–150 mCi) ^{131}I scans, which confirms the findings of Hoefnagel and Brendel (22–23). Increased sensitivity of lesion detection with increasing ^{131}I tracer doses has been reported by several groups (26,31–33).

Fourteen patients in this series demonstrated positive ^{131}I and thallium studies but had negative Tg determinations. This group had scan activity limited to the thyroid bed. It is most likely that the scan activity represents normal residual thyroid tissue which was not ablated with ^{131}I . However, because patients in this group were not biopsied, we are unable to rule out the possibility of residual DTC being present in the thyroid bed.

It has been demonstrated that thyroglobulin determinations are most sensitive in detecting DTC when the test is performed in patients who are highly TSH stimulated (13,14). If we assume that the 14 patients with iodine and thallium activity in the thyroid bed had only residual normal thyroid with no DTC, our data would suggest that Tg determinations are highly sensitive in detecting residual or metastatic DTC. A true sensitivity of Tg cannot be determined from this study, as biopsies were not taken from the 14 patients with only residual thyroid bed activity detected on thallium and iodine.

To some degree, the interpretation of the data in this study is speculative, since biopsies could not be obtained in all patients and therapeutic dose ^{131}I scans were not performed in all patients. The study demonstrates that ^{131}I scintigraphy is a significantly more sensitive test than ^{201}Tl in detecting small amounts of residual normal thyroid tissue. Conversely, ^{201}Tl was more sensitive than 5 mCi of ^{131}I in detecting residual or recurrent DTC in ^{131}I “ablated” patients who had biopsy evidence of DTC or presumptive evidence on the basis of elevated serum Tg or distant sites detected with >100 mCi ^{131}I .

The presence of pulmonary parenchymal metastasis is probably better evaluated with ^{131}I , since thallium is normally taken up by the lungs initially and is slowly cleared. Two patients imaged with thallium both early and on delayed films (1 hr postinjection) failed to conclusively demonstrate residual activity within the pulmonary parenchyma, while the ^{131}I was positive on the posttherapeutic scan doses. Tg was also markedly elevated in tissue cases.

We are currently attempting to define a strategy which would minimize the necessity for diagnostic ^{131}I scans. This would prevent patients from unnecessarily undergoing thyroid hormone withdrawal. Hoefnagel et al. determined the sensitivity for ^{201}Tl detection of residual or recurrent DTC to be 94%. The same group determined in their series that thyroglobulin had a sensitivity of 74%. The combination of both ^{201}Tl and thyroglobulin had a sensitivity of 98% and a corresponding specificity of 90%. The current study also demonstrates a high sensitivity for tumor detection using ^{201}Tl . The recurrence rate of DTC in patients who have been ablated with ^{131}I is relatively low (4,5). After ablation has been established and with the low rate of

recurrence, either thallium or thyroglobulin may be sufficient to follow patients with DTC. If the ^{131}I and ^{201}Tl studies remain negative and no unusual physical findings are evident, then no additional ^{131}I studies may be necessary.

It should be stressed that a highly reliable laboratory for Tg determinations be utilized and that thallium studies be performed using the new generation of high-resolution Anger camera equipment. In addition, a 10–15-min image of the neck and chest should be performed using at least 3 mCi of ^{201}Tl . Focal abnormalities on thallium studies or changes in the patient's clinical or laboratory status indicate the need to perform a diagnostic ^{131}I scan with appropriate endogenous stimulation.

ACKNOWLEDGMENTS

This study was supported in part by E. I. du Pont de Nemours & Co. (Grant-CG-87010).

The authors thank Joyce Jemison for her invaluable secretarial help in the preparation of this manuscript.

REFERENCES

- Krishnamurthy GT, Bland WH. Radioiodine I-131 therapy in the management of thyroid cancer: a prospective study. *Cancer* 1977;40:195–202.
- Young RF, Mazzaferri EL, Rahe AJ, et al. Pure follicular thyroid carcinoma: impact of therapy in 214 patients. *J Nucl Med* 1980;21:733.
- Varma VM, Beierwaltes WH, Nofal MM, et al. Treatment of thyroid cancer: death rates after surgery following sodium iodine I-131. *JAMA* 1970;214:1437.
- Beierwaltes WH. The treatment of thyroid carcinoma with radioactive iodine. *Semin Nucl Med* 1978;8:79.
- Mazzaferri EL, Young RL. Papillary thyroid carcinoma: a 10-year follow-up report of the impact of therapy in 576 patients. *Am J Med* 1981;70:511.
- Van Herle AJ, Uller RP. Elevated serum thyroglobulin: a marker of metastases in differentiated thyroid carcinomas. *J Clin Invest* 1975;16:272–277.
- Lo Gerfo P, Colacchio TA, Stillman T, et al. Serum thyroglobulin and recurrent thyroid cancer. *Lancet* 1977;1:881–882.
- Ng Tang Fui SC, Hoffenberg R, Maisey MN, et al. Serum thyroglobulin concentrations and whole-body radioiodine scan in the follow-up of differentiated thyroid body cancer after thyroid ablation. *Br Med J* 1979;2:298–300.
- McDougall IR, Bayer MP. Follow-up of patients with differentiated thyroid cancer using serum thyroglobulin measured by an immunoradiometric assay: comparison with I-131 total-body scans. *J Nucl Med* 1980;21:741–744.
- Pacini F, Pacinera A, Giani C, et al. Serum thyroglobulin concentration and I-131 whole-body scans in the diagnosis of metastases from differentiated thyroid carcinoma (after thyroidectomy). *Clin Endocrinol* 1980;13:107–110.
- Charles MA, Dodson LE Jr, Walceck N, et al. Serum thyroglobulin levels predict total-body iodine scan findings in patients with treated well-differentiated thyroid carcinoma. *Am J Med* 1980;69:401–407.
- Schlumberger M, Fragu P, Parmentier C, et al. Thyroglobulin assay in the follow-up of patients with differentiated thyroid carcinomas: comparison of its value in patients with or without normal residual tissue. *Acta Endocrinol* 1981;98:215–221.
- Schneider AB, Bruce RL, Goldman JM, et al. Sequential serum thyroglobulin determination. I-131 scans and I-131 uptakes after triiodothyronine withdrawal in patients with thyroid cancer. *JCEM* 1981;53:1199–1206.
- Ashcraft MW, Van Herle AJ. The comparative value of serum thyroglobulin measurements and iodine-131 total-body scans in the follow-up of patients with treated differentiated thyroid cancer. *Am J Med* 1981;71:806–813.
- Colacchio TA, Lo Gerfo P, Colacchio DA, et al. Radioiodine total-body scan versus serum thyroglobulin levels in follow-up of patients with thyroid cancer. *Surgery* 1982;91:42–45.
- Barsano CP, Skosey C, Degroot LJ, et al. Serum thyroglobulin in the management of patients with thyroid cancer. *Arch Intern Med* 1982;142:763–767.
- Galligan JP, Winship J, Van Doorn T, et al. A comparison of serum thyroglobulin measurements and whole-body I-131 scanning in the management of treated differentiated thyroid carcinoma. *Aust NZ J Med* 1982;12:248–254.
- Castagnoli A, Capelli G, E'Agata A, et al. Can thyroglobulin assay really supplant radioiodine scans in patients with differentiated thyroid cancer? *Lancet* 1982;1:573–574.
- Echenique RL, Kasi L, Haynie P. Critical evaluation of serum thyroglobulin levels and I-131 scans in post-therapy patients with differentiated thyroid carcinoma: concise communication. *J Nucl Med* 1982;23:235–240.
- Charles MA. Comparison of serum thyroglobulin with iodine scans in thyroid cancer. *J Endocrinol Invest* 1982;5:276–271.
- Ramanna L, Waxman AD, Brachman MB, et al. Correlation of thyroglobulin measurements and radioiodine scans in the follow-up of patients with differentiated thyroid cancer. *Cancer* 1985;55:1525–1529.
- Hoefnagel CA, Delprat CC, Marcuse HR, de Fijlder JJM. Role of thallium-201 total-body scintigraphy in follow-up of thyroid carcinoma. *J Nucl Med* 1986;27:1854–1857.
- Brendel AJ, Guyot M, Jeandot R, Lefort G, Manciet G. Thallium-201 imaging in the follow-up of differentiated thyroid carcinoma. *J Nucl Med* 1988;29:1515–1520.
- Ramanna L, Waxman AD, Brachman MB, Tanasescu DE, Braunstein G. Thallium-201 (Tl) and I-131 discordance in patients with differentiated thyroid CA (DTC): is there a rationale for Tl thyroglobulin (Tg) screening? *J Nucl Med* 1988;29:753.
- Atkins HL, Budinger TF, Levowitz E, et al. Thallium-201 for medical use. Part 3. Human distribution and physical imaging properties. *J Nucl Med* 1977;18:133–140.
- Waxman AD, Ramanna L, Chapman N, et al. The significance of I-131 scan dose in patients with thyroid cancer: determination of ablation: concise communication. *J Nucl Med* 1981;22:861.
- Hilts SV, Hellman D, Anderson J, et al. Serial TSH determination after T3 withdrawal or thyroidectomy in the therapy of thyroid carcinoma. *J Nucl Med* 1979;20:928–932.
- Hershman JM, Edwards L. Serum thyrotropin (TSH) levels after thyroid ablation compared with TSH levels after exogenous bovine TSH: implications for I-131 treatment of thyroid carcinoma. *Endocrinology* 1972;34:814.
- Van Herle AJ, Uller RP, Mathews NL, et al. Radioimmunoassay for measurement of thyroglobulin in human serum. *J Clin Invest* 1973;52:1320.
- Robbins J. Thyroid suppression therapy for prevention of thyroid tumors after radiation exposure. In: Degroot LJ, Frohman LA, Kaplan EL, Refetoff S, eds. *Radiation-associated thyroid carcinoma*. New York: Grune & Stratton, Inc.;

- 1977;419-431.
31. Waxman AD, Ramanna L, Chapman N, et al. The definition of ablation in patients with thyroid cancer: the effects of instrumentation and I-131 scan dose [Abstract]. *J Nucl Med* 1981;24:267-271.
32. Pacini F, Lippi F, Formica N, et al. Therapeutic doses of iodine-131 reveal undiagnosed metastases in thyroid cancer patients with detectable serum thyroglobulin levels. *J Nucl Med* 1987;28:1888-1891.
33. Balachandran S, Sayle BA. Value of thyroid carcinoma imaging after therapeutic doses of radioiodine. *Clin Nucl Med* 1981;6:162-167.

SELF-STUDY TEST

Pulmonary Nuclear Medicine

Questions are taken from the *Nuclear Medicine Self-Study Program I*, published by The Society of Nuclear Medicine

DIRECTIONS

The following items consist of a heading followed by lettered options related to that heading. Select the one lettered option that is best for each item. Answers may be found on page 474.

- In which of the following clinical situations should the number of ^{99m}Tc -macroaggregated albumin particles administered for pulmonary perfusion imaging be reduced?
 - A patient with documented pulmonary hypertension.
 - A patient who has undergone pneumonectomy.
 - An apprehensive patient who is moderately dyspneic and tachypneic and has a mildly depressed arterial pO_2 on room air.
 - A patient with chest pain and a known, long-standing ventricular septal defect.
 - A patient in the respiratory intensive care unit who is intubated and gravely ill.
- True statements concerning the sequence of ventilation and perfusion imaging include:
 - Xenon-127 ventilation imaging can be performed after ^{99m}Tc perfusion imaging because the energy of the principal ^{133}Xe photons is higher than that of the primary ^{99m}Tc photon.
 - If ^{133}Xe imaging is performed after a ^{99m}Tc study, simple computer processing readily permits subtraction of the ^{99m}Tc scatter contribution from the ^{133}Xe image.
 - An important advantage of performing a perfusion study before ventilation imaging is that the ventilation study can be avoided if the perfusion images are normal.
 - If ^{133}Xe imaging is performed after the ^{99m}Tc study, interference from the background technetium activity can be obviated by use of a 3-mCi dose of ^{99m}Tc and a 10-mCi dose of ^{133}Xe .
 - When ^{81m}Kr is employed, it is desirable to obtain alternating krypton and technetium image pairs in each of the standard projections.
- Perfusion images show complete absence of perfusion to one lung with normal perfusion to the other lung. The clinical suspicion of pulmonary embolism is low. Which of the following possibilities are moderately or highly likely explanations for these findings?
 - pneumonectomy
 - complete collapse of one lung
 - a hilar mass not evident on standard chest radiograph
 - pulmonary embolism
- True statements concerning the perfusion defect seen in the right lower lobe of the study shown in Figure 1 include:
 - Acute pulmonary embolism is an unlikely cause.
 - This appearance occasionally is seen with resolving pulmonary embolism.
 - It is most likely due to centrally located emphysema.

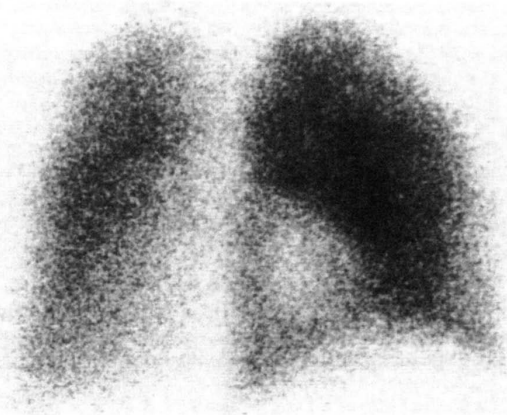


FIGURE 1

(continued on p. 474)