
Proposal of a Modified Scintigraphic Method to Evaluate Duodenogastroesophageal Reflux

Nicoletta Borsato, Luigi Bonavina, Pierluigi Zanco, Biagia Saitta, Franca Chierichetti, Alberto Peracchia, and Giorgio Ferlin

The Division of Nuclear Medicine, Castelfranco Veneto Hospital, Castelfranco Veneto, Italy, and the First Department of Surgery, University of Padua Medical School, Padova, Italy

Hepatobiliary scintigraphy with ^{99m}Tc -HIDA offers a noninvasive method to detect duodenogastric reflux. Biliary reflux was graded using the persistence rather than the intensity of the radioactive refluxate: Grade 0 was considered the absence of reflux, minimal reflux, or reflux in the first 10-15 min; Grade 1 was repetitive reflux lasting less than 10 min; Grade 2 was persistent reflux; and Grade 3 was reflux up to the esophagus. Twenty-five patients with foregut symptoms were studied and results were compared to 24-hr gastric pH monitoring. Scintigraphy and pH monitoring agreed in 15 out of 25 patients (60%), but no correlation was found with the endoscopic findings. The rationale for this approach is based on pathophysiologic evidence that damage to gastric and/or esophageal mucosa is mainly related to the prolonged contact time with duodenal contents. This technique seems to allow a complete functional evaluation of the esophagogastrroduodenal tract without causing adjunctive irradiation or discomfort to the patient.

J Nucl Med 1991; 32:436-440

The role of bile and pancreatic juice in the pathogenesis of dyspeptic symptoms and mucosal lesions of the stomach and esophagus has been extensively investigated. Reflux of alkaline duodenal contents into the stomach and eventually into the esophagus occurs either in patients with intact gastrointestinal tracts or in postgastrectomy conditions (1).

Hepatobiliary scintigraphy using ^{99m}Tc -HIDA derivatives offers a simple, noninvasive method to demonstrate duodenogastric reflux. Several indices have been proposed to give an objective evaluation of reflux. In general, radioactivity present in the gastric region was related to the count rate in the liver (2) or in the bowel (3). Thomas et al. proposed a subjective index of reflux and reported the possibility of demonstrating duodenogastroesophageal reflux (4).

Objective quantitation of the reflux is difficult for two reasons: (a) the proposed methods (2,3) take into account the intensity of the reflux, influenced by body tissue attenuation especially in obese patients, not its persistence and (b) the count rate and its variation with time in the gastric region can be overestimated if a portion of liver lies in this area due to respiratory movement.

Furthermore, esophageal reflux can be easily documented only after gastrectomy or esophagogastric resection. We propose a scintigraphic method for evaluation of duodenogastroesophageal reflux based on the duration of refluxed activity.

MATERIALS AND METHODS

Twenty-five patients (14 males, 11 females; age range 21-70 yr) complaining of dyspeptic symptoms underwent hepatobiliary scintigraphy. All patients had previously undergone upper gastrointestinal endoscopy. Liver ultrasonography was routinely performed to exclude the presence of cholelithiasis.

A commonly used cholecystokinetic composed of dried egg yolk (4 g) and sorbitol (10 g) was administered per os to the patient (patients were required to fast overnight) 20 min before i.v. injection of 200 MBq of ^{99m}Tc -HIDA. The patient was positioned supine under the camera equipped with a low-energy general-purpose collimator. A series of 60 one-minute images were acquired in a 64×64 byte mode matrix. After this acquisition, the camera was moved so that the liver and gastric regions appeared in the bottom of the camera's field of view. The patient was asked to drink, in a single swallow, 10 ml of water containing 20 MBq of ^{99m}Tc -DPTA while a new acquisition of 120 images, 0.5-sec each, was started. Finally, after further ingestion of 200 ml of normal water to obtain the exact gastric localization, a series of 1-sec image was acquired for 2 min while the patient performed several Valsalva maneuvers to induce gastroesophageal reflux.

The persistent radioactivity in the gastric region rather than the intensity of the radioactivity refluxed was taken into account for grading reflux. Four patterns of reflux were identified: Grade 0 (Fig. 1) was the absence of reflux, minimal reflux lasting 1 min, or reflux observed in the first 10-15 min after injection; Grade 1 (Fig. 2) was repetitive reflux of variable duration, generally less than 10 min; Grade 2 (Fig. 3) was persistent reflux of moderate intensity; and Grade 3 (Fig. 4) was reflux up to the esophagus.

Scintigraphic results were compared to the results from 24-

Received Jan. 17, 1990; revision accepted Sept. 12, 1990.
For reprints contact: Dr. Nicoletta Borsato, Medicina Nucleare, Ospedale Civile, Castelfranco Veneto (Treviso) Italy.

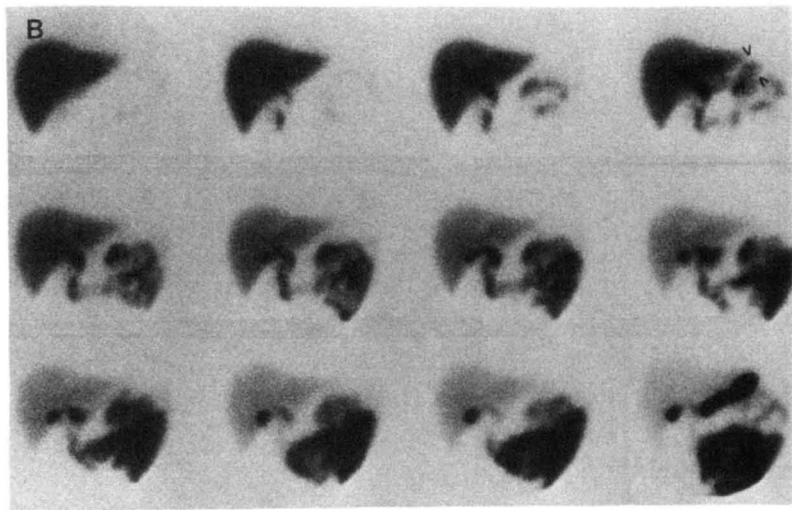
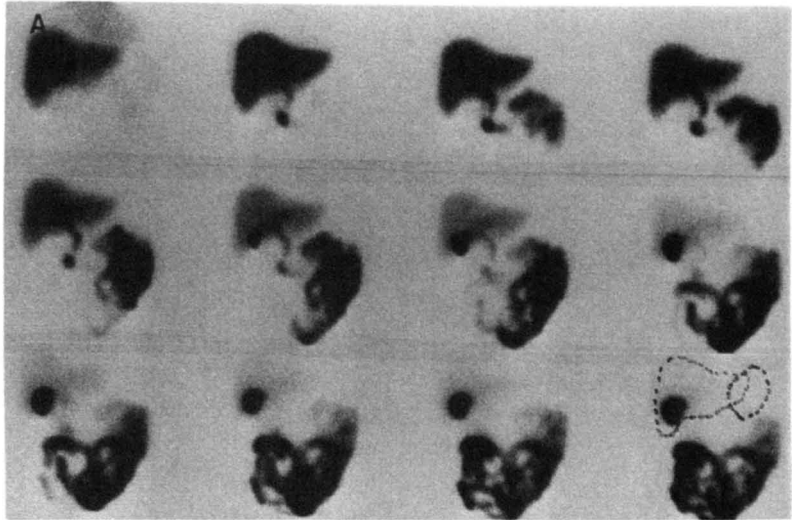


FIGURE 1

(A) A normal study in which no reflux is seen in the gastric region outlined in the last picture. (B) One episode of moderate reflux (arrow head); in the last, image gastric localization is shown.

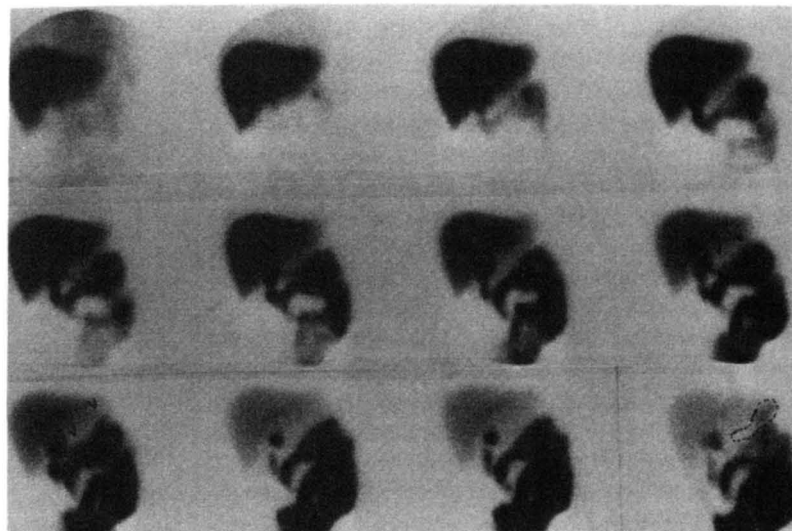


FIGURE 2

Grade 1 reflux. Repetitive episodes of moderate reflux (arrow head) are seen in the gastric antrum. In the last image, the gastric area is outlined.

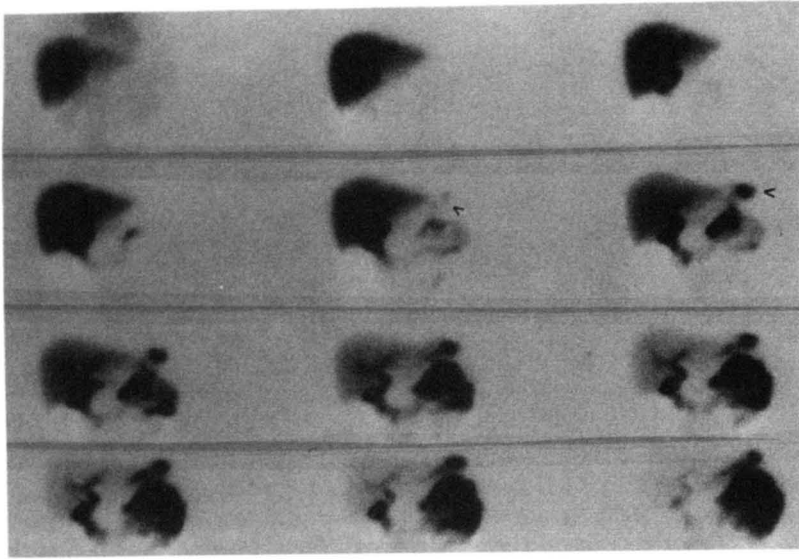


FIGURE 3
Grade 2 reflux. A persistent activity is seen in a rounded area corresponding to the gastric body.

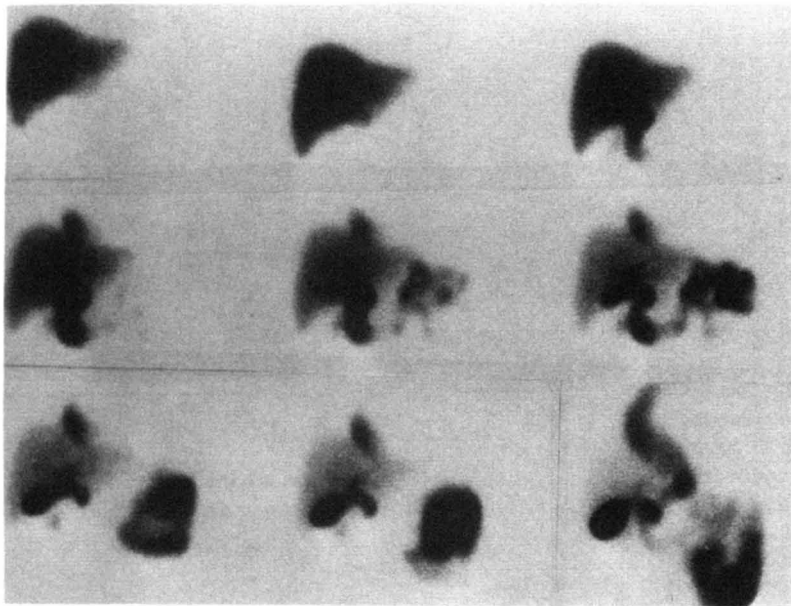


FIGURE 4
Grade 3 reflux. The refluxate arrives up to the esophagus in this patient who was surgically treated for esophageal carcinoma.

TABLE 1
Comparison of Scintigraphy and 24-Hour pH Monitoring Results

	24-hr pH monitoring	
	+	-
Scintigraphy	+ 6 (5)	7 (4)
	- 3 (3)	9 (7)

Numbers in parentheses are the number of patients with evidence of gastritis.

hr gastric pH monitoring (5). This was performed in all patients using a pH glass probe placed 5-10 cm proximal to the pylorus and connected to a portable pH meter system. Duodenogastric reflux was defined as the variation of gastric pH above 4, excluding post-prandial alkalinization. Based on data from a group of eight asymptomatic volunteer subjects, patients with greater than 10% of alkaline exposure during the monitored period were considered refluxers.

RESULTS

In 15 of the 25 patients examined (60%), scintigraphy and 24-hr pH monitoring were in agreement (Table 1).

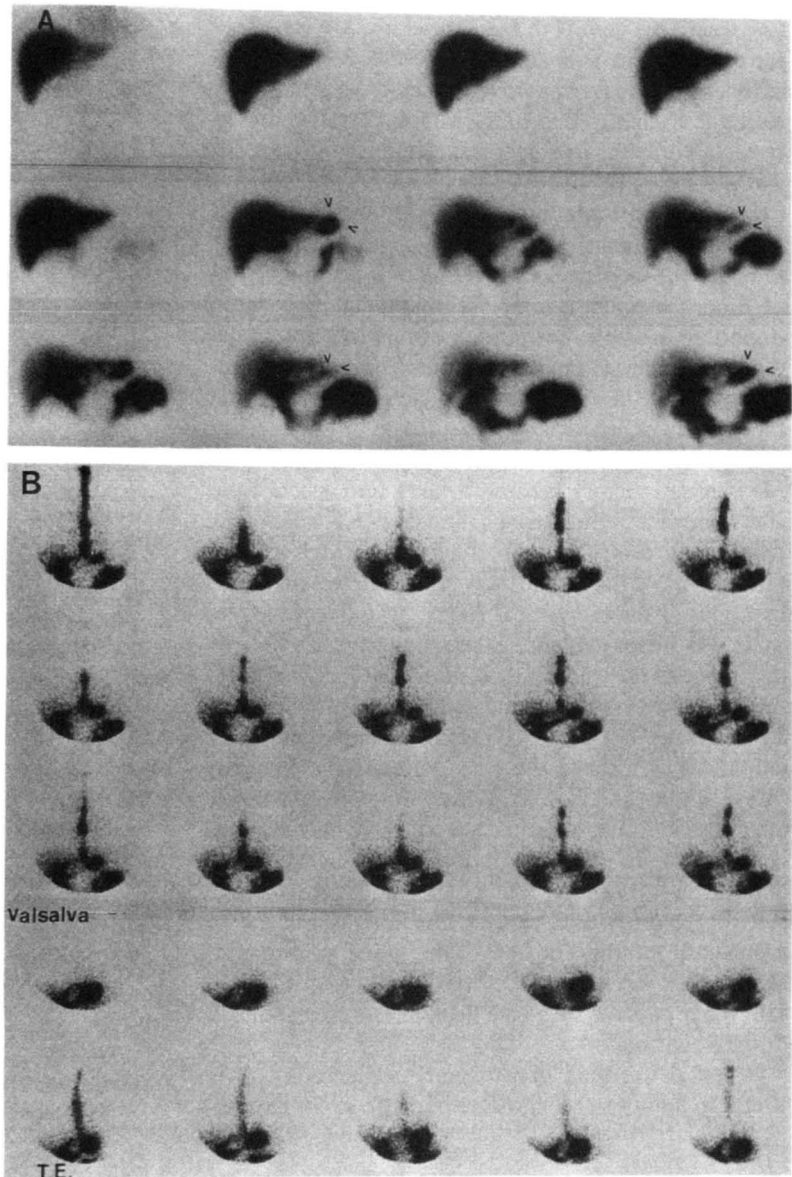


FIGURE 5
Grade 3 reflux indirectly visualized. (A) Grade 2 reflux into the stomach is persistently evident. (B) Subsequent normal esophageal transit study of a liquid bolus in which gastroesophageal reflux was obtained during the Valsalva maneuver.

Nine of the 13 patients with a positive scintigraphic study and 10 of the 12 with a negative study had evidence of gastritis ($p = ns$). In addition, no correlation was found between the scintigraphic grading and the total time of alkaline exposure measured by 24-hr pH monitoring.

Reflux up to the esophagus was directly demonstrated only in five patients with previous esophagogastrotomy. In the remaining cases, hepatobiliary scintigraphy demonstrated duodenogastric reflux, while reflux into the esophagus only occurred in the images obtained after filling of the stomach with radioactive water and Valsalva maneuvers (Fig. 5).

DISCUSSION

Hepatobiliary scintigraphy using ^{99m}Tc -HIDA derivatives can demonstrate duodenogastric reflux, although

no correlation has been found between the intensity of the reflux and damage to the gastric mucosa. The lack of correlation with the endoscopic findings has already been addressed in the literature, but it still remains an unresolved issue (6). Despite the scepticism of some authors, who do not consider alkaline reflux gastritis to be a distinct disease (7), compelling evidence for the existence of the syndrome comes from the fact that surgical diversion of biliopancreatic secretions alleviate symptoms in patients with post-gastrectomy disorders (8). On the other hand, objective tests are necessary for a precise diagnostic assessment, since antral gastritis also has been frequently found in patients with *Helicobacter pylori* infection (9).

The quantitation of duodenogastric reflux using hepatobiliary scintigraphy is subject to errors from various sources. The quantitative method proposed by Tolin

(2), where the counts in the gastric area are related to the counts in the liver at a definite time, or the method of Niemela (3) in which radioactivity in the gastric region is related to that in the bowel, have two limitations: (a) difficulty in exactly delineating the gastric area while avoiding the liver and/or bowel, because respiratory movements continuously modify the relative position of the organs; and (b) these quantitative methods measure the intensity of the reflux in a definite period of time, generally 1 min. We think that it is more important to assess the duration of contact between the duodenal contents and the gastric and/or the esophageal mucosa, since this is a recognized factor in determining the severity of mucosal damage (10).

Even the scoring system proposed by Thomas et al. (4) is unsatisfactory because it takes into account the site where the reflux arrives (i.e., Grade 1 when duodenogastric reflux is limited to the gastric antrum; Grade 2 or 3 if the gastric body is more or less involved; or Grade 4 for esophageal reflux. In our experience, there was direct evidence of esophageal reflux only in the five patients who underwent esophagogastrectomy. In the evaluation of patients with intact stomachs, we advocate the use of ^{99m}Tc -DTPA in water (normally employed to localize the gastric area) for esophageal transit studies and to determine gastroesophageal reflux after gastric filling with normal water. In this fashion, it is possible to obtain an indirect assessment of duodenogastroesophageal reflux and a comprehensive study of pyloric and cardial function as well as of esophageal motility. In four of our cases, gastroesophageal reflux was associated with duodenogastric reflux; four other patients showed a delayed esophageal transit of the liquid bolus.

When performing hepatobiliary scintigraphy, it is useful to administer a cholecystokinetic 15-20 min be-

fore the injection of the ^{99m}Tc -HIDA derivatives to reduce radioactivity storage in the gallbladder and to ensure better visualization of reflux. This can reduce the time needed for data acquisition.

In conclusion, this modified hepatobiliary scintigraphy technique can provide information about alkaline reflux and related motility disorders of the upper digestive tract that correlate with pH probe measurements. In fact, the proposed technique takes a little longer than the traditional method, but intubation is not required.

REFERENCES

1. Nath BJ, Warshaw AL. Alkaline reflux gastritis and esophagitis. *Ann Rev Med* 1984;35:383-396.
2. Tolin RD, Malmud LS, Stelzer F, et al. Enterogastric reflux in normal subjects and in patients with Billroth II gastroenterostomy. *Gastroenterology* 1979;77:1027-1033.
3. Niemela S, Heikkila J, Lehtola J. Duodenogastric bile reflux as measured by an isotope technique and its correlation with endoscopic findings. *Ann Clin Res* 1983;15:146-150.
4. Thomas WEG, Jackson PC, Cooper MJ, Davies ER. The problem associated with scintigraphic assessment of duodenogastric reflux. *Scand J Gastroenterol* 1984;19(suppl. 92):36-40.
5. Little AG, DeMeester TR, Skinner DB. Combined gastric and esophageal 24-hour pH monitoring in patients with gastroesophageal reflux. *Surg Forum* 1979;30:351-352.
6. Ritchie WP. Alkaline reflux gastritis: a critical reappraisal. *Gut* 1984;25:975-987.
7. Meyer JH. Reflections on reflux gastritis. *Gastroenterology* 1979;77:1143-1145.
8. Malagelada JR, Phillips SF, Shorter RG, et al. Postoperative reflux gastritis: pathophysiology and long-term outcome after Roux-en-Y diversion. *Ann Intern Med* 1985;103:178-183.
9. Coelho LG, Das SS, Payne A, Karim QN, Baron JH, Walker MM. *Campylobacter pylori* in esophagus, antrum, and duodenum. A histological and microbiological study. *Dig Dis Sci* 1989;34:445-448.
10. Dodds WJ, Hogan WJ, Helm JF, Den J. Pathogenesis of reflux esophagitis. *Gastroenterology* 1981;81:376-389.