Fast Diagnosis of Abdominal Infections and Inflammations with Technetium-99m-HMPAO Labeled Leukocytes

Eila H. Lantto, Tuomo J. Lantto and Martti Vorne

Departments of Radiology and Nuclear Medicine, Paijat-Hame Central Hospital, Lahti, Finland

The diagnostic value of early ^{99m}Tc-HMPAO-leukocyte images (2 min, 0.5 hr, 2 hr and 4 hr) was studied in 87 prospectively performed investigations in 80 patients with a suspicion of abdominal inflammation or infection. Sensitivity, specificity and accuracy were 74%, 85% and 77% in the 2-min scans, 88%, 81% and 86% in the 0.5-hr scans, 95%, 85% and 92% in the 2-hr scans, and 96%, 92% and 95% in the 4-hr scans. Nonspecific bowel accumulation was seen in 7% of patients at 2 hr and in 28% at 4 hr but was easily distinguishable from pathologic activity. The uptake in early images represents an active accumulation of granulocytes at the site of inflammation rather than nonspecific blood-pool activity judged by results of ^{99m}Tc-HMPAO-RBC imaging. We found that imaging within 2 hr from injection has a high diagnostic value, and that the activity accumulates in areas of infection and inflammation faster than in the intestinal background.

J Nucl Med 1991: 32:2029–2034

An accurate diagnostic method which gives results without significant delay is important in diagnosing abdominal infections and inflammation (*1*). Ultrasonography (US) and computed tomography (CT) are rapid imaging modalities but they are nonspecific and insensitive in many abdominal inflammations such as appendicitis and inflammatory bowel disease. The disadvantage of scintigraphy with ^{67}Ga-citrate or ^{111}In-labeled leukocytes is the diagnostic delay of 24 hr. There are several reports of ^{99m}Tc-hexamethylpropyleneamine oxime (HMPAO) leukocytes detecting infections and inflammations within 4 hr and even as early as 30 min after injection (*2–5*). The nonspecific bowel accumulation has, however, caused controversial opinions of the suitability of this method for abdominal imaging (*6–7*).

Therefore, we undertook a prospective study to evaluate the diagnostic accuracy of early images (2 min–4 hr) with ^{99m}Tc-HMPAO leukocytes in abdominal infections and inflammations by an assessment of tracer uptake in diseased areas and the nonspecific bowel and gallbladder uptake.

Received Feb. 25, 1991; revision accepted Jun. 4, 1991

For reprints contact: Eila Lantto, MD, Department of Radiology, Paijat-Hame Central Hospital, Keskussairaalankatu 7, SF-15850 Lahti, Finland.

PATIENTS AND METHODS

Patients

Eighty consecutive patients (45 male, 35 female; age range 9–84, mean 52 yr) with suspicion of abdominal infection or inflammation were prospectively studied with ^{99m}Tc-HMPAO leukocytes. Because some of the patients had multiple studies, a total of 87 scintigraphic procedures were performed.

The diagnoses were confirmed pathologically (surgery, biopsy, or drainage of pus) in 42 cases, and clinically (including US, CT, x-ray, and laboratory studies) in 45 cases. The final diagnoses are presented in Table 1.

Labeling Technique

Mixed leukocytes were isolated and labeled as described previously (*4*). Forty milliliters of venous blood were drawn into a 60-ml plastic syringe containing 10 ml of acid citrate dextrose and 10 ml of 6% hydroxyethyl starch. After sedimentation for 1 hr at room temperature, the supernatant was centrifuged in sterile tubes at 100 g for 5 min. The platelet-rich supernatant was isolated and centrifuged at 2,000 g for 5 min to obtain cell-free plasma. Leukocytes were suspended into 1 ml of cell-free plasma. Technetium-99m-HMPAO was formed by adding 600 MBq ^{99m}Tc in 6 ml isotonic saline to a vial containing HMPAO (Ceretec, Amersham International). Five millilters (500 MBq) of ^{99m}Tc-HMPAO complex were added to the leukocyte suspension, which was left for 10 min at room temperature. The suspension was centrifuged at 100 G for 5 min, the supernatant was discarded and the cells were resuspended in 5 ml of cell-free plasma, and reinjected intravenously.

The average cell labeling efficiency was 41% (range 7%–86%). The mean dose injected was 200 MBq (range 28–370 MBq). The viability of granulocytes was investigated by the trypan blue exclusion test. Equal volumes of cell suspension and trypan blue dye (1% w/v) were mixed and examined microscopically for dye uptake after 10 min.

Imaging

Scintigrams were obtained at 2 min, 0.5 hr, 2 hr, and 4 hr after the injection of labeled leukocytes with a large field of view gamma camera in anterior abdominal projection. Posterior abdominal, right or left anterior oblique and pelvic outlet views

TABLE 1
Final Diagnoses of the Patients

Final diagnoses	No. of examinations
Bowel inflammation and abscesses	
Ulcerative colitis or Crohn's disease	23
Acute diverticulitis	18
Abscess	12
Appendicitis	1
Colocutaneous fistula	1
Other	
Abdominal pain of unknown origin	13
Fever of unknown origin	5
Sepsis	2
Salpingo-oophoritis	2
Colon carcinoma	1
Non-infected pancreatic pseudo-cyst	1
Acute cholecystitis	1
Cholelithiasis	1
Acute pyelonephritis	1
Acute cystitis	1
Hepatitis	1
Rheumatic polymyalgia	1
Cellulitis	1
Irritable bowel	1
Total	87

were often used to localize the tracer uptake. It was not always possible to record images at 4 hr during normal working hours because the patient examination began too late.

All images were examined by two experienced nuclear medicine physicians who were blinded to each other and the clinical history and diagnosis. They graded the pathologic tracer uptake as weak, moderate or strong by subjective assessment and evaluated the nonspecific gallbladder and bowel accumulation on each image. Most readings were in agreement and the readings with some discrepancy were re-evaluated together and a decision was reached by consensus.

Serum C-reactive protein (CRP), peripheral blood leukocyte count, erythrocyte sedimentation rate, and duration of symptoms and antibiotic therapy at the time of scintigram were noted.

Imaging with Labeled Red Blood Cells

Five patients with a positive scintigraphic finding at 2 min also were examined with ^{99m}Tc-HMPAO-labeled red blood cells (RBCs) to find out whether the tracer accumulation at inflammation site represents blood pool activity.

Three milliliters (500 MBq) of ^{99m}Tc-HMPAO complex were added to 6 ml of heparinized whole blood in a 10-ml sterile vacuum tube and incubated for 10 min at room temperature. Four milliliters of the labeled whole blood were carefully layered over 3.5 ml density gradient medium (Polyprep™, Nycomed, Pharmacia Diagnostica, Oslo, Norway) in a closed sterile tube, and centrifuged at 500 g for 30 min. The pellet of red blood cells was separated, washed once with saline (10 min, 800 g), resuspended in 3 ml saline and injected into the patient. The average labeling efficiency was 55% (range 45%–60%).

Scintigraphy with labeled RBCs was performed within 1–3 days from the leukocyte scan. The possible tracer activity due to the previous leukocyte scan was registered before the injection of labeled RBCs. Images were obtained in anterior abdominal projection during flow and at 2 min, 0.5 hr and 2 hr.

TABLE 2
Results of ^{99m}Tc-HMPAO Leukocyte Scans at Various Imaging Times

	2 min	0.5 hr	2 hr	4 hr
Number of patients	87	85	86	80
True-positive	45	52	57	53
True-negative	22	21	22	23
False-positive	4	5	4	2
False-negative	16	7	3	2

The Pearson correlation coefficient and Mann-Whitney U-test were used for statistical analysis.

RESULTS

Cell viability was 100%. The results of scintigrams at various imaging times are presented in Tables 2 and 3.

The abnormal leukocyte accumulation generally increased as a function of time (Fig. 1). However, images obtained at 4 hr did not give additional information compared with 2 hr images in any patient, with the exception of one patient with false-positive images at 2 min to 2 hr and true-negative images at 4 hr. Abscesses and acute diverticulitis showed a focal leukocyte uptake which did not move in serial images. In inflammatory bowel disease, the intraluminal activity usually shifted in sequential images.

At 2 min, 16 images (18%) showed false-negative results. These were recorded from three patients with abscesses situated near bone marrow at anterior images, two with abscesses in the pouch of Douglas (one of them a healing abscess in a control examination), five with inflammatory bowel disease, two cases of acute diverticulitis, two cases of salpingo-oophoritis, one of cystitis and one of acute cholecystitis. Seven patients (8%) had false-negative images at 0.5 hr as well. Three patients had false-negative results at all imaging times. One of them, who was imaged only between 2 min and 2 hr, had acute cholecystitis which was verified surgically and histologically. One had ulcerative colitis with moderate chronic inflammation in the rectosigmoid area and one had nonspecific colitis with moderate inflammation in the rectum; in both cases the diagnosis was verified endoscopically and by histologic assessment of mucosal biopsy specimens.

Three of the five patients with false-positive images were examined because of a suspicion of postoperative abscess.

TABLE 3
Results of ^{99m}Tc-HMPAO Leukocyte Scans at Various Imaging Times

	2 min	0.5 hr	2 hr	4 hr
Sensitivity (%)	74	88	95	96
Specificity (%)	85	81	85	92
Accuracy (%)	77	86	92	95
Positive predictive value (%)	92	91	93	96
Negative predictive value (%)	58	75	88	92

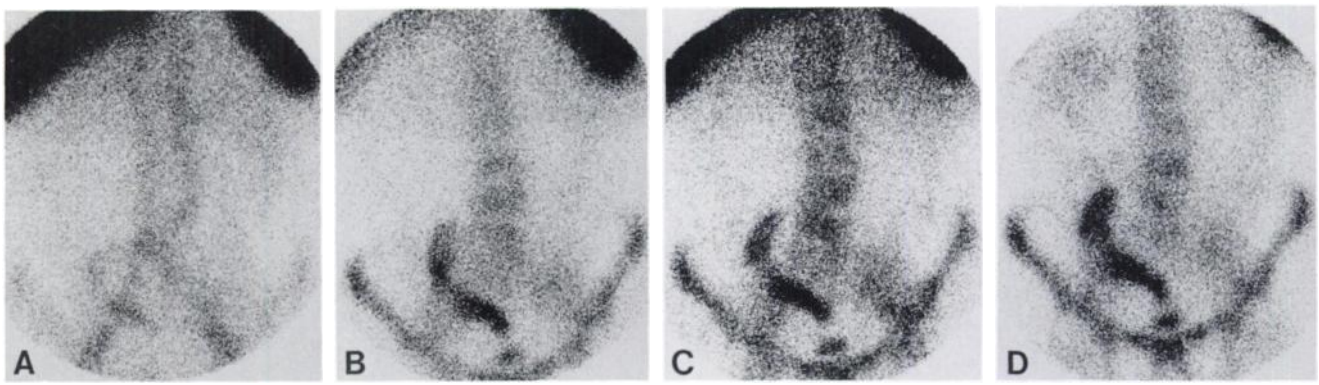

FIGURE 1. A patient with ulcerative colitis imaged with ^{99m}Tc-HMPAO leukocytes at 2 min (A), 0.5 hr (B), 2 hr (C) and 4 hr (D). The inflamed segment of bowel is clearly positive at 2 min (A), and the activity increases with time (B–D).

In two cases, there was an increasing tracer accumulation but an abscess was not found by US or CT. In one case, a weak accumulation was seen at 2 min and at 0.5 hr, which was correctly interpreted as an inflammatory reaction in a recent wound. One patient with abdominal pain and high CRP value had a weakening tracer accumulation in the right lower abdomen in serial images between 2 min and 2 hr, but the finding at 4 hr was negative. No explanation for the symptoms or scintigraphic finding was found by US, CT or barium enema. The symptoms subsided within two weeks without antibiotic treatment. In all of these patients, the scintigrams were considered false-positives because verification of an infection or inflammation was not obtained by other imaging methods. The fifth false-positive result was in a patient who had colonic adenocarcinoma which was surgically removed after scintigraphy.

Interobserver agreement was 86% for 2-min scans, 92% for 0.5-hr scans, 94% for 2-hr scans, and 95% for 4-hr scans. There was disagreement about the presence of weak uptake in the proximal colon at 0.5–4 hr in a patient with irritable bowel syndrome. In one patient with cystitis, one observer considered the scintigram negative, but the other positive because there was a rim-like uptake in the wall of the urinary bladder at 0.5 and 2 hr. The 4-hr scintigram was negative because images were recorded after voiding. In one patient, one observer considered the finding negative with nonspecific bowel activity in later images, but the other found it suggestive for acute diverticulitis. The consensus was negative. The other cases of initial disagreement were whether there was a weak uptake or not, mainly in 2-min scans.

There was no significant difference in CRP, leukocyte count, ESR or duration of symptoms and antibiotic therapy between patients with true-positive and false-negative scintigrams, between patients with true-negative and false-positive scintigrams, or between patients with true-positive and true-negative scintigrams. There was no correlation between the imaging time at which the scintigrams became positive and the laboratory tests or duration of symptoms or antibiotic therapy before scintigraphy.

Nonspecific bowel accumulation was never present before 2 hr. Six patients (7%) had faint accumulation in the ascending colon at 2 hr and 22 patients (28%) at 4 hr, respectively. Nonspecific gallbladder accumulation was seen in five cases (6%) both at 2 hr and 4 hr.

Five patients with a positive leukocyte scan finding at 2 min were imaged with labeled RBCs. Two of them (one with periappendicular abscess and one with Crohn's disease) had focal uptake in the RBC scintigram, but the accumulation was weaker than with labeled leukocytes (Fig. 2). The other three patients (two with ulcerative colitis and one with acute diverticulitis) had negative RBC scan findings (Fig. 3).

DISCUSSION

Fast imaging methods with high sensitivity and specificity are needed in many clinical situations (*1*). The main disadvantage of ^{67}Ga-citrate and ^{111}In-labeled agents has been the diagnostic delay of at least 24 hr. There have been many attempts to utilize the favorable imaging properties of ^{99m}Tc to detect inflammatory lesions with different forms of ^{99m}Tc-labeled agents [i.e., colloids, polyclonal human immunoglobulin and monoclonal antibodies (*8–12*)]. Since 1986, ^{99m}Tc-HMPAO labeled leukocytes have been successfully used for imaging a wide variety of inflammatory diseases (*2–5, 13–16*)). There have been reports indicating that abdominal infections can be detected as early as 0.5 hr following injection of ^{99m}Tc-HMPAO leukocytes (*2–5*).

In our study, most images were positive earlier than previously described. Sensitivity, specificity and accuracy of 74%, 85% and 77%, respectively, were achieved at 2 min. The accuracy at 0.5, 2 and 4 hr was 85%, 92% and 95%, respectively. The 4-hr images did not give any useful additional information compared with 2-hr images. The higher accuracy of 4-hr images was due to a number of false-negative and false-positive examinations which were not imaged at 4 hr. Some false-negative images at 2 min or at 0.5 hr were in patients with inflammatory bowel disease in inactive or mild stages. Abscesses situated in

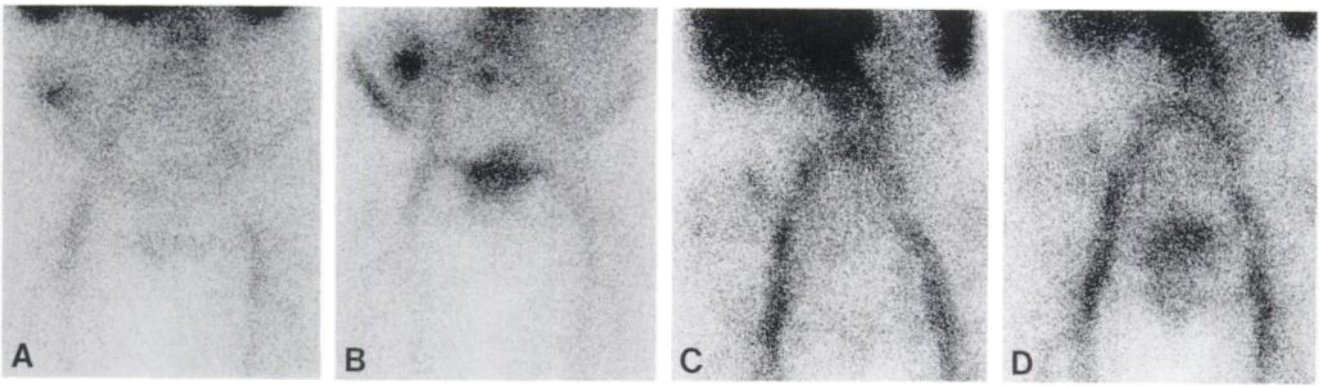

FIGURE 2. Focal accumulation of ^{99m}Tc-HMPAO leukocytes in a periappendicular abscess at 2 min (A) and 0.5 hr (B). Much fainter activity is seen with labeled red blood cells at 2 min (C) and 0.5 hr (D).

anterior projection over bone marrow were not seen at 2 min because of high normal bone marrow activity. They would probably be seen in oblique views. The sensitivity, specificity and accuracy of the present study agree with the previous results of Roddie et al, Vorne et al., Li et al., and Reynolds et al. (*3–4, 15–16*).

We found no difference in the duration of symptoms or antibiotic therapy between patients with true-positive or false-negative scintigrams. Our results do not support the suspicion that early images would have lower sensitivity to detect chronic abscesses (*7*). For example, one patient in our series was imaged three times and the scintigram was positive at 2 min every time, although symptoms and antibiotic therapy had lasted for over 2 mo.

Nonspecific bowel accumulation appearing mainly after 4 hr following reinjection has been mentioned as a potential disadvantage of the ^{99m}Tc-HMPAO leukocyte scan (*6–7*). In our study, the nonspecific activity, seen mainly in the ascending colon, appeared at 2 hr in 7%, and in 26% of patients at 4 hr. It was faint and did not interfere with the correct interpretation of images (Fig. 4). Mountford et al. in their comparison of ^{111}In-oxine leukocytes and ^{99m}Tc-HMPAO leukocytes yielded a relatively low specificity of 62% with ^{99m}Tc-HMPAO leukocytes due to the nonspecific activity in the bowel (*7*). However, in their study images were recorded at 4 and 24 hr, which was not ideal for ^{99m}Tc-HMPAO leukocytes. The nonspecific activity is probably due to excretion of ^{99m}Tc-complexes other than free pertechnetate or HMPAO-complex because thyroid, gastric or brain uptake is not seen (*17–18*). Thus potassium perchlorate administration before the study is not necessary. Nonspecific bowel accumulation is also fairly commonly seen in ^{111}In labeled leukocyte scans (*19–20*) and always in ^{67}Ga scintigrams (*4,21*).

Becker et al. found nonspecific gallbladder activity in half of their 12 patients (*17*). In our study, nonspecific gallbladder uptake was seen only in 6% of patients at 2 and 4 hr, which is in agreement with a previous report of Roddie et al. (*3*). The nonspecific accumulation is faint and seen in the gallbladder lumen. In acute cholecystitis the uptake is rim-like and easily distinguishable from the nonspecific activity (*5*).

Accumulation of labeled granulocytes in malignant tumors has been reported with ^{111}In and ^{99m}Tc-HMPAO scintigraphy (*5,22–23*). The mechanism of uptake by the tumor is not completely understood. The activity in the patient of the present study can probably be explained by the chronic secondary inflammation seen in the histological examination.

In spite of the rapid imaging results after reinjection,

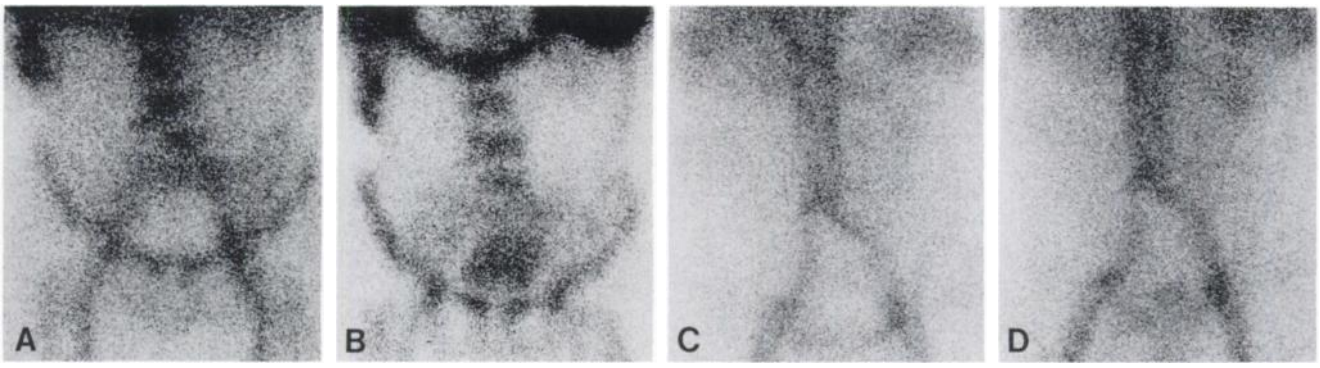

FIGURE 3. Abnormal activity is seen in the ascending, transverse and descending colon in a patient with ulcerative colitis imaged with labeled leukocytes at 2 min (A) and 0.5 hr (B). Images with labeled red blood cells show no activity in the inflamed bowel at 2 min (C) or 0.5 hr (D).

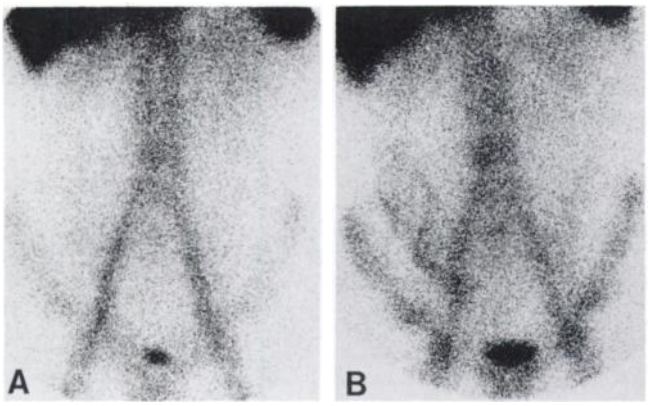

FIGURE 4. Anterior abdominal images of a patient with irritable bowel at 0.5 hr (A) and 4 hr (B). There is no abnormal uptake at 0.5 hr, but faint activity in the ascending colon and terminal ileum is seen at 4 hr.

the method still has the disadvantage of a time-consuming labeling procedure. However, because the diagnosis can be made accurately within a couple of hours from venipuncture, this method can also be used for rapid assessment of acutely ill patients, unlike ^{111}In scintigraphy. Convenience, image quality, radiation dosimetry and more selective labeling of granulocytes are also advantages over ^{111}In (*2–4,13,17*). Acquisition time is only a few minutes, which allows serial imaging and larger patient throughput.

The mechanism of tracer accumulation at inflammatory sites in the early images is unclear. Much of the early information about leukocyte kinetics has been obtained by studying neutrophils labeled with diisopropylfluorophosphate (DFP-32), which, however, cannot be imaged externally (*24*). Following this work, leukokinetics have been studied with ^{111}In (*25*). Some authors have reported activity at inflammatory sites after 30 min following injection of ^{111}In-leukocytes (*26–27*). This activity was regarded as blood-pool activity due to increased vascularity and hyperemia in an infected site (*28–29*). To investigate the mechanism of tracer accumulation in early images, we labeled RBCs with ^{99m}Tc-HMPAO by a method which we have successfully used in imaging gastrointestinal bleeding. In two patients, weak activity was seen at the inflammatory site with labeled RBCs at 2 min, 0.5 hr and 2 hr. However, this uptake was much fainter than in the leukocyte scan (Fig. 2). In the other three patients with the inflammatory site clearly positive with leukocytes at 2 min, no abnormal activity was seen in the inflamed area with labeled RBCs. These results suggest that the uptake seen at 2 min and 0.5 hr cannot be only nonspecific blood pool activity but is mainly due to an active accumulation of granulocytes at the inflammatory site. However, this hypothesis must be further evaluated with a larger series of patients. An interesting theory about the mechanism of early uptake is presented with the use of ^{99m}Tc-albumin colloid leukocytes (TAC-WBC) (*8–9*). The agent responsible for early activity at inflammatory site is thought to be free TAC, which goes through the vessels and labels the leukocytes at the abscess. TAC-WBC preparation has been reported to contain 20%–30% of free TAC (*8*). In ^{99m}Tc-HMPAO leukocytes about 98% of unbound label can be removed by the final centrifugation (*14*). The early positive findings with ^{99m}Tc-HMPAO leukocytes probably cannot be explained by the accumulation of free [^{99m}Tc]pertechnetate or ^{99m}Tc-HMPAO at the inflammatory sites.

In conclusion, most abdominal infections are seen at 2 min with ^{99m}Tc-HMPAO leukocytes, but images taken at 0.5 and/or 2 hr are recommended to confirm the increasing uptake. Imaging at 4 hr is not needed, and the frequency of nonspecific bowel tracer accumulation at this point is higher than in earlier images. The mechanism of granulocyte accumulation at the inflammation in early images appears to be active migration rather than nonspecific blood-pool activity, but further clarification is needed.

REFERENCES

1. Rubin RH. In search of the hot appendix: a clinician's view of inflammation imaging [Editorial]. *J Nucl Med* 1990;31:316–317.
2. Peters AM, Osman S, Henderson BL, et al. Clinical experience with ^{99m}Tc-hexamethylpropyleneamine oxime for labeling leucocytes and imaging inflammation. *Lancet* 1986;ii:946–949.
3. Roddie ME, Peters AM, Danpure HJ, et al. Inflammation: imaging with Tc-99m-HMPAO labeled leukocytes. *Radiology* 1988;166:767–772.
4. Vorne M, Soini I, Lantto T, et al. Technetium-99m HM-PAO-labeled leukocytes in detection of inflammatory lesions: comparison with gallium-67-citrate. *J Nucl Med* 1989;30:1332–1336.
5. Laitinen R, Tähtinen J, Lantto T, et al. Tc-99m labeled leukocytes in imaging of patients with suspected acute abdominal inflammation. *Clin Nucl Med* 1990;15:597–602.
6. Hotze A, Kropp J, Kozak B, et al. ^{99m}Tc-HMPAO leukocyte imaging: First clinical results and possible problems in inflammatory abdominal diseases. *Nucl Med* 1988;27:115–116.
7. Mountford PJ, Kettle AG, O'Doherty MJ, et al. Comparison of technetium-99m-HM-PAO leukocytes with indium-111-oxine leukocytes for localizing intraabdominal sepsis. *J Nucl Med* 1990;31:311–315.
8. Marcus CS, Henneman PL, Butler JA, et al. Characteristics of the Tc-99m albumin colloid leucocyte preparation. *J Nucl Med* 1987;28:574.
9. Marcus CS, Kuperus JH, Butler JA, et al. Phagocytic labeling of leukocytes with ^{99m}Tc-albumin colloid for nuclear medicine. *Nucl Med Biol* 1988;15:673–682.
10. Mock BH, English D. Leukocyte labeling with technetium-99m tin colloids. *J Nucl Med* 1987;28:1471–1477.
11. Lind P, Langsteger W, Költringer P, et al. Immunoscintigraphy of inflammatory processes with a technetium-99m-labeled monoclonal antigranulocyte antibody (Mab BW 250/183). *J Nucl Med* 1990;31:417–423.
12. Buscombe JR, Lui D, Ensing G, et al. ^{99m}Tc-human immunoglobulin (HIG)-first results of a new agent for the localization of infection and inflammation. *Eur J Nucl Med* 1990;16:649–655.
13. Peters AM, Roddie ME, Danpure HJ, et al. ^{99m}Tc-HMPAO labelled leucocytes: comparison with ^{111}In-tropolonate labelled granulocyes. *Nucl Med Commun* 1988;9:449–463.
14. Schölmerich J, Schmidt E, Scumichen C, et al. Scintigraphic assessment of bowel involvement and disease activity in Crohn's disease using technetium Tc-99m-hexamethyl propylene amine oxine as leukocyte label. *Gastroenterology* 1988;95:1287–1293.
15. Li DJ, Middleton SJ, Wright EP. ^{99m}Tc-HMPAO-labelled leukocyte scintigraphy in inflammatory bowel disease. *Nucl Med Commun* 1990;12:889.
16. Reynolds JH, Graham D, Smith FW. Imaging inflammation with ^{99m}Tc-HMPAO-labelled leucocytes. *Clin Radiol* 1990;42:195–198.
17. Becker W, Schoman E, Fischbach W, et al. Comparison of ^{99m}Tc-HMPAO and ^{111}In-oxine-labelled granulocytes in man: first clinical results. *Nucl Med Commun* 1988;9:435–447.
18. Paakkinen S, Vorne M, Lantto T, et al. Detection of inflammation with ^{99m}Tc-HMPAO labelled leucocytes. *Ann Chir Gynaecol* 1987;76:197–200.
19. Datz FL, Thorne DA. Gastrointestinal tract radionuclide activity on In-111-labeled-leukocyte imaging: clinical significance in patients with fever

of unknown origin. *Radiology* 1986;160:635–639.
20. Syrjälä MT, Liewendahl K, Valtonen V, et al. Intestinal accumulation of ^{111}In-granulocytes in patients studied because of occult infection. *Eur J Nucl Med* 1987;13:121–124.
21. Korobkin M, Callen PW, Filly RA, et al. Comparison of computed tomography, ultrasonography, and gallium-67 scanning in the evaluation of suspected abdominal abscess. *Radiology* 1978;129:89–93.
22. Schmidt KG, Rasmussen JW, Wedebye IM. Accumulation of indium-111-labeled granulocytes in malignant tumors. *J Nucl Med* 1988;29:479–484.
23. Fortner A, Datz FL, Taylor A, et al. Uptake of ^{111}In-labeled leukocytes by tumor. *Am J Roentgenol* 1986;146:621–625.
24. Athens JW, Haab OP, Raab SO, et al. Leukokinetic studies. IV. The total blood, circulating and marginal granulocyte pools and the granulocyte turnover rate in normal subjects. *J Clin Invest* 1961;40:989–995.
25. Weiblen BJ, Forstrom L, McCullough J. Studies of the kinetics of indium-111-labeled granulocytes. *J Lab Clin Med* 1979;94:246–255.
26. Dutcher JP, Schiffer CA, Johston GS. Rapid migration of ^{111}In-labeled granulocytes to sites of infection. *N Engl J Med* 1981;304:586–589.
27. Becker W, Fischbach W, Reiners C, et al. Three-phase white blood cell scan: diagnostic validity in abdominal inflammatory disease. *J Nucl Med* 1986;27:1109–1115.
28. Datz FL, Jacobs J, Baker W, et al. Decreased sensitivity of early imaging with In-111-oxine-labeled leukocytes in detection of occult infection: concise communication. *J Nucl Med* 1984;25:303–306.
29. Doherty PW, Goodwin DA. Migration of ^{111}In-labeled granulocytes to infection sites. *N Engl J Med* 1981;304:1546–1547.

EDITORIAL

Imaging of Inflammatory Sites in the 1990s: New Horizons

The anatomic localization of focal collections of inflammatory cells in the setting of acute or subacute infections or inflammatory states presents a major challenge to the clinician. The early and accurate detection of postsurgical infectious complications such as intra-abdominal absess, infection involving deep wounds suffered following major trauma and appendicitis would allow earlier therapy with antibiotics and surgical debridement. The availability of a rapid imaging technique for inflammatory cells would also aid in the diagnosis of skeletal infections, such as osteomyelitis, and in the evaluation of immunosuppressed patients who present with fever and subtle, but nonlocalizing signs of infection. Such a technique would also be very useful for diagnosing and assessing the response to therapy of inflammatory diseases such as ulcerative colitis, Crohn's disease, rheumatoid arthritis, systemic lupus erythematosus, the systemic vasculitidies and sacoidosis. Despite the fact that methods for imaging inflammatory and infectious lesions were developed as early as 1971 with ^{67}Ga scanning (*1*) and 1976 with the use of ^{111}In-labeled leukocytes (*2,3*), there as yet exists no widely available diagnostic test to clinicians for this purpose. This is particularly true in the detection of intra-abdominal sources of inflammation and infection.

The techniques currently in limited use for detecting inflammatory sites are:

1. Gallium-67 scanning.
2. Indium-111-labeled leukocytes.
3. Leukocytes labeled with ^{99m}Tc via phagocytic ingestion of colloid in the form of reducing agents such as stannous pyrophosphate, or via passive uptake by ^{99m}Tc-labeled lipophilic complexes.
4. Direct injection of ^{99m}Tc- or ^{111}In-labeled agents which localize at inflammatory sites such as anti-granulocyte antibodies, and polyclonal immunoglobulins.

Gallium-67-citrate was first noted to localize in inflammatory lesions in 1971 (*2,3*) and since that time has been useful in certain instances for the detection of infectious foci (*4*). The major problems with ^{67}Ga scanning are that at least 24 hr are required between injection and imaging, and that early bowel uptake precludes its use for evaluation of abdominal infections (*5–6*). Indium-111-labeled leukocyte scanning is recognized as a useful test for detecting inflammation and infection in vascular grafts, chronic pulmonary inflammation and certain abdominal afflictions including inflammatory bowel disease, pseudomembranous colitis, diverticulitis and bowel infarction (*7–10*). Although ^{111}In-labeled leukocytes do not normally localize in the bowel, false-positive images have been caused by gastrointestinal bleeding, swallowed leukocytes and multiple enemas (*9*). In a study of 312 scans from 271 patients with fever of unknown origin, 32 false-positive results of abdominal uptake were noted at 24 hr following injection due to gastrointestinal bleeding or swallowed leukocytes (*9*). Other disadvantages of ^{111}In-labeling are the expense and inconvenience of using ^{111}In and the radiation dose to the patient.

Various methods have been developed to label leukocytes with ^{99m}Tc instead of ^{111}In to improve image resolution and to decrease expense and radiation dose to the patient. Phagocytic uptake of ^{99m}Tc-labeled colloids or microspheres by neutrophils and monocytes has been used to this end (*11–13*). These methods require less blood from patients since no cell separation is required. Technetium-99m-albumin labeled colloid has been reported to localize appendiceal abscesses within 15 min to several hours depending on the clinical situation (*13*). The early activity (minutes) within the inflammatory site is due to the uptake of unphagocytized ^{99m}Tc-

Received Aug. 12, 1991; accepted Aug. 12, 1991.

For reprints contact: Marilyn C. Pike, Arthritis Unit, Massachusetts General Hospital, Fruit St., Boston, MA 02114.