

---

# Radioimmunodetection of Degranulated Human Eosinophils in Mice: A Potential Model for Imaging Hodgkin's Disease and Other Pathologic Conditions

Michael K. Samoszuk, Mei Fang and Anne-Line J. Anderson

*Pathology and Radiological Sciences Departments, University of California, Irvine, California*

---

Various human tumors such as lymphomas and carcinomas sometimes contain extensive infiltration by degranulating eosinophils. To determine if degranulated eosinophils are suitable targets for immunolocalization, we performed in vivo distribution and imaging studies in mice, using EOS (a murine monoclonal antibody directed to human eosinophil peroxidase) labeled with indium-111. Adult mice were injected intravenously with radiolabeled EOS antibody or with similarly radiolabeled normal mouse IgG before receiving an intramuscular injection into the right thigh of homogenized human eosinophils adsorbed to latex microspheres. There was striking localization in the right thigh of the radiolabeled EOS antibody detectable by gamma imaging techniques as soon as 24 hr after injection. By contrast, there was little accumulation of radiolabeled normal IgG in the right thigh. We conclude that human eosinophil peroxidase is potentially a suitable target for radioimmunodetection and therapy of neoplasms and pathologic conditions that contain degranulating eosinophils.

**J Nucl Med 1991; 32:89-94**

---

**H**uman tumors of various histologic types (lymphomas; adenocarcinomas of the breast and colon; lung carcinomas) sometimes contain massive infiltration by eosinophils (1-6). In tissues involved by Hodgkin's disease, T-cell lymphomas, and certain other pathologic conditions, the eosinophilic infiltrate is also accompanied by extensive degranulation of the eosinophils (7-10). By contrast, eosinophils in normal tissues, such as bone marrow, do not undergo detectable degranulation (11).

A major component of eosinophil granules is eosinophil peroxidase, a highly cationic protein that binds avidly to cell membranes upon degranulation (12). We have developed a murine monoclonal antibody (EOS)

that is directed against human eosinophil peroxidase (13). In pre-clinical in vitro studies, the antibody has been shown to bind specifically to tissues (such as Hodgkin's disease and T-cell lymphomas) that contain degranulating eosinophils (14).

The intrinsically tumor-specific localization of eosinophil degranulation suggested to us the novel approach of using radiolabeled EOS antibody for radioimmunodetection of eosinophil peroxidase in vivo. In this report, we describe preclinical distribution and imaging studies of radiolabeled EOS antibody in mice that had received intramuscular deposits of homogenized or intact human eosinophils. Our results suggest that human eosinophil peroxidase may be a suitable target for radioimmunodetection and radiation therapy of those human tumors and pathologic conditions that contain degranulating eosinophils.

## MATERIALS AND METHODS

### Preparation and Testing of Labeled Antibodies

Protein A-purified EOS antibody was produced by IDEON Corporation (Redwood City, CA) from ascites of mice inoculated intraperitoneally with a subclone of the SF25.5 cell line. The antibody was conjugated with diethylenetriaminepentaacetic acid anhydride (DTPA) (Sigma, St. Louis, MO) and labeled with indium-111- (<sup>111</sup>In) chloride (Amersham, Arlington Heights, IL) in accordance with a previously published protocol (15). For use as a negative control, normal mouse IgG (Sigma) was also conjugated to DTPA and labeled with <sup>111</sup>In, using an identical procedure. The negative control antibody was included in order to evaluate the possibility that radiolabeled mouse immunoglobulin can localize nonspecifically at the sites of focal inflammation (16) produced by injection of homogenized eosinophils. Both conjugates were analyzed by SDS-PAGE before labeling with <sup>111</sup>In.

For these studies, 800 µg of EOS-DTPA conjugate and 600 µg of IgG-DTPA were labeled with 590 µCi (21.8 MBq) and 470 µCi (17.4 MBq) of <sup>111</sup>In, respectively. After a 30-40-min incubation period at room temperature, the labeled antibodies were purified on 15 ml, P6DG gel (Bio-Rad, Richmond, CA) columns eluted with phosphate-buffered saline (PBS). The initial labeling efficiency and final radiochemical purity were

---

Received Mar. 23, 1990; revision accepted Jun. 11, 1990.  
For reprints contact: Michael Samoszuk, MD, Pathology Department, CCM, Building D-440, University of California, Irvine, CA 92717.

determined by ascending thin-layer chromatography (TLC), using silica gel-impregnated glass fiber strips and a mobile phase of 10% (w/v) aqueous ammonium acetate/methanol/0.3 M aqueous sodium citrate (2:2:1, v/v). The labeled and purified antibodies were then diluted to a final concentration of ~100 µg/ml before further use.

To determine the binding activity of the labeled antibodies, a direct binding radioimmunoassay was performed using 10<sup>5</sup> freeze-thawed human eosinophils or intact lymphocytes fixed to wells of polystyrene microtiter plates with poly-L-lysine and 0.2% glutaraldehyde. The eosinophils used in the radioimmunoassay and the subsequent biodistribution and imaging studies were purified from peripheral blood using differential centrifugation over Percoll (Sigma, St. Louis, MO) after stimulation with the chemoattractant f-met leu phe (Sigma) (12,13). The red cells were removed by hypotonic lysis in distilled water, and the eosinophils were then cryopreserved in fetal calf serum with 10% dimethylsulfoxide in liquid nitrogen.

Before use, the frozen eosinophils were thawed, pooled, and washed. This purification and cryopreservation procedure resulted in some disintegration of the eosinophils and the creation of peroxidase-coated cellular debris, which functioned as the target in the radioimmunoassay. Normally, peroxidase in intact eosinophils is exclusively localized within intracellular granules and is not accessible to antibody binding unless the cells are artificially permeabilized (unpublished data).

After blockage with 4 µg/ml of human IgG, the wells of the microtiter plates were washed and incubated at room temperature with 50 µl of serially diluted radiolabeled antibody for 45 min. The wells were then washed three times with PBS, and the bound radioactivity in each well was removed with 200 µl of 0.1 N HCl and counted in a well scintillation counter.

### Injection Protocol

Adult, female, BALB mice (Simonsen Laboratories, Gilroy, CA) weighing 16–21 grams were used in the imaging and distribution studies. The test and control animals were first given an i.v. injection into the tail of 150–300 µl of radiolabeled EOS antibody or radiolabeled negative control antibody (~15–30 µg/mouse; 8–13 µCi/mouse). Blood was not drawn into the syringes prior to injection; in some mice, there was infiltration of the tail. Doses were measured before and after injection in a dose calibrator. For accurate calculation of the injected dose, each syringe was also weighed before and after injection.

Immediately afterward, the test and control animals received a 100-µl intramuscular injection with a 27-gauge needle into the right thigh of 10<sup>6</sup> human eosinophils (12) that had been homogenized on ice for 10 sec with a Teflon tissue homogenizer and then adsorbed to an equal volume of 11-micron, latex microspheres (Sigma) in acetate buffer, pH 5.0. Eosinophil peroxidase is strongly cationic (12) and binds avidly in acetate buffer to the microspheres, which were used to deposit and maintain the target antigen in the thigh. The negative control animals also received an intramuscular injection into the left thigh of 100 µl of unlabeled microspheres in order to evaluate the amount of nonspecific localization of radiolabeled antibody to latex microspheres alone.

Radiolabeled antibody was injected intravenously prior to

the injection of the target antigen because of the scarcity of human eosinophils. We elected to inject with eosinophils only those animals that we believed had received a good, i.v. injection of antibody; this sequence of injections permitted us to make maximal use of the scarce and difficult-to-purify eosinophil target.

### Imaging Studies

At intervals of 6, 24, 48, and 72 hr after injection, groups of test mice were killed. Groups of control animals were killed at 24 hr and 48 hr after injection. Posterior scintiphotos were obtained shortly after sacrifice using a gamma camera equipped with a pinhole collimator positioned ~10 cm above the mouse. Twenty thousand counts were collected for each image.

### Biodistribution

Groups of test and control animals were necropsied at various intervals after injections of labeled antibody, and the organs and tissues listed in Tables 1 and 2 were sampled or removed. The samples were weighed in pre-tared test tubes and counted in a well scintillation counter along with diluted aliquots of the injected material.

Because of the unexpectedly high amounts of uptake of radiolabeled EOS antibody in the lungs and spleens of some of the test animals, biodistribution studies were also performed on normal mice at 24 and 48 hr after i.v. injection with radiolabeled EOS antibody. These studies were intended to determine if radiolabeled EOS antibody binds nonspecifically to murine lung and spleen. In addition, the lungs and spleens from two of the test animals were examined microscopically after fixation in B5. The tissues were subjected to standard dehydration in xylene followed by dekenkerization and paraffin embedding prior to sectioning and staining with hematoxylin and eosin.

To determine if radiolabeled EOS antibody binds to intact eosinophils in vivo, biodistribution studies were also performed on nine mice that had received intramuscular injections of 10<sup>6</sup> intact eosinophils into the right thigh. As internal controls, the left thighs of these mice received an injection of 0.1 ml PBS.

**TABLE 1**  
Biodistribution of Negative Control Antibody

Organ	% Injected dose/gram of tissue*	
	24 hr (n = 4)	48 hr (n = 5)
Blood	10.2 ± 5.6	5.8 ± 2.3
Heart	4.3 ± 1.6	5.2 ± 1.0
Lung	9.4 ± 1.9	11.0 ± 3.7
Liver	7.7 ± 1.9	9.6 ± 1.0
Spleen	9.6 ± 3.7	14.0 ± 4.1
Kidney	12.2 ± 6.0	17.2 ± 2.9
Stomach	2.5 ± 1.4	2.9 ± 1.4
Bone	3.5 ± 0.8	4.7 ± 0.6
Skin	4.4 ± 1.1	5.3 ± 1.0
Left thigh	2.5 ± 0.9	3.8 ± 2.6
Right thigh	6.3 ± 2.7	4.9 ± 1.9
Tail	9.5 ± 6.9	5.4 ± 0.7

\* Mean ± 1 s.d.

**TABLE 2**  
Biodistribution of Radiolabeled EOS Antibody in Test Animals

Organ	% Injected dose/gram of tissue <sup>*</sup>			
	6 hr (n = 3)	24 hr (n = 4)	48 hr (n = 5)	72 hr <sup>†</sup> (n = 2)
Blood	—	17.2 ± 3.5	10.1 ± 2.3	4.9
Heart	7.6 ± 1.5	9.6 ± 1.8	6.9 ± 2.4	5.9
Lung	27.3 ± 19.6	13.0 ± 1.8	17.2 ± 13.4	11.1
Liver	11.8 ± 1.0	12.8 ± 2.8	12.0 ± 1.2	12.1
Spleen	25.6 ± 8.7	23.5 ± 3.6	25.2 ± 1.7	23.3
Kidney	10.1 ± 1.9	11.8 ± 4.0	10.4 ± 1.6	10.1
Stomach	2.5 ± 1.3	4.5 ± 0.6	2.9 ± 0.6	3.2
Bone	5.5 ± 1.0	4.9 ± 1.1	5.3 ± 0.7	4.6
Skin	11.0 ± 5.5	5.5 ± 1.1	5.2 ± 1.2	4.5
Left thigh	1.8 ± 0.3	2.0 ± 0.4	2.0 ± 0.8	1.4
Right thigh	9.8 ± 1.9	28.9 ± 5.9	34.2 ± 2.2	30.4
Tail	23.5 ± 15.7	7.2 ± 4.0	4.2 ± 0.6	4.8

<sup>\*</sup> Mean ± 1 s.d.

<sup>†</sup> Mean of duplicate measurements.

## RESULTS

### Preparation of Labeled Antibody

Analysis by TLC of the initial reaction mixture indicated that 71%–78% of the <sup>111</sup>In was bound to antibody. After gel chromatographic purification, the final radiochemical purity of the preparations was determined to be 86%–95%. Analysis of the DTPA-conjugated EOS antibody by SDS-PAGE showed that a high molecular weight (>200,000 Daltons) protein was present in trace amounts, suggesting that DTPA-antibody undergoes some degree of self-aggregation.

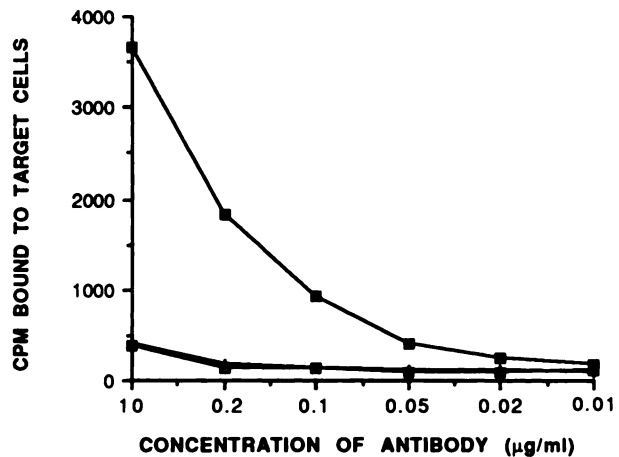
The results of the binding assay to target cells are presented in Figure 1. Note that radiolabeled EOS antibody binds only to freeze-thawed eosinophils and not to lymphocytes, while the radiolabeled negative control does not bind to the eosinophils. There was detectable binding to eosinophils at concentrations as low as 20 ng/ml of radiolabeled EOS.

### Imaging Studies

By 24 hr after injection, there was distinct localization of radiolabeled EOS antibody in the right thigh of test animals (Fig. 2), while the negative control antibody did not localize to microspheres or to eosinophils bound to microspheres (Fig. 3). At 48 hr, localization in the right thigh by radiolabeled EOS was even more intense (Fig. 4); by contrast, radiolabeled negative control antibody at 48 hr appeared to be distributed uniformly throughout the body, with only minimal localization to the eosinophils in the right thigh (Fig. 5). Similar results were observed in all of the animals that were imaged.

### Biodistribution

The results of the biodistribution studies are summarized in Tables 1–4. In Table 1, the negative control

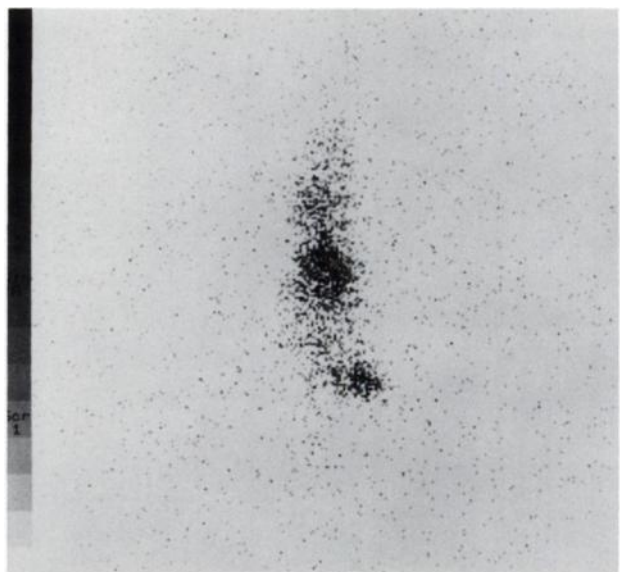


**FIGURE 1**

Cell binding assay using radiolabeled EOS and normal IgG. There is detectable binding of EOS to eosinophil target cells (closed squares) but not to lymphocyte target cells (open squares). Labeled normal IgG does not bind to eosinophils (+).

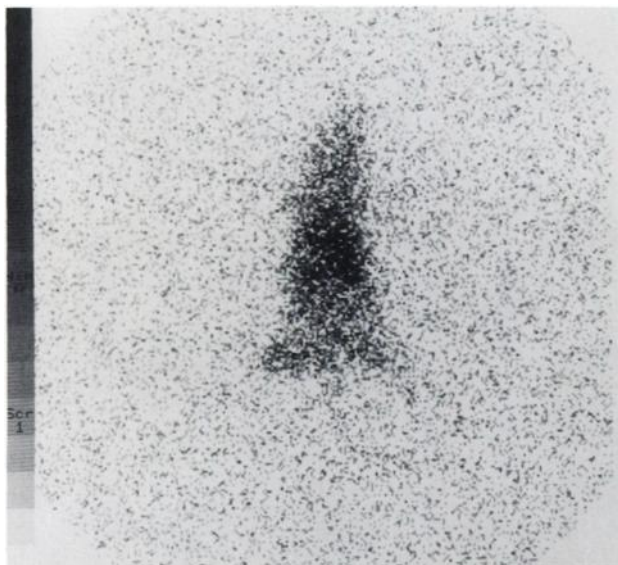
antibody had minimal localization to the left thigh (microspheres alone) and right thigh (eosinophils plus microspheres). The kidneys, spleens, and lungs of the negative control animals contained the highest percentage of injected dose per gram of tissue. The liver, however, contained the highest absolute amount of radiolabeled antibody when adjusted for the weight of the organ.

As soon as 6 hr after injection, there was significantly ( $p < 0.05$ ) more localization of radiolabeled EOS in the right thigh compared with the left thigh in test animals

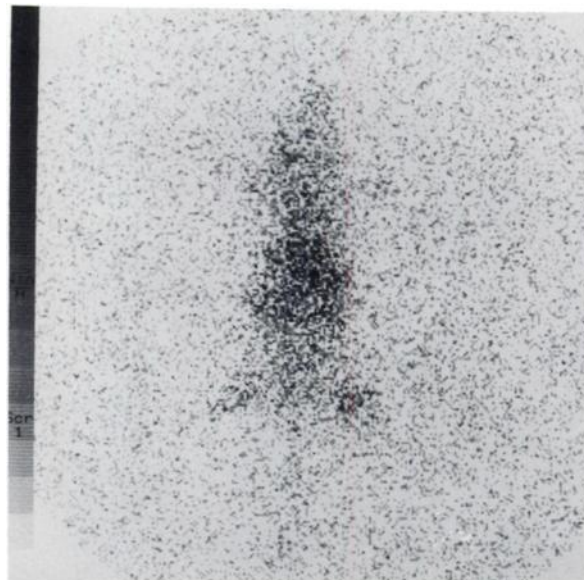


**FIGURE 2**

Imaging of representative test animal at 24 hr. Radiolabeled EOS antibody is distributed throughout the animal, and there is obvious localization to the right thigh, which was injected with the eosinophils and microspheres.



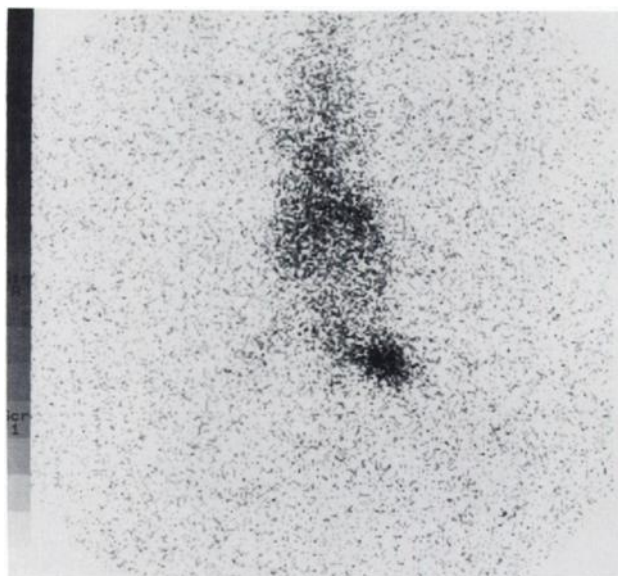
**FIGURE 3**  
Imaging of representative control animal at 24 hr. The radiolabeled normal IgG is distributed throughout the animal, and the right (microspheres alone) and left thighs (microspheres plus eosinophils) appear to have nearly equal signal intensity.



**FIGURE 5**  
Imaging of representative control animal at 48 hr. Negative control antibody remains distributed throughout the animal, with minimal localization to the right thigh (microspheres plus eosinophils).

(Table 2). The ratios of radiolabeled antibody in the right thigh compared to the left thigh were 5.4 at 6 hr, 14.5 at 24 hr, 17.1 at 48 hr, and 21.7 at 72 hr. At 24, 48, and 72 hr after injection, the right thigh contained the highest concentration of radiolabeled EOS of any organ tested.

In the tails of the test animals necropsied at 6 hr



**FIGURE 4**  
Imaging of representative test animal at 48 hr. Strong localization of radiolabeled EOS antibody is evident in the right thigh (microspheres plus eosinophils).

postinjection, there was a high mean activity ( $23.5\% \pm 15.7\%$  injected dose/gram). Because of technical problems, we did not measure the blood activity in the test mice at 6 hr. It should be noted, however, that when we corrected the data for activity left in the tails, there was no substantial change in the relative biodistribution of radiolabeled antibody in the organs (data not shown).

Because the lungs and spleens of the test animals injected with the EOS antibody contained higher concentrations of radiation than the negative control animals, biodistribution studies with radiolabeled EOS antibody were also performed in six normal mice (Table 3). The uptake of EOS antibody in the lungs of normal animals is less than the uptake in test animals. There is, however, some uptake of EOS antibody in the spleens of normal animals.

The lungs and spleens from two of the test animals that had received injections of EOS antibody and homogenized eosinophils were also examined microscopically for evidence of target antigen embolization. In the lungs (Fig. 6) and in the spleens (Fig. 7) of these test animals, there was obvious embolization of latex microspheres.

The results of the biodistribution studies in mice that had received injections of "intact," freeze-thawed eosinophils and EOS antibody are presented in Table 4. Again, there was some localization of EOS antibody in the spleens (18.0% of injected dose per gram of tissue; 2.3% of injected dose per whole organ). It is also notable that EOS antibody localized slightly to the "intact" (freeze-thawed) eosinophils in the right thigh. The binding to "intact" eosinophils, however, was substantially

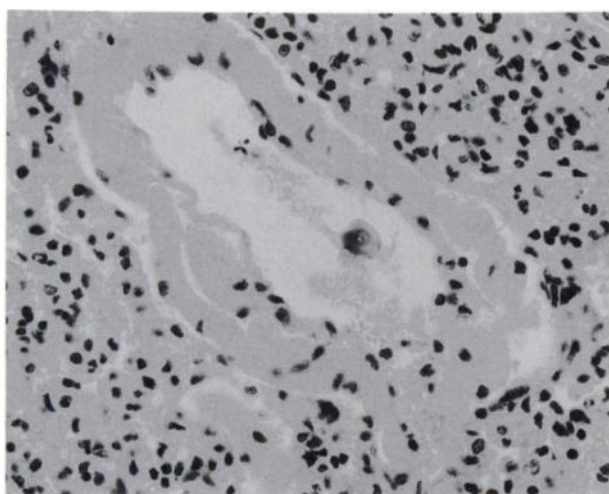
**TABLE 3**  
Biodistribution of EOS in Normal Mice

Organ	% Injected dose/gram of tissue	
	24 hr (n = 3)	48 hr (n = 3)
Blood	14.1 ± 6.7	9.4 ± 4.3
Heart	7.2 ± 2.9	5.9 ± 1.8
Lung	9.7 ± 3.3	8.3 ± 1.7
Liver	8.1 ± 2.5	9.4 ± 3.0
Spleen	24.9 ± 12.0	17.9 ± 5.2
Kidney	8.6 ± 3.1	7.0 ± 0.7
Stomach	1.5 ± 0.5	1.7 ± 0.7
Bone	3.5 ± 1.4	3.1 ± 0.8
Skin	5.8 ± 3.2	4.7 ± 0.7
Left thigh	1.9 ± 0.8	1.7 ± 0.1
Right thigh	2.4 ± 1.2	1.4 ± 0.2
Tail	11.6 ± 2.6	6.3 ± 2.9

less than the binding to homogenized eosinophils, listed in Table 2.

### DISCUSSION

The imaging and biodistribution studies described in this report have demonstrated that radiolabeled EOS antibody retains its affinity and avidity for eosinophil peroxidase and rapidly localizes *in vivo* to intramuscular deposits of as few as  $10^6$  degranulated human eosinophils. In addition, there was relatively little binding by EOS antibody to freeze-thawed, intact eosinophils. Radiolabeled normal IgG (the negative control) did not have detectable localization to the degranulated eosinophils or to the latex microspheres. This controlled study, therefore, provides evidence that human eosinophil peroxidase is potentially a suitable target for specific, *in vivo* radioimmuno-detection with the EOS antibody.



**FIGURE 6**  
Lung arteriole in a test animal at 48 hr. A purple, refractile microsphere is visible in the lumen. The dehydration in xylene and paraffin embedding of the tissue caused artifactual distortion of the microsphere. Original magnification 400×.



**FIGURE 7**  
Massive deposition of microspheres in the red pulp of the spleen of a test animal 48 hr after injection. Purple, refractile plastic particles are located between follicles and distort the focal plane of the image. Original magnification 250×.

Although there was high uptake of EOS antibody in the lungs of some test animals, this was probably the result of embolization of the target antigen on the microspheres to the lungs. On microscopic examination, there were numerous target microspheres in the lungs of some of the test animals, which probably accounts for the variation between animals. Moreover, uptake of labeled EOS antibody was much lower in the lungs of the normal mice listed in Tables 3 and 4.

There is some splenic uptake of EOS antibody. We speculate that the highly variable "localization" of radiolabeled EOS to the spleen is attributable to the variable and unpredictable amount of embolization of target microspheres to the spleens of different animals, as shown in our histologic studies. In addition, our SDS-PAGE analysis indicated that small amounts of microaggregates or polymers of DTPA-conjugated antibody were present in our injected preparations. After

**TABLE 4**  
Biodistribution of EOS in Mice with Intact Eosinophils

Organ	% Injected dose/gram of tissue	
	24 hr (n = 4)	48 hr (n = 5)
Blood	20.8 ± 3.2	11.2 ± 2.1
Heart	8.0 ± 0.5	6.5 ± 1.1
Lung	12.0 ± 1.2	8.9 ± 0.9
Liver	9.3 ± 1.9	8.7 ± 1.0
Spleen	18.0 ± 4.4	18.0 ± 6.5
Kidney	9.0 ± 1.3	7.6 ± 1.7
Stomach	2.7 ± 0.9	2.0 ± 0.5
Bone	4.1 ± 0.7	3.7 ± 0.4
Skin	4.9 ± 1.3	3.9 ± 0.5
Left thigh	1.9 ± 0.5	1.6 ± 0.2
Right thigh	5.8 ± 1.0	6.0 ± 2.1
Tail	5.8 ± 1.9	7.3 ± 3.2

an i.v. injection, these aggregates could be cleared by the spleen, thus explaining the relatively high uptake of DTPA- antibody by the spleens.

Our findings may have considerable practical significance for developing new imaging, staging, and therapeutic approaches to those tumors and parasitic diseases which contain eosinophil degranulation (1-10). In particular, Hodgkin's disease is a good candidate for imaging and therapy with radiolabeled EOS antibody because the peroxidase target antigen is much more abundant in Hodgkin's disease than the Ki-1 and CD30 antigens on Reed-Sternberg cells, which have recently been proposed as targets for radioimmunodetection and therapy (17,18). In our studies, for example, eosinophil peroxidase from as few as  $10^6$  eosinophils (20  $\mu$ l packed cells) was readily imaged; it should be emphasized that eosinophils far exceed Reed-Sternberg cells in tissues involved with Hodgkin's disease.

Radiolabeled EOS antibody, therefore, may complement other approaches such as radiolabeled antiferritin, which has been used with some success for the systemic therapy of advanced Hodgkin's disease (19) or gallium-67, which is being used as an imaging agent for lymphomas (20-23). In future reports, therefore, we hope to describe clinical applications of radiolabeled EOS antibody to the imaging of human subjects with Hodgkin's disease.

## ACKNOWLEDGMENTS

The excellent technical assistance of Haresh Majmudar in performing the imaging studies is gratefully acknowledged. This work was made possible by a grant from the Public Health Service (CA48713) and was presented in part at the Fifth International Conference on Monoclonal Antibody Immunocjugates in San Diego, California, on March 17, 1990.

## REFERENCES

- Looi LM. Tumor-associated tissue eosinophilia in nasopharyngeal carcinoma. *Cancer* 1987;59:466-470.
- Slungaard A, Ascensao J, Zanjani E, Jacobs HS. Pulmonary carcinoma with eosinophilia. *N Engl J Med* 1983;309:778-781.
- McGinnis MC, Bradley EL, Pretlow TP, et al. Correlation of stromal cells by morphometric analysis with metastatic behavior of human colonic carcinoma. *Cancer Res* 1989;49:5989-5993.
- Watanabe K, Shinbo T, Kojima M, Naito M, Tanahashi N, Nara M. B-cell lymphoma associated with eosinophilia. *Cancer* 1989;64:1682-1685.
- Vukelja SJ, Weiss RB, Perry DJ, Longo DL. Eosinophilia associated with adult T-cell leukemia/lymphoma. *Cancer* 1988;62:1527-1530.
- Vaage J, Pepi KG, Au TL. Immunospecific eosinophil infiltration of a mouse mammary carcinoma. *Cancer Res* 1986;46:5344-5348.
- Butterfield JH, Kephart GM, Banks PM, Gleich GJ. Extracellular deposition of eosinophil granule major basic protein in lymph nodes of patients with Hodgkin's disease. *Blood* 1986;68:1250-1256.
- Samoszuk MK, Nathwani BN, Lukes RJ. Extensive deposition of eosinophil peroxidase in Hodgkin's and non-Hodgkin's lymphomas. *Am J Pathol* 1986;125:426-429.
- Tai PC, Spry CJF, Olsen EGJ, Ackerman SJ, Dunnette S, Gleich GJ. Deposits of eosinophil granule proteins in cardiac tissues of patients with eosinophilic endomyocardial disease. *Lancet* 1987;8534:643-647.
- Kephart GM, Andrade ZA, Gleich GJ. Localization of eosinophil major basic protein onto eggs of *Schistosoma mansoni* in human pathologic tissue. *Am J Pathol* 1988;133:389-396.
- Samoszuk MK, Espinoza FP. Deposition of autofluorescent eosinophil granules in pathologic bone marrow biopsies. *Blood* 1987;70:597-599.
- Samoszuk MK, Petersen A, Gidanian F, Rietveld C. Cytophilic and cytotoxic properties of human eosinophil peroxidase plus major basic protein. *Am J Pathol* 1988;132:455-460.
- Samoszuk MK, Sholly S, Epstein AL. Eosinophil peroxidase is detectable with a monoclonal antibody in collagen bands of nodular sclerosis Hodgkin's disease. *Lab Invest* 1987;56:394-400.
- Samoszuk MK, Petersen A, Lo-Hsueh M, Rietveld C. A peroxide-generating immunoconjugate directed to eosinophil peroxidase is cytotoxic to Hodgkin's disease cells in vitro. *Antibody Immunocnj Radiopharm* 1989;2:37-46.
- Hnatowich DJ, Childs RL, Lanteigne D, Najafi A. The preparation of DTPA-coupled antibodies radiolabeled with metallic radionuclides: an improved method. *J Immunol Meth* 1983;65:147-157.
- Rubin RH, Fischman AJ, Needleman M, et al. Radiolabeled, nonspecific, polyclonal human immunoglobulin in the detection of focal inflammation by scintigraphy: comparison with gallium-67-citrate and technetium-99m-labeled albumin. *J Nucl Med* 1989;30:385-389.
- Burrichter H, Rossbach C, Gielow P, Schaadt M, Hundeshagen H, Diehl V. Radioimmunodetection of Hodgkin tumors in nude mice. In: Winkler C, ed. *Nuclear medicine in clinical oncology*. Berlin: Springer-Verlag; 1986:383-390.
- Engert A, Burrows F, Jung W, et al. Evaluation of ricin-A chain-containing immunotoxins directed against the CD30 antigen as potential reagents for the treatment of Hodgkin's disease. *Cancer Res* 1990;50:84-88.
- Lenhard RE, Order SE, Spunberg JJ, Asbell SO, Leibel SA. Isotopic immunoglobulin: a new systemic therapy for advanced Hodgkin's disease. *J Clin Oncol* 1985;3:1296-1300.
- Turner DA, Fordham EW, Ali A, Slayton RE. Gallium-67 imaging in the management of Hodgkin's disease and other malignant tumors. *Semin Nucl Med* 1978;8:205-218.
- Bekerman C, Hoffer PB, Bitran JD. The role of gallium-67 in the clinical evaluation of cancer. *Semin Nucl Med* 1984;14:296-323.
- Zollars LE, Nagel S, Tumei SS. Three cases demonstrating the role of gallium scanning in relapsing Hodgkin's disease and non-Hodgkin's lymphoma. *J Nucl Med* 1987;28:1611-1615.
- Israel O, Front D, Epelbaum R, et al. Residual mass and negative gallium scintigraphy in treated lymphoma. *J Nucl Med* 1990;31:365-368.