

---

# Critical Cerebral Blood Flow Thresholds Studied by SPECT Using Xenon-133 and Iodine-123 Iodoamphetamine

Shinichi Nakano, Kazuo Kinoshita, Seishi Jinnouchi, Hiroaki Hoshi, and Katsushi Watanabe

*Departments of Neurosurgery and Radiology, Miyazaki Medical College, Miyazaki, Japan*

Regional cerebral blood flow (rCBF) was assessed in patients with cerebrovascular diseases (CVD) by single photon emission computed tomography (SPECT) using  $^{133}\text{Xe}$  and N-isopropyl-p-[ $^{123}\text{I}$ ]iodoamphetamine ([ $^{123}\text{I}$ ]IMP). The purpose of this study was to determine the infarcted and symptomatic blood flow thresholds of cerebral cortex by SPECT. In the  $^{133}\text{Xe}$  inhalation method rCBF was calculated by employing the Celsis modification of the Kanno and Lassen algorithm. In the [ $^{123}\text{I}$ ]IMP SPECT quantitation was obtained by counting-rate ratio for the low flow lesion to the contralateral homologous region which was presumed to be normal (Lesion/Normal ratio, L/N ratio). The infarcted and symptomatic blood flow thresholds by  $^{133}\text{Xe}$  SPECT were 19–23 and 33–36 ml/100 g/min, respectively. While, those of L/N ratio in the [ $^{123}\text{I}$ ]IMP SPECT were 39–48 and 65–72%, respectively. There was a significant correlation between the ischemic degrees evaluated by  $^{133}\text{Xe}$  and [ $^{123}\text{I}$ ]IMP SPECT studies.

J Nucl Med 30:337–342, 1989

---

The critical relationship between cerebral electrical activity and blood flow was first observed during carotid endarterectomy by electroencephalogram (EEG) monitoring and xenon-133 ( $^{133}\text{Xe}$ ) intracarotid injection techniques. These studies have demonstrated a threshold of 17–18 ml/100 g/min for EEG flattening (1–4). Since then many experimental studies on focal ischemia have developed a concept of “ischemic flow thresholds” (5–8). In experimental studies the ischemic flow threshold of synaptic transmission failure and membrane failure were estimated at 16–20 and 6–8 ml/100 g/min, respectively. The threshold concept is helpful for the management of acute ischemic stroke. Evaluation of residual flow in the ischemic brain tissue is very important to evaluate prognosis and make a therapeutic plan.

Recently regional cerebral blood flow (rCBF) has been measured widely. Xenon-133 had been the most widely used tracer in measurement of rCBF with single photon emission computed tomography (SPECT). N-isopropyl-p-[ $^{123}\text{I}$ ]iodoamphetamine ([ $^{123}\text{I}$ ]IMP), a new lipophilic radiopharmaceutical, has become to be used

widely and provides rCBF images of higher quality. We measured rCBF in patients with cerebrovascular diseases (CVD) with SPECT using  $^{133}\text{Xe}$  and [ $^{123}\text{I}$ ]IMP and tried to determine the infarcted and symptomatic blood flow thresholds of cerebral cortex.

## MATERIALS AND METHODS

### Patient Selection

This study includes 24 patients with CVD, 20 males and four females, aged 6 to 83 yr (median age 47 yr). Of these 24 patients, nine had cortical infarctions, 11 had lacunar infarctions, and the remaining four patients had only transient ischemic attacks (TIAs). All patients but one (Case 16) with lacunar infarctions or TIAs had occlusive or stenotic changes of large cerebral arteries. The other patient with TIA (Case 16) had Sturge-Weber disease and his angiography showed A-V shunt and early venous drainage. In these patients all SPECT studies were performed within 3 days from the onset of CVD. All patients underwent neurologic examination, x-ray computed tomography (CT) scan and angiographies. All were awake and their PaCO<sub>2</sub> values were normal (Table 1).

The low flow lesions were separated into three groups from the findings of CT scan and neurologic examination. Group 1 means large infarctions with cortical involvement which resulted in irreversible neurologic deficits. These lesions were

---

Received May 27, 1988; revision accepted Oct. 13, 1988.

For reprints contact: Shinichi Nakano, MD, Dept. of Neurosurgery, Miyazaki Medical College, 5200, Kihara, Kiyotake, Miyazaki, 889-16, Japan.

**TABLE 1**  
Clinical Data of the 24 Patients in This Study

Group	Case no.	Age (yr)	Sex	CT	Angiography	<sup>133</sup> Xe rCBF (ml/100 g/min)	L/N ratio	PaCO <sub>2</sub> (mmHg)
1	1	42	M	C	ICA occlusion	14 (35%)	31%	38.6
	2	51	M	C	ICA occlusion	16 (40%)	30%	42.1
	3	56	M	C	MCA occlusion	15 (37%)	27%	40.3
	4	54	M	C	MCA occlusion	18 (36%)	37%	42.3
	5	50	M	C	MCA occlusion	19 (43%)	34%	40.0
	6	83	M	C	MCA embolism	4 (9%)	24%	44.2
	7	62	M	C	PCA occlusion	13 (32%)	22%	41.1
	8	54	M	C	PCA occlusion	16 (37%)	39%	39.2
	9	70	M	C	PCA occlusion	18 (25%)	28%	45.1
2	10	42	M	N	ICA occlusion	26 (49%)	53%	37.2
	11	56	M	L	MCA occlusion	27 (66%)	52%	39.8
	12	55	M	L	MCA occlusion	23 (56%)	48%	42.1
	13	25	M	L	MCA occlusion	30 (57%)	54%	38.0
	14	60	M	N	PCA occlusion	28 (62%)	64%	43.3
	15	40	F	N	PCA occlusion	33 (57%)	54%	39.2
	16	14	M	N	A-V shunt	30 (60%)	65%	38.3
3	17	68	F	L	MCA occlusion	46 (70%)	81%	42.5
	18	26	M	L	MCA occlusion	40 (83%)	78%	40.1
	19	53	M	L	MCA occlusion	36 (73%)	72%	39.6
	20	50	M	L	MCA occlusion	42 (79%)	82%	38.8
	21	55	F	L	MCA stenosis	44 (89%)	87%	43.5
	22	6	M	L	MCA stenosis	51 (82%)	77%	40.3
	23	53	F	L	MCA stenosis	52 (84%)	87%	41.5
	24	14	M	L	MCA stenosis	55 (79%)	85%	37.5

CT findings: C : cortical infarction; L: lacunar infarction; N : normal.

Angiography: ICA: internal carotid artery; MCA: middle cerebral artery; PCA : posterior cerebral artery.

delineated as low density areas in CT scans. Group 2 means reversible cortical dysfunctions, so called zone of "ischemic penumbra". At the time of examination the cortical functions were disturbed, whereas they had full recovery later (within 14 days) and CT scan revealed no abnormal density area in the cerebral cortex.

It could not be determined whether hemiplegia resulted from cortical or white matter dysfunctions. Thus the cortical dysfunctions evaluated in this study were only motor aphasia and homonymous hemianopsia. Group 3 means low flow lesions with preserved normal cortical functions, so called zone of "misery perfusion". The cortical ischemia of Group 3 was accompanied with occlusive or stenotic changes of large cerebral arteries. Cortical low flow was delineated well by SPECT studies, whereas CT scan revealed no abnormal density area in the cerebral cortex and neurologic examination revealed no cortical dysfunction. Cortical low flow happened to be found by the chance in lacunar infarctions.

#### Patients Preparation

Measurements of rCBF were performed with SPECT using <sup>133</sup>Xe and [<sup>123</sup>I]IMP. The patients were placed in a supine position in a quiet room with their eyes closed. At first they breathed <sup>133</sup>Xe gas at a concentration of 10 mCi/l for 1 min with a nose clamp and a rubber mouthpiece connected to the

Ventil-Con spirometer. Then the spirometer was switched to open circuit and measurements continued for further 9 min. Iodine-123 IMP SPECT followed <sup>133</sup>Xe SPECT. Prior to injection of [<sup>123</sup>I]IMP, which was free of iodine-124 and contained at most 4.5% of iodine-125, the patients had been given iodine solution to block the thyroid. The data acquisition started 30 min after injection of 3 mCi of [<sup>123</sup>I]IMP.

#### Data Acquisition and Analysis

This study was performed with a ring-type gamma camera (SET020, Shimazu, Co., Kyoto, Japan) which consists of a gantry assembly with 64 scanning detectors. This system has two rings and simultaneously acquires two parallel slices with a center-to-center interslice distance of 3.5 cm. A high resolution (HR) collimator was used in the [<sup>123</sup>I]IMP SPECT and a hypersensitive (HS) one was done in the <sup>133</sup>Xe SPECT. The raw data were reconstructed by the method of filtered back-projection, using a Ramachandran-Butterworth filter. Filter order was 8 and cutoff frequencies were 24 and 28 mm for <sup>133</sup>Xe and [<sup>123</sup>I]IMP studies, respectively. Reconstruction was performed using a Data General Eclipse S-120 processor for a 64 × 64 matrix image in the [<sup>123</sup>I]IMP SPECT and a 32 × 32 matrix in the <sup>133</sup>Xe SPECT. Slice thicknesses were 16 and 24 mm in HR and HS collimators, respectively. In the <sup>133</sup>Xe SPECT the calculation of rCBF was performed by employing

the Celsis modification of the Kanno and Lassen algorithm (9,10). The total count for  $^{133}\text{Xe}$  SPECT was ~150,000–200,000 counts. In  $^{123}\text{I}$ IMP SPECT, data acquisition lasted until 600,000 counts were collected. Data analysis was done without smoothing. In each group a circle region of interest (ROI) of 1.75 cm diameter ( $4 \times 4$  matrix in the  $^{123}\text{I}$ IMP SPECT) was placed over the low flow lesion of the cerebral cortex. For comparison an equal size ROI was placed over the contralateral homologous region. In Group 1, ROI was placed over the cerebral cortex which was delineated as a low density area in CT scan. In Group 2, ROI was placed over the frontal operculum or occipital cortex. In Group 3, ROI was placed over the frontal operculum. In the  $^{133}\text{Xe}$  SPECT, rCBF of the low flow lesion and contralateral homologous region were calculated and then the ratio for the former to the latter was also calculated. In the  $^{123}\text{I}$ IMP SPECT, the counting-rate ratio for the low flow lesion to the contralateral homologous region (Lesion/Normal ratio, L/N ratio), was calculated (Fig. 1). As side to side comparison of the counting-rate is most meaningful in cases with normal rCBF in the contralateral homologous tissue, this study included only those with cortical flows above 40 ml/100 g/min in the homologous tissue.

The statistical differences of  $^{133}\text{Xe}$  rCBF and L/N ratios between Group 1 and 2 and Group 2 and 3 were evaluated by Student's t-test.

## RESULTS

The clinical data of the 24 patients and the blood flow values of the low flow lesions of all groups are summarized in Table 1 and Table 2.

Group 1 contained nine patients with large cerebral infarctions with cortical involvement. All of them had

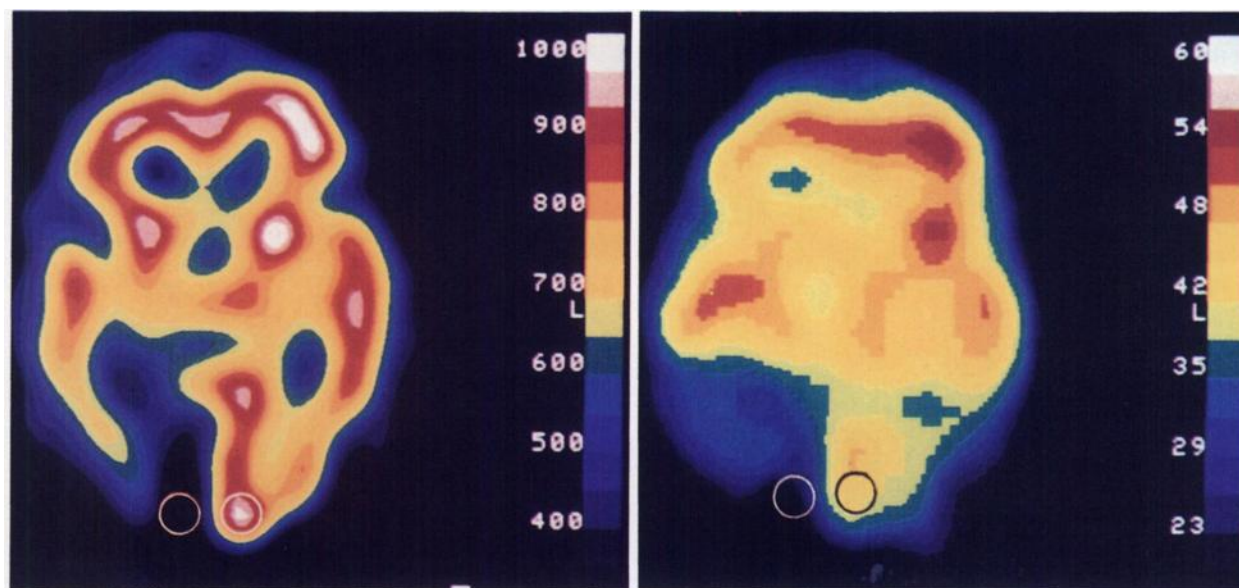
**TABLE 2**  
 $^{133}\text{Xe}$  rCBF and L/N Ratio in Each Group  
(mean value  $\pm$  s.d.)

	$^{133}\text{Xe}$ rCBF (ml/100 g/min)	L/N ratio (%)
Group 1 (n = 9)	14.8 $\pm$ 4.2 (32.7 $\pm$ 9.6%)	30.2 $\pm$ 5.4
Group 2 (n = 7)	28.1 $\pm$ 3.0 (58.1 $\pm$ 4.9%)	55.7 $\pm$ 5.9
Group 3 (n = 8)	45.8 $\pm$ 6.1 (79.9 $\pm$ 5.7%)	81.1 $\pm$ 4.9

occlusive or stenotic changes of large cerebral arteries. Group 2 contained seven patients. Of these seven patients, two (Cases 14 and 15) showed complete recovery from homonymous hemianopsia within 24 hr after the onset, three (Cases 10, 11, and 12) showed complete recovery from motor aphasia within 3 days and the remaining two (Cases 13 and 16) required 10 and 14 days to recover from motor aphasia, respectively. Group 3 contained eight patients with lacunar infarctions. These patients had only hemiparesis which was considered to have resulted from lacunar infarctions by CT scan. All of them had occlusive or stenotic changes of large cerebral arteries and the cerebral cortex was delineated as a low flow area in SPECT studies.

### Xenon-133 rCBF

Xenon-133 rCBF of the infarcted areas (Group 1) were at most 19 ml/100 g/min. Xenon-133 rCBF of the reversible symptomatic lesions (Groups 2) ranged between 23 and 33 ml/100 g/min. While those of asymptomatic low flow lesions (Group 3) were at least



**FIGURE 1**

A 62-yr-old man with cortical infarction in the right occipital lobe (Case 7). Left:  $^{133}\text{Xe}$  SPECT, Right:  $^{123}\text{I}$ IMP SPECT. These SPECT studies were performed on the next day of sudden onset of left homonymous hemianopsia. Xenon-133 rCBF value in the infarct area was 13 ml/100 g/min (32%) and L/N ratio in the  $^{123}\text{I}$ IMP SPECT was 22%. Iodine-123 IMP SPECT had higher spatial resolution than  $^{133}\text{Xe}$  SPECT.

36 ml/100 g/min. The infarcted flow threshold determined from the combined data of Groups 1 and 2 was 19–23 ml/100 g/min. While the symptomatic flow threshold determined from the combined data of Groups 2 and 3 was 33–36 ml/100 g/min. The statistical differences of  $^{133}\text{Xe}$  rCBF values between Groups 1 and 2 and Groups 2 and 3 were highly significant ( $p < 0.001$ ).

#### Iodine-123 IMP SPECT

The L/N ratios in the [ $^{123}\text{I}$ ]IMP SPECT of the infarcted areas (Group 1) were at most 39%. The L/N ratios of the reversible symptomatic lesions (Group 2) ranged between 48% and 65%. While, those of the asymptomatic low flow lesions (Group 3) were at least 72%. The infarcted and symptomatic thresholds of L/N ratios determined in the same manner as described above were 39–48 and 65–72%, respectively. The statistical differences of L/N ratios between Groups 1 and 2 and Groups 2 and 3 were highly significant ( $p < 0.001$ ). There was a significant correlation between the ischemic degrees evaluated by  $^{133}\text{Xe}$  and [ $^{123}\text{I}$ ]IMP SPECT studies ( $p < 0.001$ , Fig. 2).

## DISCUSSION

#### Critical Cerebral Blood Flow Thresholds

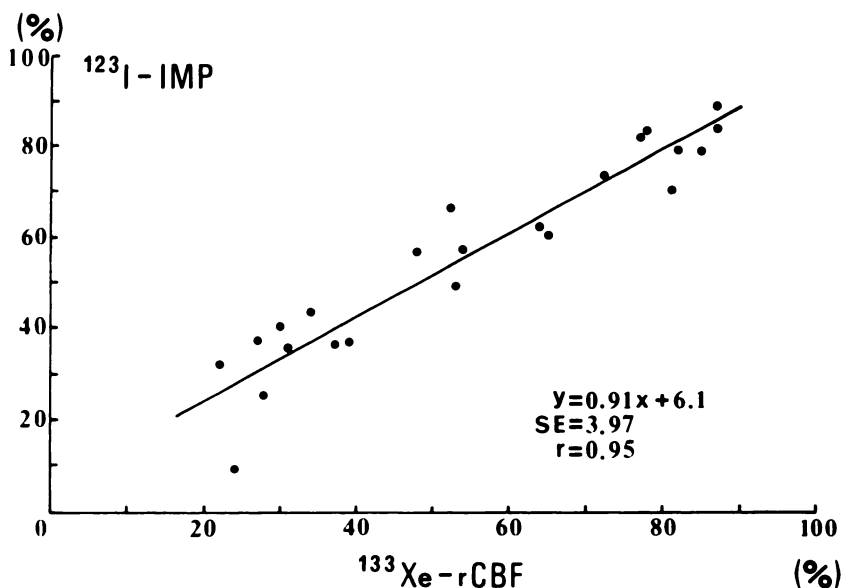
Many experimental studies on cerebral ischemia have demonstrated the existence of two separate thresholds, symptomatic and infarcted flow thresholds (5–8). According to Jones et al. (7) in monkeys mild reversible neurologic deficits could be detected when rCBF fell below ~23 ml/100 g/min. However, the development of infarction is a function of intensity and duration of ischemia. After 2 to 3 hr of middle cerebral artery (MCA) occlusion rCBF below 10 to 12 ml/100 g/min

led to infarction, whereas with permanent MCA occlusion rCBF below 17 to 18 ml/100 g/min was associated with infarction. They suggested an infarcted threshold, rising over some hours to a plateau at ~17 ml to 18 ml/100 g/min, below which normal tissue structure is irreversibly damaged. In a similar model in cats it has been shown that spontaneous neurologic activity ceases at flows below 18 ml/100 g/min (6).

#### Methodologic Problems

The establishment of the precise critical cerebral blood flow thresholds is difficult for variations of rapidity and duration of ischemia, tissue vulnerability, and cerebral metabolic rate. Particularly the development of infarction is too complex to be described by simple threshold concepts (7,8,11–13). Even profound ischemia is reversible for a short time. Regional cerebral metabolic rate of oxygen (rCMRO<sub>2</sub>) or glucose (rCMRglu) may be more important factors of cerebral function and viability. It is very important to evaluate these metabolic rates in distinguishing reversible ischemic neurologic deficits from irreversible ones. However, these metabolic rates can be measured at present only by positron emission tomography (PET) techniques. Thus, for practical use, we determined the approximate critical lower thresholds of cortical rCBF by SPECT using  $^{133}\text{Xe}$  and [ $^{123}\text{I}$ ]IMP.

There are two other methodologic problems in determining the critical lower thresholds of rCBF by SPECT. The first one is the partial volume averaging resulting from limited spatial resolution. Particularly,  $^{133}\text{Xe}$  SPECT had poor spatial resolution and rCBF values are greatly influenced by surrounding tissue. In the evaluation of small low flow lesions, the impact of the partial volume effect may be important. In this study we selected only the patients with relatively large low flow lesions in the cerebral cortex in order to maintain



**FIGURE 2**  
Correlation between L/N ratios in the [ $^{123}\text{I}$ ]IMP SPECT and those of  $^{133}\text{Xe}$  rCBF values ( $p < 0.001$ ).

the impact of partial volume effect. Therefore, the difference of the impact of partial volume effect between  $^{133}\text{Xe}$  and [ $^{123}\text{I}$ ]IMP SPECT studies was not clear in our study. The second one is the presence of luxury perfusion which increase rCBF values of the low flow lesions. In this study SPECT studies in more than 3 days after the onset of CVD were excluded to prevent the influence of luxury perfusion.

#### Xenon-133 SPECT Studies

It was difficult to establish the precise infarcted and symptomatic thresholds of  $^{133}\text{Xe}$  rCBF from this study. However, all the low flow lesions with  $^{133}\text{Xe}$  rCBF below 19 ml/100 g/min fell into infarctions and all the low flow lesions with  $^{133}\text{Xe}$  rCBF above 23 ml/100 g/min were reversible. Thus the infarcted threshold of  $^{133}\text{Xe}$  rCBF seemed to be between 19 and 23 ml/100 g/min. On the other hand, the maximum  $^{133}\text{Xe}$  rCBF value of Group 2 was 33 ml/100 g/min, whereas the minimum one of Group 3 was 36 ml/100 g/min. Thus the symptomatic threshold of  $^{133}\text{Xe}$  rCBF seemed to be between 33 and 36 ml/100 g/min.

These critical thresholds of  $^{133}\text{Xe}$  rCBF defined by  $^{133}\text{Xe}$  inhalation method were consistent with the previous studies by intraarterial  $^{133}\text{Xe}$  injection method during carotid endarterectomy. Their studies have demonstrated that major EEG changes occurred with a flow below 16 to 20 ml/100 g/min and no EEG change was seen with the flow above 30 ml/100 g/min (1-4). Our results were also consistent with those of PET studies (14,15). Yamamoto et al. (14) reported that a reduction in rCBF from 29 to 21 ml/100 g/min showed no abnormality of CT scan even in patients with transient focal ischemic attacks and that a reduction in rCBF below 20 ml/100 g/min showed various degrees of focal low density. Lenzi et al. (15) also reported that in the early phase of ischemic insult an absolute decrease of rCBF below 20 ml/100 g/min seemed to correlate with poor clinical outcome and that all patients with a rCBF above 20 ml/100 g/min showed some clinical improvement. However, in a recent PET study Powers et al. (16,17) demonstrated lower thresholds in patients with subacute or chronic causes of ischemia such as vasospasm or atherosclerosis. They reported that rCBF above 19 ml/100 g/min is adequate to maintain normal cerebral function and that rCBF above 15 ml/100 g/min is adequate to preserve tissue viability. These thresholds are apparently lower than those obtained by other PET studies (14,15). These findings may suggest that brain tissue can tolerate gradual development of severe ischemia with rCBF below 20 ml/100 g/min.

#### Iodine-123 IMP SPECT Studies

Iodine-123 IMP is distributed in correlation to rCBF and is useful for imaging relative rCBF (18-21). Raynaud et al. (22) reported L/N ratios of chronic infarcted areas. However, there has been no previous report of

ischemic thresholds studied by [ $^{123}\text{I}$ ]IMP SPECT because it cannot provide absolute values of rCBF. We tried to make a quantitative analysis of rCBF in the [ $^{123}\text{I}$ ]IMP SPECT using L/N ratios.

In this study all the low flow lesions with L/N ratios below 39% fell into infarctions and all the low flow lesions with L/N ratios above 48% were reversible. While, all the low flow lesions with L/N ratios below 65% were symptomatic and all the low flow lesions with L/N ratios above 72% were asymptomatic. Thus the infarcted and symptomatic thresholds of L/N ratio were 39-48% and 65-72%, respectively.

Iodine-123 IMP SPECT has higher spatial resolution than  $^{133}\text{Xe}$  SPECT, and L/N ratios enabled to make a quantitative analysis of rCBF even in the [ $^{123}\text{I}$ ]IMP SPECT. Furthermore, there was a good correlation between the ischemic degrees evaluated by  $^{133}\text{Xe}$  and [ $^{123}\text{I}$ ]IMP SPECT studies. Thus [ $^{123}\text{I}$ ]IMP SPECT seemed to be the examination of first choice to evaluate rCBF in patients with CVD.

However, [ $^{123}\text{I}$ ]IMP cannot provide absolute values of rCBF and cannot detect the decrease of rCBF in the nonaffected cerebral hemisphere as a result of diaschisis. Unless the uptake of [ $^{123}\text{I}$ ]IMP in the nonaffected cerebral hemisphere is normal, side to side comparison (L/N ratio) becomes meaningless. Thus the patients with  $^{133}\text{Xe}$  rCBF in the nonaffected cerebral cortex below 40 ml/100 g/min were excluded from this study. It is recommended that  $^{133}\text{Xe}$  SPECT should be performed in patients with bilateral cerebral ischemia.

#### CONCLUSION

Iodine-123 IMP SPECT provided good rCBF images with high spatial resolution and L/N ratios enabled to make a quantitative analysis of rCBF even in the [ $^{123}\text{I}$ ]IMP SPECT. There was a significant correlation between the ischemic degrees evaluated by  $^{133}\text{Xe}$  and [ $^{123}\text{I}$ ]IMP SPECT studies. Therefore, [ $^{123}\text{I}$ ]IMP SPECT is the examination of first choice to evaluate rCBF in patients with cerebrovascular diseases.

The infarcted and symptomatic blood flow thresholds by  $^{133}\text{Xe}$  SPECT were 19-23 and 33-36 ml/100 g/min, respectively, while those of L/N ratio in the [ $^{123}\text{I}$ ]IMP SPECT were 39-48% and 65-72%, respectively.

#### REFERENCES

1. Boysen G. Cerebral blood flow measurement as a safeguard during carotid endarterectomy. *Stroke* 1971; 2:1-10.
2. Trojaborg W, Boysen G. Relation between EEG, regional cerebral blood flow and internal carotid artery pressure during carotid endarterectomy. *Electroenceph Clin Neurophysiol* 1973; 34:61-69.
3. Sharbrough FW, Messick JM Jr, Sundt TM. Correlation of continuous electroencephalograms with cerebral blood flow measurements during carotid endarterectomy. *Stroke* 1973; 4:674-683.
4. Sundt TM, Sharbrough PW, Anderson RE, et al.

- Cerebral blood flow measurements and electroencephalograms during carotid endarterectomy. *J Neurosurgery* 1974; 41:310-320.
5. Branston MM, Symon L, Crockard HA, et al. Relationship between the cortical evoked potential and local cortical blood flow following acute middle cerebral artery occlusion in the baboon. *Exp Neurol* 1974; 45:195-208.
  6. Heiss WD, Hayakawa T, Waltz AG. Cortical neuronal function during ischemia. Effects of occlusion of one middle cerebral artery on single-unit activity in cats. *Arch Neurol* 1976; 33:813-820.
  7. Jones TH, Morawetz RB, Crowell RM, et al. Thresholds of focal cerebral ischemia in awake monkeys. *J Neurosurg* 1981; 54:773-782.
  8. Astrup J. Energy-requiring cell functions in the ischemic brain. *J Neurosurg* 1982; 56:482-497.
  9. Kanno I, Lassen NA. Two methods for calculating regional cerebral blood flow from emission computed tomography of inert gas concentrations. *J Comput Assist Tomogr* 1979; 3:71-76.
  10. Celsis P, Goldman T, Henriksen L, et al. A method for calculating regional cerebral blood flow from emission computed tomography of inert gas concentrations. *J Comput Assist Tomogr* 1981; 5:641-645.
  11. Heiss WD, Rosner G. Functional recovery of cortical neurons as related to degree and duration of ischemia. *Ann Neurol* 1983; 14:294-301.
  12. Marcoux FW, Morawetz RB, Crowell RM, et al. Differential regional vulnerability in transient focal cerebral ischemia. *Stroke* 1982; 13:339-346.
  13. Morawetz RB, Marcoux FW, Crowell RM, et al. Identical thresholds for cerebral ischemia in white and gray matter. *Acta Neurol Scand Suppl* 1979; 72, 60:282-283.
  14. Yamamoto YL, Little J, Meyer E, et al. Evaluation of <sup>77</sup>Kr positron emission tomographic studies in stroke. *J Comput Assist Tomogr* 1978; 2:663-664.
  15. Lenzi GL, Frackowiak RSJ, Jones T. Cerebral oxygen metabolism and blood flow in human cerebral ischemic infarction. *J Cereb Blood Flow Metab* 1982; 2:321-335.
  16. Powers WJ, Grubb RL Jr, Baker RP, et al. Regional cerebral blood flow and metabolism in reversible ischemia due to vasospasm. Determination by positron emission tomography. *J Neurosurg* 1985; 62:539-546.
  17. Powers WJ, Grubb RL Jr, Darriet D, et al. Cerebral blood flow and cerebral metabolic rate of oxygen requirements for cerebral function and viability in humans. *J Cereb Blood Flow Metab* 1985; 5:600-608.
  18. Winchell HS, Baldwin RM, Lin TH. Development of I-123-labeled amines for brain studies: localization of I-123 iodophenylalkyl amines in rat brain. *J Nucl Med* 1980; 21:940-946.
  19. Winchell HS, Horst WP, Braun L, et al. N-isopropyl-<sup>123</sup>I]p-iodoamphetamine: single-pass brain uptake and washout; binding to brain synaptosomes; and localization in dog and monkey brain. *J Nucl Med* 21:947-952.
  20. Kuhl DE, Barrio JR, Huang SC, et al. Quantifying local cerebral blood flow by N-isopropyl-p-<sup>123</sup>I]iodoamphetamine (IMP) tomography. *J Nucl Med* 1982; 23:196-203.
  21. Rapin JR, Le Poncin-Lafitte M, Duterte D, et al. Iodoamphetamine as a new tracer for local cerebral blood flow in the rat: comparison with isopropyl-iodoamphetamine. *J Cereb Blood Flow Metab* 1984; 4:270-274.
  22. Raynaud C, Rancurel G, Samson Y, et al. Pathophysiologic study of chronic infarcts with I-123 isopropyl iodoamphetamine (IMP): the importance of peri-infarct area. *Stroke* 1987; 18:21-29.