

Captopril Renal Scintigraphy in a Patient with Bilateral Renal Artery Stenosis

Kazuo Itoh, Masahiro Shinohara, Masaki Togashi, and Tomohiko Koyanagi

Departments of Nuclear Medicine, Radiology, and Urology, School of Medicine, Hokkaido University, Kita-15 Nishi-7, Kita-ku, Sapporo, 060, Japan.

A 41-yr-old woman with bilateral renal artery stenosis (RAS) and renovascular hypertension is presented. In this patient, the routine [^{99m}Tc]diethylenetriaminepentaacetic acid renal scintigraphy without Captopril was normal and the subsequent study with Captopril showed a marked decrease in glomerular filtration rate of the right kidney alone. Percutaneous transluminal angioplasty of the functionally affected right kidney immediately evoked new renin-dependent hypertension caused by the untreated left RAS. This patient illustrates two major points: (a) as a diagnostic tool, the sensitivity of Captopril renal scintigraphy may be compromised by an inability to detect bilateral RAS, but (b) after angioplasty, it can be useful for evaluating the treated kidney and in revealing contralateral disease that may benefit from angioplasty.

J Nucl Med 30:2042-2045, 1989

Radionuclide renal scintigraphy is routinely performed to evaluate renal blood perfusion, morphology, and renal function in various renal diseases and in hypertensive patients. Its sensitivity for disclosing renovascular hypertension (RVH) is high, but the large number of false-positive results yield a low specificity (1, 2). Captopril renal scintigraphy has proved to be a highly specific noninvasive study to predict RVH (3-5). Captopril, an anti-hypertensive drug which inhibits angiotensin-I converting enzyme (ACE), induces a striking change of glomerular filtration rate (GFR) in RVH. We encountered a patient with RVH who had bilateral renal artery stenosis (RAS), but showed only a unilateral decrease in GFR on Captopril renal scintigraphy (CRS) utilizing technetium-99M diethylenetriaminepentaacetic acid ([^{99m}Tc]DTPA) as the test agent. However, after percutaneous transluminal angioplasty (PTA) a repeat CRS revealed a functional stenosis in the contralateral kidney.

CASE REPORT

A 41-yr-old woman was admitted for surgical treatment of renovascular hypertension. Two years before admission she

presented to a physician in a local hospital and thereafter bilateral RAS was demonstrated by angiography. Various anti-hypertensive drugs were only temporarily successful in maintaining blood pressure in the normal range.

On admission, her blood pressure was 186 mmHg in systole and 110 mmHg in diastole. A bruit was heard in the abdomen. Cardiomegaly (CTR = 60%) and left ventricular hypertrophy were observed. Laboratory data, including renal function, were within normal limits, except a mild elevation in the fasting blood glucose level (125 mg/dl), hypercholesteremia (235 mg/dl) and elevated urinary dopamine excretion (1106.9 µg/day).

Peripheral plasma renin activity by Captopril challenge test was increased from 2.98 ng/ml/hr at baseline to 7.45 ng/ml/hr at 60 min. The response rate was equivocal for renovascular hypertension (6). Blood sampling from the renal vein was also carried out for the measurement of renin release after loading Captopril (25 mg). Responsibility of RAS for RVH was not clearly established by venous sampling method. Those results are summarized in Table 1. Angiography again demonstrated bilateral RAS (Fig. 1) with severe ring-like stenosis (90-95%) on the right and a mild stenosis (60-70%) of a beaded appearance on the left, consistent with fibromuscular dysplasia. No significant progression of the vascular stenosis had been noted as compared to the previous angiography 1 yr before.

Captopril renal scintigraphy was employed before and after transluminal angioplasty to assess response to treatment. This study entailed an intravenous bolus injection of 370 MBq of [^{99m}Tc]DTPA and gamma camera imaging. Serial 1-sec interval images were stored in the computer for the initial 1 min, followed by 10-sec images for additional 19 min. The 2-3 min image was used to quantitate the absolute and relative renal

Received Mar. 13, 1989; revision accepted July 18, 1989.

For reprints contact: Kazuo Itoh, MD, Dept. of Nuclear Medicine, School of Medicine, Hokkaido University, Kita-15 Nishi-7, Kita-ku, Sapporo, 060 Japan.

TABLE 1
Results of Venous Renin and Aldosterone by Captopril Test

	PRA [‡]		Aldosterone [†]	
	Peripheral plasma activity before and after PTA			
	Before	After	Before	After
Baseline	2.98	1.93	227.9	201.8
Loading 30'	5.71	8.42	170.6	128.5
60'	7.46	8.76	122.7	100.3

	Renal vein activity before PTA			
	Rt	Lt	Rt	Lt
	Baseline	4.72	1.35	210.4
Loading	4.26	4.51	74.4	67.8

Captopril test: P.O. 25 mg of Captopril
Normal range: 0.5–2.0 ng/ml/hr.
[†]Less than 130 pg/ml

uptakes, as reported previously (7). Glomerular function was estimated by the regression equation between DTPA uptake and creatinine clearance (8). This was followed to a similar renogram, but the patient was premedicated with 25 mg oral Captopril 1 hr before the [^{99m}Tc]DTPA injection. The patient was also hydrated with 300 ml of water 30 min before the study (4).

The baseline study without Captopril (RS-1 in Fig. 2 and Fig. 3) was normal: GFR was estimated to be 40 ml/min on the right and 41 ml/min on the left. After 25 mg of Captopril (RS-2 in Fig. 2 and Fig. 3), only the GFR on the right showed a striking drop from 40 ml/min to 27 ml/min. In contrast, the left kidney showed no change. Captopril scintigraphy (RS-3 in Fig. 2) was also performed 1 wk after the daily adminis-

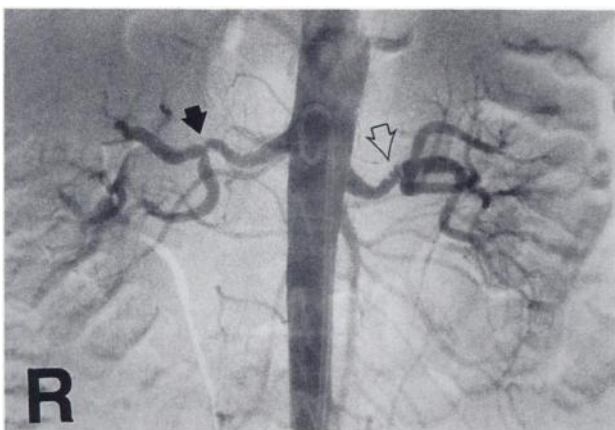


FIGURE 1
Contrast angiogram. Both renal arteries are stenosed in the main branch. Degree of the stenosis is more severe in the right renal artery (closed arrow) than in the left one (open arrow).

tration of 37.5 mg of Captopril, and the unilateral decrease in right renal function persisted but the depression was less than the single-dose response. As a result of the data obtained it was elected to perform transluminal angioplasty of the right renal artery only which promptly induced a hypotension of short duration. Her blood pressure again rose to 210/130 mmHg ~ 24 hr after angioplasty. While the postangioplastic Captopril (RS-4 in Fig. 2) showed no decrease in GFR in the reconstructed right kidney, implying a successful angioplasty, the untreated left kidney demonstrated a marked decrease in GFR. Angioplasty of the left renal artery was then performed and this was followed by an immediate drop in blood pressure. She was maintained without antihypertensive drugs and the day before discharge the Captopril renogram (RS-5 in Fig. 2) showed equal renal function. Captopril test after the treatment showed higher response rate of PRA than before the treatment (Table 1), but intravenous digital subtraction angiography before discharge demonstrated no evidence of residual stenosis in either artery. In all scintigraphic examinations, parenchymal uptake determination were more sensitive than blood flow evaluation in detecting functional stenosis.

DISCUSSION

ACE inhibitors in experimental models of unilateral RAS demonstrate opposite effects on the renal function of the two kidneys; decreased function to the side of arterial stenosis and increased function on the contralateral normal kidney (9, 10). In clinical application, asymmetric response to Captopril in hypertensive patients is widely recognized as a specific finding indicative of renovascular hypertension with functional renin-angiotensin-aldosterone dependency. With bilateral RAS, however, the detection of functional stenosis may be more complicated for at least two reasons (11). First, the exaggerated degree of asymmetry of renal function in response to Captopril may not occur since both kidneys behave in the "clipped" fashion that is observed in experimental models of two kidneys, one clip kidney. Second, a pre-existing renal insufficiency secondary to advanced RVH may be capable of producing a change in function in response to Captopril that is sufficiently large to be disclosed by [^{99m}Tc]DTPA renography. The case presented in this report suggests the possibility of a unilateral functional predominance of renin-dependency in the challenge of Captopril in RVH with bilateral renal artery stenosis. Some factors such as a severity of bilateral RAS or insufficient dose of Captopril to evoke bilateral response may be related to the unilateral response in our case, although the precise mechanism is not known.

Transluminal angioplasty of the functionally responsive kidney alone did not give permanent relief from hypertension in the case presented in this report. This underscores the necessity of postangioplasty Captopril renography to assess the efficacy of treatment and the status of the untreated side.

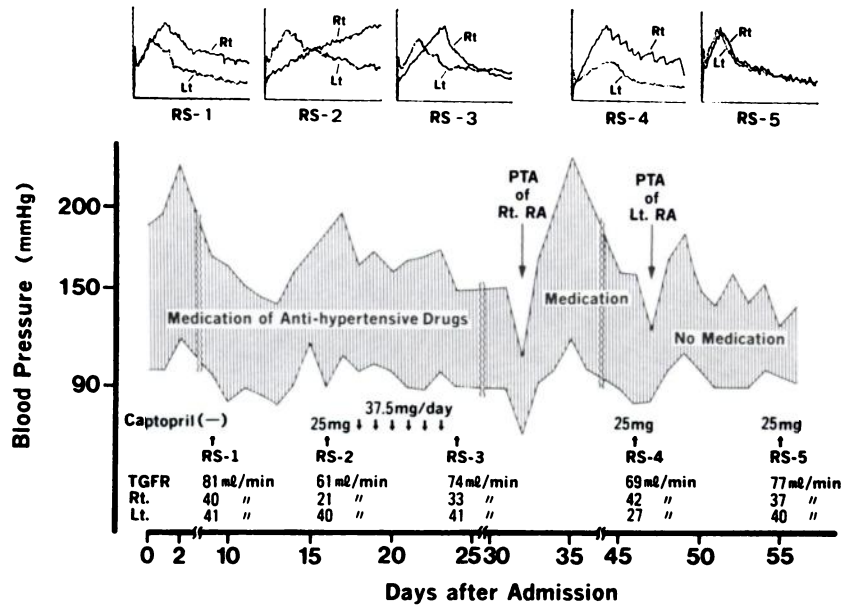


FIGURE 2
Diagram of clinical course before and after transluminal percutaneous angioplasty (PTA).

ACKNOWLEDGMENT

We greatly thank Dr. Leonard Rosenthal, of the Montreal General Hospital, for his helpful comments.

REFERENCES

1. Maxwell M. Cooperative study of renovascular hypertension: current status. *Kidney Int* 1975; 8(suppl):153-

160.
2. Harvey RJ, Krumlovsky F, delGreco F, et al. Screening for renovascular hypertension. Is renal digital-subtraction angiography the preferred noninvasive test? *JAMA* 1985; 254:388-393.
3. Majd M, Potter BM, Guzzetta PC, et al. Effect of captopril on efficacy of renal scintigraphy in detection of renal artery stenosis [Abstract] *J Nucl Med* 1983; 24:P23.

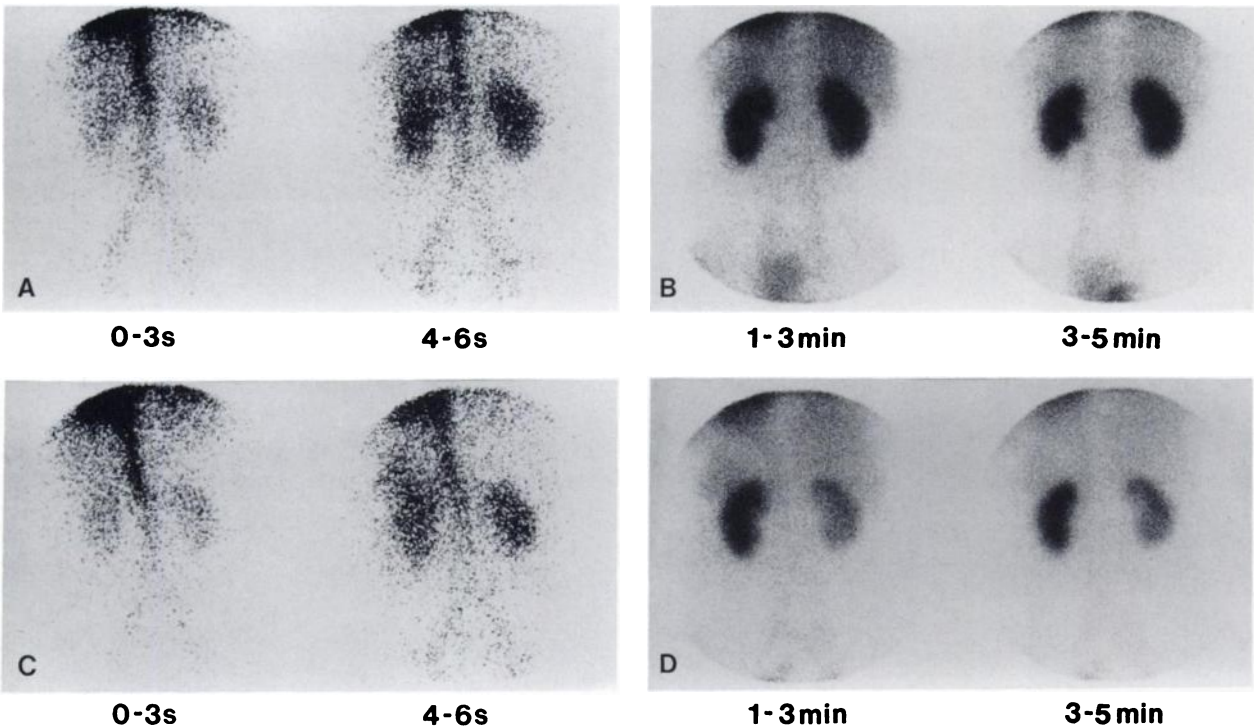


FIGURE 3
Pre-angioplastic renal scintigraphy. Baseline study (A and B) shows no disparity in blood perfusion images (A) and early parenchymal and excretory images (B). Captopril renal scintigram (C and D) shows striking diminution in parenchymal uptake on the right (D), which is strongly suggestive of reduced glomerular filtration rate. No significant difference is noted in blood perfusion (C).

4. Geyskes GG, Oei HY, Puylaert CBAJ, et al. Renovascular hypertension identified by captopril-induced changes in the renogram. *Hypertension* 1987; 9:451-458.
5. Sfakianakis GN, Bourgoignie JJ, Jaffe D, et al. Single-dose captopril scintigraphy in the diagnosis of renovascular hypertension. *J Nucl Med* 1987; 28:1383-1392.
6. Lyons DF, Streck WF, Kem DC, et al. Captopril stimulation of differential renins in renovascular hypertension. *Hypertension* 1983; 5:615-622.
7. Gates GF: Glomerular filtration rate: estimation from fractional renal accumulation of ^{99m}Tc-DTPA (standard). *Am J Roentgenol* 1982; 138:565-570.
8. Itoh K, Arakawa M. Re-estimation of renal function with ^{99m}Tc-DTPA by the Gates method. *Kakuigaku* 1987; 24:389-396.
9. Hall JE, Guyton AC, Jackson TE, et al. Control of glomerular filtration rate by renin-angiotension system. *Am J Physiol* 1977; 233:F366-F372.
10. Nally JV, Clarke HS, Gupta BK, et al. Captopril renography in two-kidney and one-kidney Goldblatt hypertension. *J Nucl Med* 1987; 28:1171-1179.
11. Nally JV. Renal scintigraphy in the evaluation of renovascular hypertension: a note of optimism yet caution [Editorial]. *J Nucl Med* 1987; 28:1501-1505.