
Clinical Use of Technetium-99m HM-PAO for Determination of Brain Death

Robert H. Reid, Karen Y. Gulenchyn, and James R. Ballinger

Division of Nuclear Medicine, Ottawa Civic Hospital and Children's Hospital of Eastern Ontario, and Department of Radiology, School of Medicine, University of Ottawa, Ottawa, Ontario, Canada

We report our clinical experience with the use of [^{99m}Tc]hexamethyl propyleneamine oxime (HM-PAO) in establishing a diagnosis of brain death in 11 patients following trauma to the head and four patients who suffered atraumatic injuries. In 9/15 studies there was no intracranial flow present and brain death was then confirmed by standard criteria. Of the remaining 6/15 studies which showed evidence of cerebral perfusion, 3/6 patients underwent a subsequent HM-PAO study which showed cessation of perfusion. One additional patient died of pneumonia and two patients survived. Thus, in all cases where there was no flow present the diagnosis of brain death was later confirmed whereas three patients clinically thought to be brain dead showed significant perfusion and survived the cerebral trauma. HM-PAO may be useful in determination of brain death because it provides unequivocal results, can be performed by planar imaging at the bedside, and does not require withdrawal of medical therapy, thus allowing a diagnosis to be established more rapidly.

J Nucl Med 30:1621-1626, 1989

Dynamic radionuclide cerebral angiography has been the nuclear medicine technique used for over a decade to aid in the diagnosis of brain death (1). However, these studies which use an intravascular tracer such as technetium-99m (^{99m}Tc) pertechnetate or [^{99m}Tc]diethylenetriaminepentaacetic acid (DTPA) are often difficult to interpret if activity is detected in the sagittal sinus despite the absence of intracranial arterial flow. The significance of activity in the sagittal sinus is controversial, although a retrospective study by Lee et al. concluded that such activity is not clinically significant and does not contradict a diagnosis of brain death (2). Static imaging with a cerebral perfusion agent would also avoid the theoretical technical disadvantages associated with dynamic flow imaging.

Technetium-99m hexamethyl propyleneamine oxime (HM-PAO, "Cerotec", Amersham Canada Ltd) is a lipophilic radiopharmaceutical which crosses the intact blood-brain barrier and is trapped in the brain in proportion to regional perfusion (3). Roine et al. reported one case in which planar and single photon emission computed tomographic (SPECT) imaging

with [^{99m}Tc]HM-PAO was used to confirm a diagnosis of brain death (4). Schober et al. evaluated [^{99m}Tc]HM-PAO and iodine-123 N-isopropyl-*p*-iodoamphetamine ([¹²³I]IMP) for determination of brain death in eight and four children, respectively, with planar imaging (5), and found these agents to offer a rapid, safe, and specific bedside test which does not suffer interference from barbiturates. This evaluation has recently been extended to include a further five children (6).

We report our clinical experience with this technique in 15 patients. In addition to confirming the results of previous studies, we report the finding of relatively intact perfusion in patients thought to be clinically brain dead.

METHODS

Fifteen patients with clinical evidence of brain death have been studied with this technique. Ten patients had suffered cerebral trauma due to motor vehicle accidents (MVA) or assault. One patient struck his head in a swimming pool and was resuscitated. Four patients suffered atraumatic injuries secondary to neoplasm or cardiopulmonary arrest.

Technetium-99m HM-PAO was prepared by addition of [^{99m}Tc]pertechnetate to a freeze-dried kit according to the manufacturer's directions (7). Radiochemical purity was 82-92% as determined either by the recommended three-system chromatographic technique (7) or by a rapid extraction tech-

Received Dec. 12, 1988; revision accepted June 12, 1989.

For reprints contact: Robert H. Reid, MD, Div. of Nuclear Medicine, Ottawa Civic Hospital, 1053 Carling Ave., Ottawa, Ontario, Canada, K1Y 4E9.

TABLE 1
Clinical Data and Results*

Case no.	Mode of injury	Clinical status	ICP	CT	EEG	HM-PAO	Outcome
1	Assault	Unconscious; unresponsive; nonreactive pupils	40	R hemisphere edema; 2 cm L midline shift; R frontal hematoma	N/A	T - R frontal defect; generalized decrease in R hemisphere	R frontal lobotomy; recovery slow; conscious but residual motor and intellectual impairment
2	Assault	Unconscious; unresponsive	45	R frontal contusion/subdural; diffuse edema	N/A	T - R frontal & L posterior parietal defects; CCD	Recovery very slow; vegetative state; unresponsive
3	MVA	Unconscious; unresponsive	43	Contusions; small subdural; 1 cm midline shift	Diffusely abnormal	P - L frontal & parietal defects	Died 5 days later of H influenza pneumonia
4	MVA	Fixed pupils; GCS 3; abrasions of scalp; multiple fractures	N/A	Diffuse edema; subarachnoid blood	Isoelectric	P - no flow; scalp activity corresponds to contusions	Brain death
5	MVA	Decerebrate; hypotensive	150	Diffuse edema	Isoelectric	P - no flow	Brain death
6	MVA	Decerebrate	75-90	Small subdural; R midline shift; diffuse edema	Isoelectric	1) P - cerebellar flow only	Brain death
7	MVA	GCS 3	90	N/A	Isoelectric	2) - no flow	Brain death
8	MVA	Decerebrate; GCS 3	90	Multiple contusions; TTH	Isoelectric	P - no flow	Brain death
9	Fall	Decerebrate; GCS 3; gag +; corneal +	N/A	L subdural; TTH; subarachnoid bleeding	Diffusely abnormal	P - no flow	Brain death
10	MVA	Decerebrate	N/A	Multiple hemorrhages; TTH	Isoelectric	P - no flow	Brain death
11	Struck head in swimming pool	Cardiopulmonary arrest; unresponsive following resuscitation	N/A	N/A	Isoelectric	P - no flow	Brain death
12	Aspiration in quadriplegic patient	Cardiopulmonary arrest; fixed & dilated pupils	N/A	N/A	Isoelectric	P - no flow	Brain death

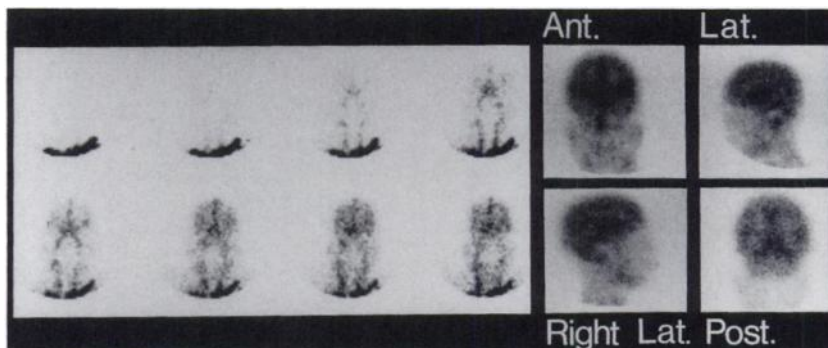
(continued)

TABLE 1 (continued)
Clinical Data and Results*

Case no.	Mode of injury	Clinical status	ICP	CT	EEG	HM-PAO	Outcome
13	Posterior fossa tumor	Acute herniation; cardiac arrest;	40	1) Grade 3 astrocytoma	1) Dif- fusely abnor- mal	1) T - defect R post cortex & cerebellum; global increase in activity; ? luxury perfusion	
			60	2) Diffuse edema; loss of gray/white differentiation	2) Dif- fusely abnor- mal	2) T - loss of corti- cal differentiation	
			100		3) Iso- electric	3) P - no flow	Brain death
14	Pineal tumor	Acute postoperative her- niation of brainstem	6	Diffuse edema	Isoelectric	1) P - flow evident	Brain death
15	Blockage of V-P shunt	Secondary herniation of brainstem	N/A	Ventricles return to normal size after draining of shunt	Isoelectric	2) P - no flow P - no flow	Brain death

* Abbreviations: T: tomographic; P: planar; MVA: motor vehicle accident; ICP: intracranial pressure; CCD: crossed cerebellar diaschisis; GCS: Glasgow coma scale; and TTH: transtentorial herniation.

FIGURE 1
Normal flow study and planar views.
Differentiation of cortical gray and white matter is evident.



nique validated in this laboratory (8). Because of its in vitro instability, [^{99m}Tc]HM-PAO was injected within 30 min of reconstitution.

The adult dose of 20 mCi (740 MBq) was scaled down by body surface area for pediatric patients, with a minimum dose of 5 mCi (185 MBq). An anterior flow study (24 frames at 2 sec/frame) was performed with a gamma camera following bolus injection of [^{99m}Tc]HM-PAO. With unstable patients only planar imaging was performed in multiple projections immediately following the flow study. However, if the flow study or initial planar images suggested intracranial perfusion and if the patient's condition permitted transfer to the SPECT pallet, tomographic imaging was also performed using a rotating gamma camera with a high-resolution parallel-hole collimator. Data acquired in 64 projections of 20–30 sec each were smoothed with a prefilter, then reconstructed using a ramp Hanning filter into a 64×64 or 128×128 matrix.

The results of [^{99m}Tc]HM-PAO imaging were compared with other available data: clinical status, electroencephalography (EEG), x-ray computed tomography (CT), measures of

intracranial pressure (ICP), and standard clinical criteria for diagnosis of brain death (9).

RESULTS

The clinical data and results are presented in Table 1.

Dynamic and planar imaging of the normal distribution of [^{99m}Tc]HM-PAO are shown in Figure 1. Activity is much higher in the brain than in surrounding soft tissue and intravascular activity is not apparent. Within the brain, differentiation between gray and white matter is evident.

In the initial HM-PAO study in each of the 15 patients, nine studies showed no intracranial activity, one showed cerebellar perfusion only, and five showed significant cerebral perfusion.

The nine cases in which no intracranial activity was detected on the initial flow study or equilibrium images suggested a diagnosis of brain death. In all of these cases, barbiturate and muscle-relaxant therapy was then withdrawn and the diagnosis of brain death was confirmed by standard criteria (9). One of these patients (case 4, Fig. 2) showed superficial activity which in multiple views was confined to the scalp and represented contusions.

One patient (case 6, Fig. 3) showed a lack of supra-

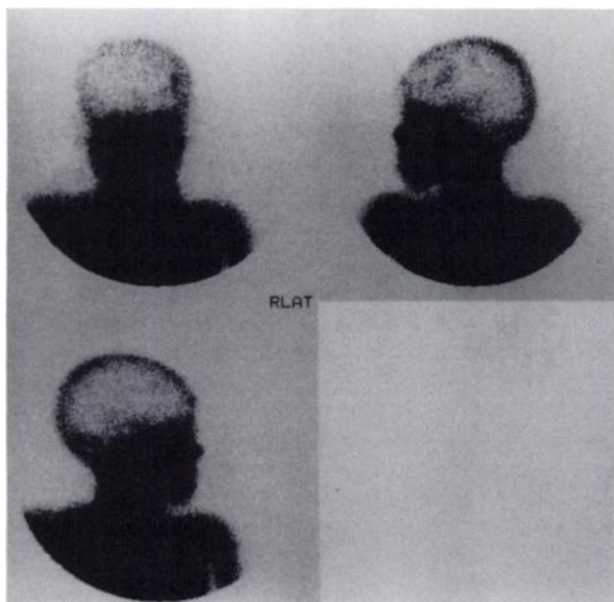


FIGURE 2
Case 4: Motor vehicle accident. HM-PAO scan shows lack of intracranial flow but superficial activity which corresponds to scalp contusions. In a pertechnetate flow study this could have been mistaken for evidence of perfusion.

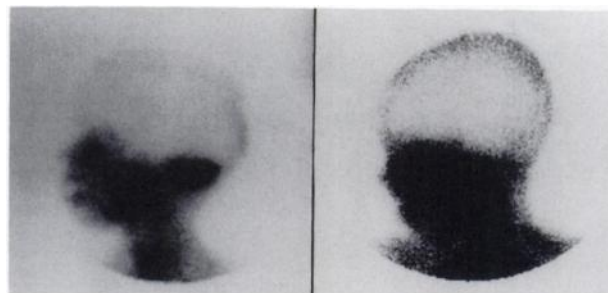

FIGURE 3
Case 6: Motor vehicle accident. A: Initial HM-PAO scan shows lack of supratentorial activity but flow persists to cerebellum. Patient was still breathing spontaneously. B: Follow-up HM-PAO study 24 hr later when patient required mechanical ventilation shows complete lack of intracranial flow.

tentorial flow but cerebellar perfusion was preserved. The patient was still breathing spontaneously. Twenty-four hours later the patient required mechanical ventilation and a repeat HM-PAO scan showed a complete lack of intracranial perfusion.

Of the five patients (Table 1, cases 1, 2, 3, 13, and 14) who showed significant supratentorial perfusion on the initial HM-PAO scan, two patients survived, 1 died of pneumonia, and two showed a lack of cerebral perfusion on repeat HM-PAO studies. The first three patients demonstrated reduced HM-PAO uptake in areas of traumatic injury evident on CT. The latter two patients had both suffered atraumatic injuries related to neoplasm. In one of these (case 13, Fig. 4), the initial HM-PAO scan showed a defect at the site of the tumor in the right posterior cortex and cerebellum, but increased activity in the remainder of the cerebral cortex. The cortex/cerebellum ratio was 1.20 (normal range: 0.85-0.95). The follow-up scan showed a loss of gray/white matter differentiation but the cortex/cerebellum ratio remained elevated at 1.25 despite raised ICP. After a sudden further increase in ICP 2 days later, an HM-

PAO scan showed a total lack of intracranial perfusion and brain death was then confirmed by standard criteria.

DISCUSSION

Brain death may be declared when all functions of the entire brain, including the brain stem, have irreversibly ceased (9). Brain stem function is usually assessed by clinical examination while higher cerebral function is assessed by EEG. However, the EEG may be falsely silent due to drug intoxication, hypothermia, shock or technical artifacts. Furthermore, medical therapy (barbiturate coma and muscle relaxants) must be withdrawn for a period of 24 hr before a diagnosis of brain death can be established. Therefore, confirmatory tests of brain death are required, particularly when organ donation is being considered (1,9-11).

Several radiological techniques have been used for assessment of brain death, but each has its limitations. Contrast angiography is invasive, not available around the clock, exposes potential donor organs to toxic con-

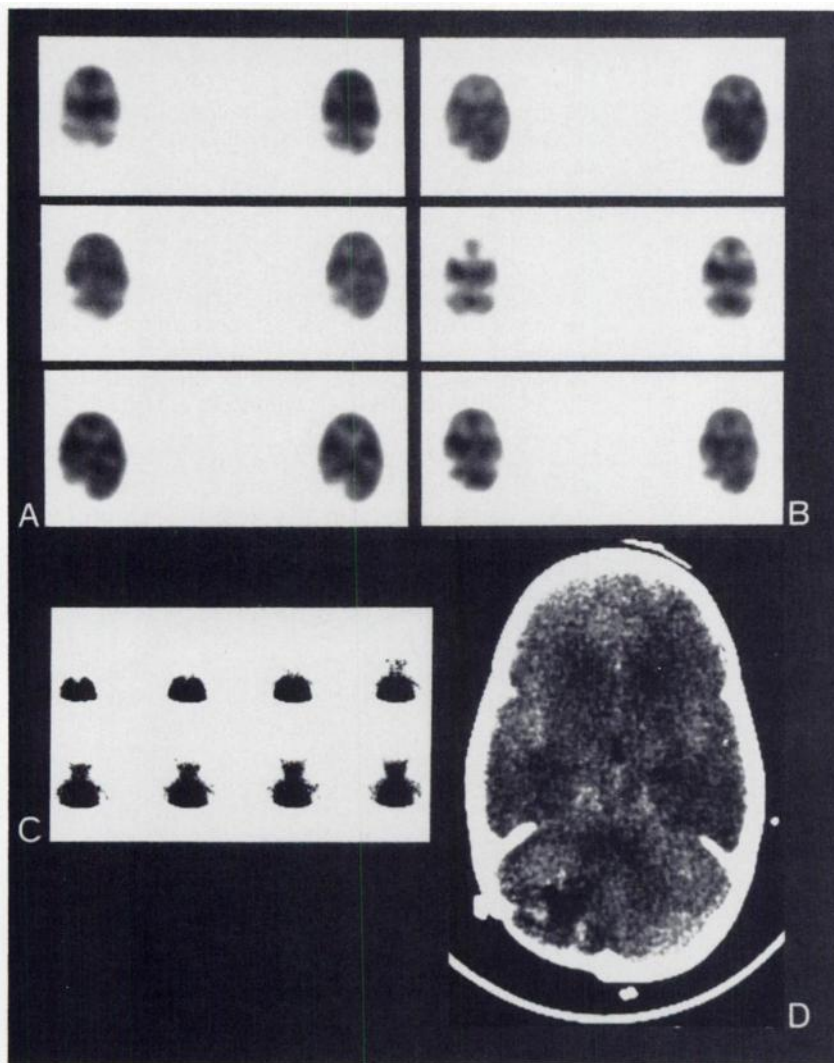


FIGURE 4

Case 13: Posterior fossa tumor. A: Initial HM-PAO scan shows defect in right cerebellum and posterior cortex due to tumor and related edema. Activity in remainder of cortex is increased. B: Follow-up HM-PAO scan after further increase in ICP shows loss of cortical gray/white matter differentiation but cortical perfusion remains high. C: Two days later there is no evidence of intracranial flow. D: CT scan (same day as panel B) shows loss of cortical gray/white matter differentiation and global edema.

trast media, and requires transportation of the patient to the radiology department (10,11). Xenon-enhanced CT is not routinely available, requires transportation of the patient, and suffers artifacts due to bony structures (10). The xenon-133 cerebral perfusion study is not routinely available, requires transportation of the patient, does not visualize deep structures, and suffers artifacts due to increased extracranial flow (10).

Radionuclide cerebral angiography is widely available, but requires rapid acquisition of dynamic images in technically challenging situations, cannot image flow in the posterior fossa and interpretation may be difficult or equivocal. In a recent series, four of 14 studies were equivocal due to faint venous activity in the sagittal sinus; all four patients died within 2 days (11). A retrospective study by Lee et al. (2) concluded that activity in the sagittal sinus does not contradict a diagnosis of brain death.

Brain death studies with lipophilic radiopharmaceuticals avoid many of the limitations of other techniques. The utility of [^{99m}Tc]HM-PAO has been demonstrated previously (4-6). Although the utility of [¹²³I]IMP has also been demonstrated (5,6), the half-life and means of production of ¹²³I present logistical problems which make only the ^{99m}Tc agents practical.

The standard criteria for determination of brain death require withdrawal of medical therapy (barbiturate coma and muscle relaxants) for 24 hr (9). The HM-PAO test can be performed without withdrawal of medical therapy, allowing earlier determination of brain death which is particularly important in organ donation (4-6). Although anesthetics can reduce cerebral perfusion, they do not abolish it and thus do not interfere with this test (4-6,12).

Although generally HM-PAO imaging is best performed with SPECT (3,7), planar flow and equilibrium images are sufficient to establish a diagnosis of brain death. This allows the test to be performed at the bedside with a portable gamma camera in the intensive care unit.

In all of our patients with no evidence of intracranial perfusion, the diagnosis of brain death was confirmed by standard criteria. Conversely, three patients who were clinically thought to be brain dead showed relatively normal perfusion despite severe trauma to the head and raised ICP. Two of these patients survived; the third died of pneumonia.

Case 13 (Fig. 4) was particularly interesting. The initial HM-PAO scan showed a deficit at the site of the tumor but the remainder of the cortex showed increased perfusion. The same was seen on a second study, but a third study showed a complete lack of intracranial perfusion. We interpret the increased cortical perfusion to represent global luxury perfusion related to loss of autonomic control of perfusion.

In Case 4 (Fig. 2), superficial activity was evident in

the scalp as a result of contusions. In a traditional radionuclide angiographic study with an intravascular tracer, this might have been misinterpreted as evidence of perfusion. Extracranial activity can be minimized by application of a tourniquet but this is not always possible due to the patient's injuries.

In our experience, the patients with traumatic injury show a dramatic loss of perfusion while patients with atraumatic injury show a more gradual change in perfusion patterns.

In conclusion, HM-PAO imaging is as simple and convenient as traditional radionuclide angiography but provides more clear-cut evidence for diagnosis of brain death. The flow study is equivalent to that obtained with intravascular agents. Moreover, when perfusion is present, the HM-PAO image allows assessment of the extent of injury which is often greater than that evident on CT. The main limitation is technical constraint on reconstitution of the kit.

REFERENCES

1. Pjura GA, Kim EE. Radionuclide evaluation of brain death. In: Freeman LM, Weissmann HS, eds. *Nuclear Medicine Annual 1987*. New York: Raven Press, 1987:269-293.
2. Lee VW, Hauck RM, Morrison MC, Peng TT, Fischer E, Carter A. Scintigraphic evaluation of brain death: significance of sagittal sinus visualization. *J Nucl Med* 1987; 28:1279-1283.
3. Neirinckx RD, Canning LR, Piper IM, et al. Technetium-99m d,l-HM-PAO: a new radiopharmaceutical for SPECT imaging of regional cerebral blood perfusion. *J Nucl Med* 1987; 28:191-202.
4. Roine RO, Launes J, Lindroth L, Nikkinen P. ^{99m}Tc-hexamethylpropyleneamine oxime scans to confirm brain death. *Lancet* 1986; 2:1223-1224.
5. Schober O, Galaske R, Heyer R. Determination of brain death with ¹²³I-IMP and ^{99m}Tc-HM-PAO. *Neurosurg Rev* 1987; 10:19-22.
6. Galaske RG, Schober O, Heyer R. ^{99m}Tc-HM-PAO and ¹²³I-iodoamphetamine cerebral scintigraphy: a new, noninvasive method in determination of brain death in children. *Eur J Nucl Med* 1988; 14:446-452.
7. Ceretec package insert. Amersham Canada Ltd. 1987.
8. Ballinger JR, Reid RH, Gulenchyn KY. Radiochemical purity of [^{99m}Tc]HM-PAO [Letter]. *J Nucl Med* 1988; 29:572-573.
9. President's commission for the study of ethical problems in medicine and biomedical and behavioral research. Guidelines for the determination of death: report of the medical consultants on the diagnosis of death. *JAMA* 1981; 246:2184-2186.
10. Darby JM, Yonas H, Gur D, Latchaw RE. Xenon-enhanced computed tomography in brain death. *Arch Neurol* 1987; 44:551-554.
11. Patel YP, Gupta SM, Baston R, Herrera NE. Brain death: confirmation by radionuclide cerebral angiography. *Clin Nucl Med* 1988; 13:438-442.
12. Costa DC, Lui D, Ell PJ. Tc-99m-HMPAO uptake in rat brain: sensitivity to physiological and pharmacological intervention "in vivo" [Abstract]. *Nucl Med* 1987; 26:146-147.