# The Use of Radionuclide Cisternography in the Diagnosis of Pleural Cerebrospinal Fluid Fistulae

Arthur Z. Krasnow, B. David Collier, Ali T. Isitman, Robert S. Hellman, and Thomas M. Joestgen

*Department of Radiology, Nuclear Medicine Section, Medical College of Wisconsin, Milwaukee, Wisconsin*

Radionuclide cisternography (RNC) is an excellent method of studying cerebrospinal fluid (CSF) dynamics and fistulous communications. Two patients are described in which pleural cerebrospinal fluid fistulae were found by this technique. In addition, marking the area presurgically reduced operating room time in one patient. Such communications are important to locate since they can cause significant loss of CSF as well as provide a pathway for pathogens to enter the central nervous system.

**J Nucl Med 30:120–123, 1989**

Contrast myelography usually is the procedure of choice for assessing structural abnormalities in and adjacent to the subarachnoid space. However, functional aberration in relation to cerebrospinal fluid (CSF) dynamics, including fistulous communications, may often be better assessed by radionuclide cisternography (RNC). Since the introduction of this technique by De Chiro in 1964 (*1*), reports of CSF fistulae to the nasal passages (*2–4*), the skin (*5*), surgical wounds (*2*), and various intracavitary spaces (*6–8*) have been described. RNC may be very helpful in such clinical situations by demonstrating and accurately localizing the site of the fistula.

We are reporting two patients in which RNC serendipitously discovered a CSF pleural fistula. We were then able to presurgically mark the site of the fistula in one patient which was extremely helpful prior to neurosurgical intervention.

## CASE 1

A 22-yr-old male was admitted for evaluation of upper extremity weakness and numbness. Two years previously he had become paraplegic in his lower extremities following a motorcycle accident. At that time he had sustained multiple fractures to several of his upper thoracic vertebrae requiring extensive surgery. One year later he developed a syringomyelocele in the upper thoracic region requiring further surgery. He did well until 1 mo prior to this admission when a magnetic resonance scan showed that the syringomyelocele had recurred. Cisternography was ordered to assess whether communicating hydrocephalus with increased CSF production was contributing to the persistence of this cavity. Five hundred microcuries of indium-111 diethylenetriaminepentaacetic acid ([$^{111}$In]DTPA) was injected intrathecally into the lumbar subarachnoid space and images in multiple projections were obtained at 6 and 24 hr. A posterior head, neck, and chest image at 6 hr revealed a large round area of tracer accumulation just to the right of the spinal canal which appears to be in the upper chest (Fig. 1A).

An image obtained in the anterior projection over the chest at 24 hr, while the patient was supine (Fig. 1B), showed activity outlining the right pleural cavity. The presence of a right pleural effusion was confirmed by the layering of fluid in the right lateral decubitus chest radiograph (Fig. 2A). A nuclear image taken at 24 hr in the posterior projection while the patient was in the right lateral decubitus position (Fig. 2B) reveals gross communication between the upper thoracic pocket of activity and the pleural space, thus mapping the fistulous tract. Repeat examination 2 mo later was unchanged. A chest x-ray was then performed with a marker placed in the area of abnormal tracer accumulation in order to presurgically locate the fistulous communication. At surgery a 6–8 mm midline dural tear was found in the region of T3–4, at the site of a previous interbody fusion. Postoperatively the patient has done well with only minimal reaccumulation of the pleural fluid.

Received April 14, 1988; revision accepted August 31, 1988.

For reprints contact: B. David Collier, MD, Nuclear Medicine Section, Milwaukee County Medical Complex, 8700 W. Wisconsin Ave., Milwaukee, WI 53226.

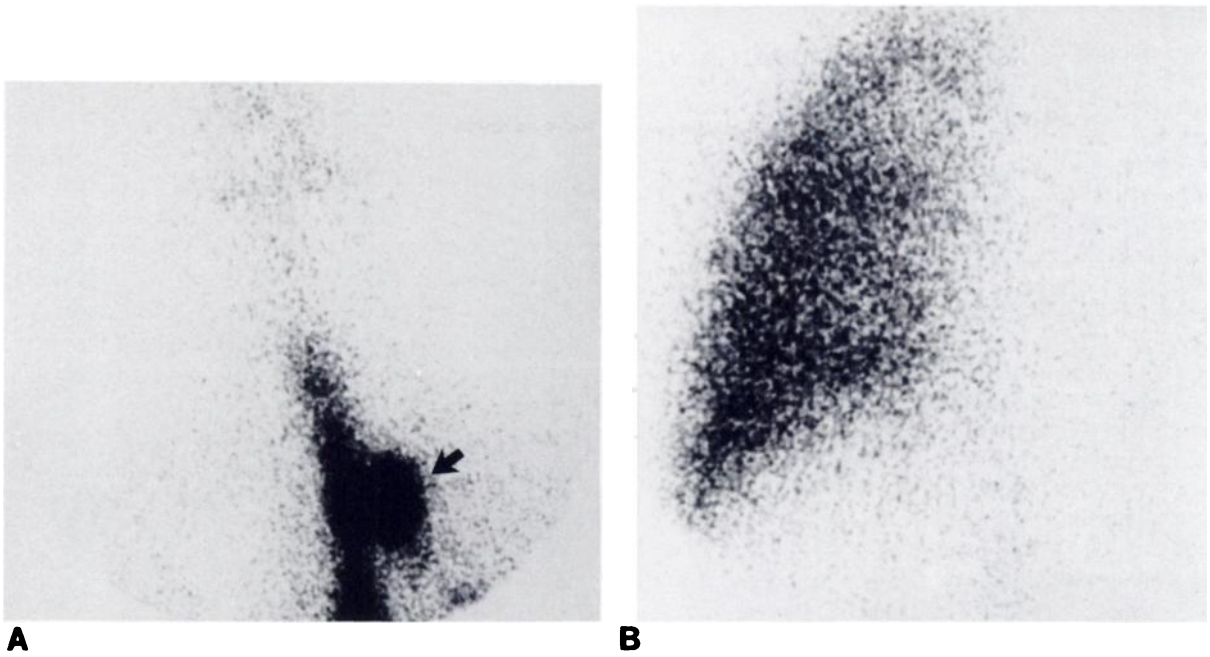


**FIGURE 1**
A: Posterior head and chest image obtained 6 hr following the intrathecal injection of [$^{111}$In]DTPA. Note the abnormal area of tracer to the right of the spine in the upper chest (arrow). B: Anterior RNC image in the supine position obtained at 24 hr showing the presence of tracer outlining the pleural cavity.

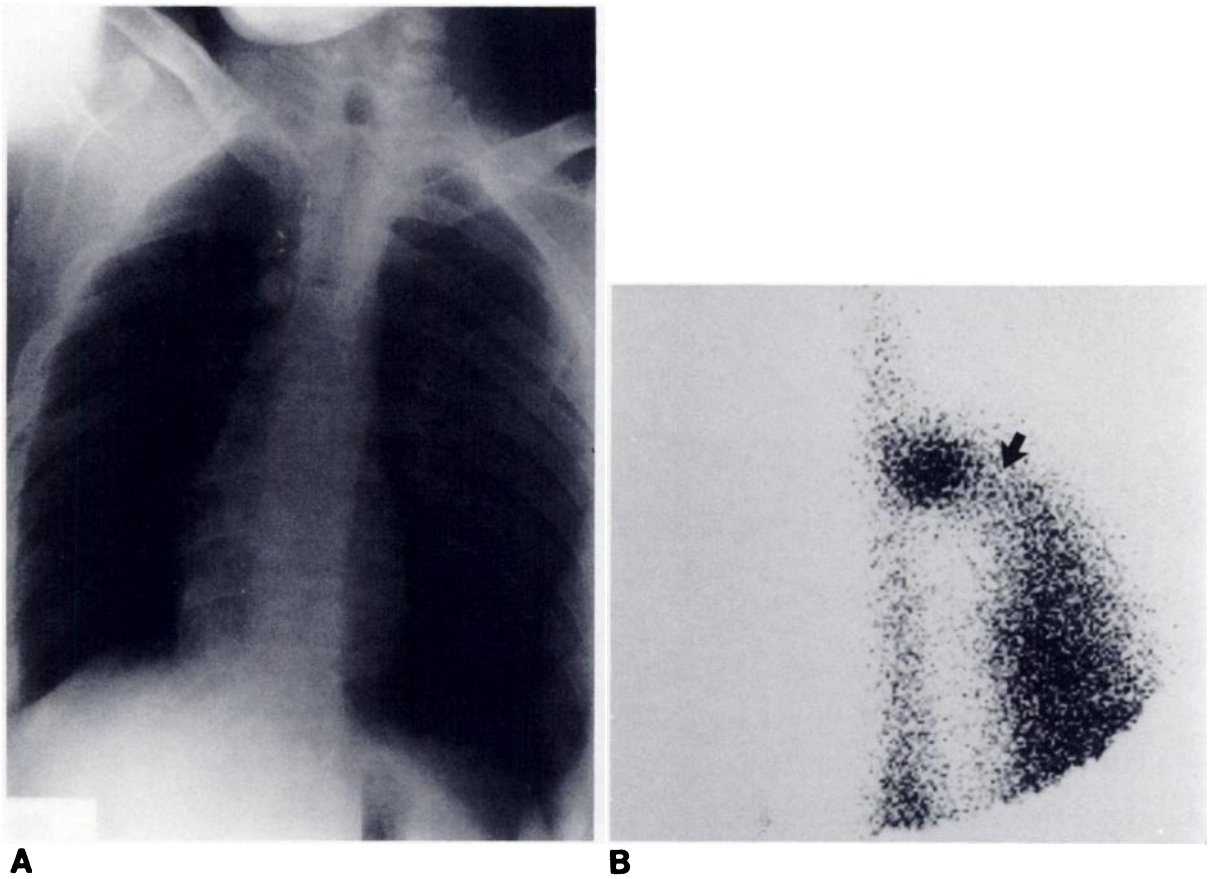


**FIGURE 2**
A: Right lateral decubitus chest x-ray showing layering of the pleural fluid. B: Corresponding right lateral decubitus [$^{111}$In]DTPA RNC image at 24 hr with visualization of the fistulous tract exiting from the subdural space (arrow).

**CASE 2**

An 18-yr-old Hispanic male suffered multiple gunshot wounds to the left upper chest and thoracic spine causing T6 paraplegia and a left pneumothorax. A chest tube was placed and a small amount of fluid was obtained over the next several days. The etiology of the pleural fluid was unknown so a radionuclide cisternogram was performed. Five hundred microcurie [$^{111}$In]DTPA was injected into the lower lumbar subarachnoid space. In a posterior supine image obtained at 24 hr, radioactivity was seen diffusely throughout the left lung field indicating that a CSF pleural fistula was present (Fig. 3). A focal area of more intense activity is seen in the midline representing the leakage site. This finding was confirmed during surgery when a dural tear at the level of the fifth thoracic vertebrae was found and repaired. Marking the fistula site in this case was not performed since the surgeons felt that the fistula would be at the known site of spinal injury. The detection and repair of this abnormality proved to be extremely important since one week later the patient developed left-sided empyema requiring surgical decortication.

## DISCUSSION

CSF fistulae have been reported to occur in many different sites. Most of these aberrant tracts develop post operatively or secondary to trauma but tumor invasion has also been reported (*2,7–9*). Occasionally patients with elevated CSF pressure spontaneously develop such fistulae in order to relieve this pressure (*10*). Nuclear techniques are well suited for visualization of such abnormalities with radiopharmaceuticals having been injected into both the cervical (*2,5,8,9,11*) and lumbar subarachnoid spaces (*2–4,7*) and even into an Ommaya shunt (*12*). Our two patients developed CSF pleural leaks secondary to trauma, one from a car accident (closed injury) and the other from a gunshot wound (open injury). We were able to provide an explanation for the cause of the pleural effusion in both instances and successfully marked the site of the fistula in one patient allowing a significant reduction in operation time.

Contrast myelography is often unable to detect fistulous CSF tracts. A CSF fistula may be so small that detectable quantities of radiographic contrast material can not pass through the opening. Also, imaging is typically performed shortly after the injection of the contrast agent which may not allow sufficient time for the material to move through the tract. RNC is a more physiological and sensitive test which is only minimally invasive. Routine delayed images are easily obtained and often extremely helpful. Since most leaks are observed in <24 hr, it is reasonable to use technetium-99m ($^{99m}$Tc) DTPA in adults instead of the routinely used [$^{111}$In]DTPA (*7*). However, if [$^{99m}$Tc]DTPA is used, it is imperative that the preparation pass rigid

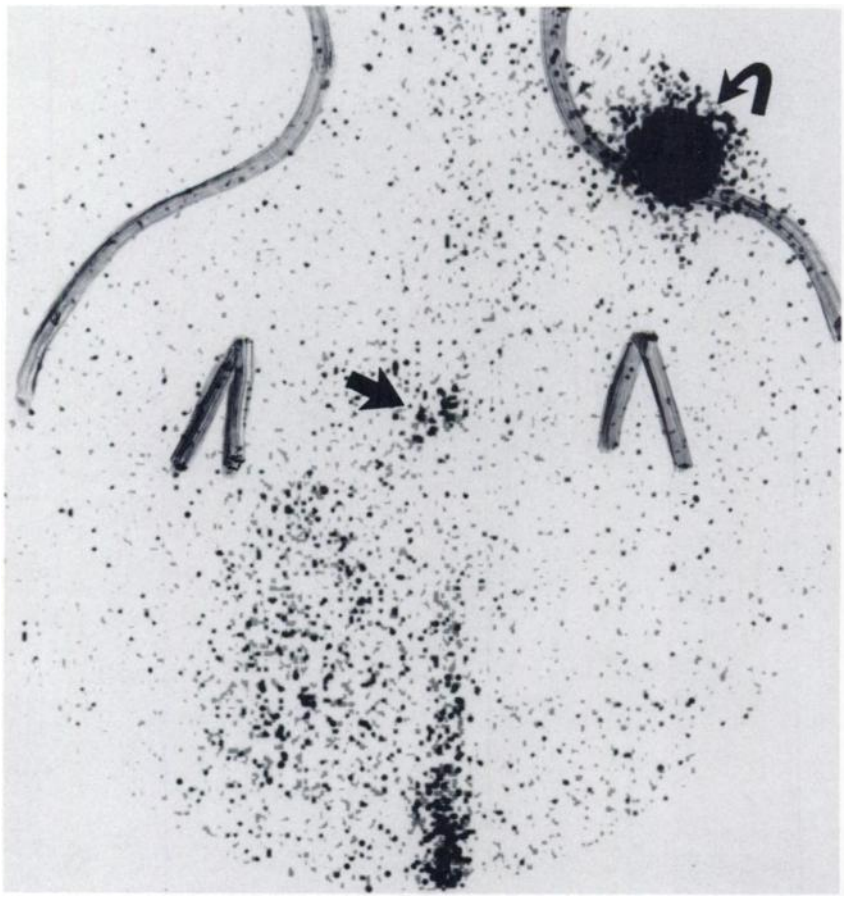

**FIGURE 3**
Posterior supine RNC image of the second patient at 24 hr revealing abnormal tracer diffusely in the left chest. A more focal accumulation of activity representing the site of the fistula is seen in the midline (straight arrow). A shoulder marker is seen in the right upper corner (curved arrow). (Note: body outline is superimposed to allow for better image interpretation)

radiopharmaceutical quality control measures, be freshly prepared, and be administered in a small volume with high specific activity. If [$^{111}$In]DTPA is used a larger dose of 1–2 mCi might prove to be beneficial because of the poorer imaging characteristics of this radionuclide and the increased target to background ratio that might occur (*9,12*).

The fistulous tract itself is often difficult to visualize by RNC. This is probably due to the small diameter of the canal and the intermittancy of fluid transit. In our two patients the site where the tract began was easily seen. A marker placed in this area with a subsequent chest x-ray in one patient provided invaluable information for the neurosurgeons who otherwise might have spent a long time searching for the defect. More detailed information was obtained by placing the patient and gamma camera in various positions. Placing the patient in a dependent position is a well known technique for improving the visualization of naspharyngeal leaks (*13*). However it may be difficult to position post traumatic patients who have an unstable spinal canal and various traction devices. Nasopharyngeal CSF leaks which are not visualized, are often only discovered by detecting radioactivity in nasally placed pledgets (*14*). Obviously a similar technique is not feasible in the pleural space. However, the counting of pleural fluid activity from an appropriately timed thoracentasis following intrathecal radionuclide administration offers an intriguing possibility. Another technique to increase visualization of CSF fistulae is the use of over pressure, although this is controversial (*15*).

Several authors have also shown that serial RNC is an excellent means of following CSF fistulae both pre and post operatively (*2,11*). Spontaneous closure of a known lesion would prevent surgery in patients who might not tolerate an operation well. In our first patient, repeat imaging after 2 mo failed to show resolution of the abnormality so elective surgery was performed. The interesting possibility of using quantitative techniques for serial comparisons to look for improvement is feasible in asymptomatic or minimally symptomatic patients.

In conclusion physiologic information obtained from RNC offers many advantages when evaluating and treating patients with insidious CSF fistulae. In addition to demonstrating the presence of a CSF leak, it may be utilized presurgically to mark the site of the leak with considerable accuracy.

## REFERENCES


1. Dichiro G. Radiographic and isotopic procedures in neurological diagnosis. *JAMA* 1964; 188:524.
2. Maeda T, Ishida H, Matsuda H, et al. The utility of radionuclide myelography and cisternography in the progress of cerebral spinal fluid leaks. *Eur J Nucl Med* 1984; 9:416–418.
3. Ashburn WL, Harbert JC, Bruice WH, et al. Cerebrospinal fluid rhenorrhea studies with gamma scintillation camera. *J Nucl Med* 1968; 9:523.
4. Front D, Penning L. Ocult spontaneous cerebrospinal fluid rhinorrhea diagnosed by isotope cisternography. *Neuroradiol* 1971; 2:167.
5. Liebeskend AL, Herz DA, Rosenthal AD, et al. Radionuclide demonstration of spinal dural leaks. *J Nucl Med* 1973; 14:356–358.
6. Goupta, SM, Frias J, Garg A, et al. Aberrant cerebrospinal fluid pathway: detection by scintigraphy. *Clin Nucl Med* 1986; 11:593–594.
7. Rosen PR, Chaudhuri TK. Radioisotope myelography in the detection of pleural-dural communication as a source of recurrent meningitis. *Clin Nucl Med* 1983; 8:28–30.
8. Hoffstetter KR, Bjelland JC, Patton DD, et al. Detection of bronchopleural-subarachnoid fistula by radionuclide myelography: case report. *J Nucl Med* 1977; 18:981–983.
9. Colletti PM, Siegel ME. Post-traumatic lumbar cerebrospinal fluid leak: detection by retrograde In-111 DTPA myeloscintigraphy. *Clin Nucl Med* 1981; 6:403–404.
10. Ommaya A. Cerebrospinal fluid rhinorrhea. *Neurol* 1965; 15:106.
11. Kadrie H, Driedger AA, McInnis W. Persistent dural cerebrospinal fluid leak shown by retrograde radionuclide myelography. Case report. *J Nucl Med* 1976; 17:797–799.
12. Silverman D, Davis WB, Harbert JC, et al. Spinal cerebrospinal fluid leak demonstrated by retrograde myeloscintigraphy. *Clin Nucl Med* 1981; 6:27–29.
13. Harbert J. Radionuclide cisternography. In: *Textbook of nuclear medicine.* Philadelphia: Lea and Febiger. 1984:111–126.
14. McKusick KA, Malmud LA, Kordela PA, et al. Radionuclide cisternography: normal values of nasal secretions of intrathecally injected In-DTPA. *J Nucl Med* 1973; 14:933.
15. Magnaes B, Solheim D. Controlled overpressure cisternography to localize cerebral spinal fluid rhinorrhea. *J Nucl Med* 1977; 18:109.