

## Nuclear Hepatology: Where Is It Heading Now?

---

**R**adiocolloid imaging of the liver remained a popular imaging test for nearly 30 years until it faced stiff competition from other imaging tests such as ultrasound, computed tomography (CT), and nuclear magnetic resonance (NMR) (1-4). A factor common to all four of these imaging modalities is that they depend upon alteration in morphology to be able to detect the presence of disease. More recently, it has been recognized that functional changes may precede morphologic alterations by weeks or months. Functional imaging, therefore, has the potential for early detection of disease, before morphologic changes have taken place.

Functional liver imaging has become more widely accepted since the introduction of  $^{99m}\text{Tc}$ -labeled iminodiacetic acids [ $^{99m}\text{Tc}$ ]IDA in 1976 (5) and has had a perceptible impact on the diagnostic work up of patients with acute cholecystitis (6). In a patient with leucocytosis, fever, and right upper quadrant pain, the nonvisualization of the gallbladder by [ $^{99m}\text{Tc}$ ]IDA scintigraphy is virtually diagnostic of acute cholecystitis (6-8). An accompanying "rim sign" around the gallbladder fossa suggests complex acute cholecystitis requiring immediate surgery (9,10). Scintigraphic features of calculous and acalculous acute cholecystitis are similar (8). The sensitivity and specificity of [ $^{99m}\text{Tc}$ ]IDA scintigraphy in 296 patients with suspected acute cholecystitis are 95.2% and 99.2%, respectively (7). Clinicians have accepted [ $^{99m}\text{Tc}$ ]IDA scintigraphy as a reliable and cost-effective diagnostic test in acute cholecystitis.

In addition to acute cholecystitis, other common hepatobiliary diseases that can be assessed with [ $^{99m}\text{Tc}$ ]IDA scintigraphy include: extrahepatic bile duct obstruction (due to stone, strictures, or malignancy), intrahepatic cholestasis (due to bacterial or viral infection, septicemia or cholestatic drugs) and alcoholic cirrhosis. Less common diseases include sclerosing cholangitis (primary or secondary) primary biliary cirrhosis, and metabolic diseases (hemachromatosis). Clinicians, on the other hand, have delayed wide acceptance of [ $^{99m}\text{Tc}$ ]IDA scintigraphy in the diagnostic workup of these groups of diseases. Why then have the clinicians who so readily accepted [ $^{99m}\text{Tc}$ ]IDA scintigraphy in the diagnosis of acute cholecystitis delayed its acceptance in the case of other hepatobiliary diseases? This editorial will review the reasons for delay and discuss the corrective measures that have been undertaken and suggest the next course of action to be taken by nuclear medicine physicians to accelerate clinicians widespread acceptance of [ $^{99m}\text{Tc}$ ]IDA scintigraphy in the assessment of all hepatobiliary diseases.

Among several reasons for delay in acceptance, four stand out clearly: (a) Late approval of superior [ $^{99m}\text{Tc}$ ]IDA agents; (b) Poor results from early studies using first generation [ $^{99m}\text{Tc}$ ]IDA agents in patients with far advanced disease who had already morphologic changes that could be detected readily with either CT or ultrasound; (c) Lack of thorough understanding of [ $^{99m}\text{Tc}$ ]IDA scintigraphic patterns in normal subjects resulting in the selection of wrong criteria for diagnosis in patients; (d) exclusion of quantitative physiologic parameters and reliance mainly on the hepatobiliary image pattern.

The availability of [ $^{99m}\text{Tc}$ ]IDA agents over the years occurred in three phases. In the first phase, dimethyl, diethyl, paraisopropyl, and parabutyl IDA agents were made available in the late 1970s under investigational new drug category. In the second phase, diisopropyl IDA was made available and approved by the FDA for routine use in 1982. In the third phase, trimethylbromo IDA was made available and approved by the FDA for routine use in 1987. The first phase agents worked well as long as the liver function was near normal. Since most patients with acute cholecystitis maintain near normal liver function, these agents provided excellent results which impressed the clinicians who readily accepted [ $^{99m}\text{Tc}$ ]IDA scintigraphy for acute cholecystitis (6).

Impressed with excellent results in acute cholecystitis, physicians extended the use of first

Received Sept. 28, 1987; revision accepted Feb. 8, 1988.

For reprints contact: G. T. Krishnamurthy, MD, Nuclear Medicine (115), VA Medical Center, P.O. Box 1034, Portland, OR 97207.

phase IDA agents to study other hepatobiliary diseases. Here they selected patients with far advanced liver disease (11,12). In two reports comprising a total of 106 patients the mean serum bilirubin was 12 mg%. Both studies excluded patients with serum bilirubin <2.5 mg%. Control subjects were not included to establish normal and variant patterns. In one study the diagnosis of biliary obstruction was excluded when the small intestine was seen by 60 min (11). In the other study the diagnosis of biliary obstruction was made when the small intestine to background ratio was less than one at 24 hr (12). No attempt was made to quantitate any other functional parameters. First generation <sup>99m</sup>Tc agents used in these two studies did not compete well for hepatic uptake in the presence of high serum bilirubin. The in vitro hepatocyte uptake of 100% in bilirubin free medium decreases to <35% in the presence of 10 mg% bilirubin (13). As could be predicted, results obtained with physiologic based scintigraphy were inferior compared to morphologic based ultrasound and CT. In 106 patients, the scintigraphic sensitivity was 41–74% compared to sensitivity of 63–77% for CT and 55–90% for ultrasound (11–12). Based on such results, review articles and editorials uncomplementary to scintigraphy were published in other journals widely read by clinicians who justifiably withheld their enthusiasm for applying [<sup>99m</sup>Tc]IDA scintigraphy in the assessment of hepatobiliary diseases other than acute cholecystitis (14,15).

### **Corrective Measures Undertaken**

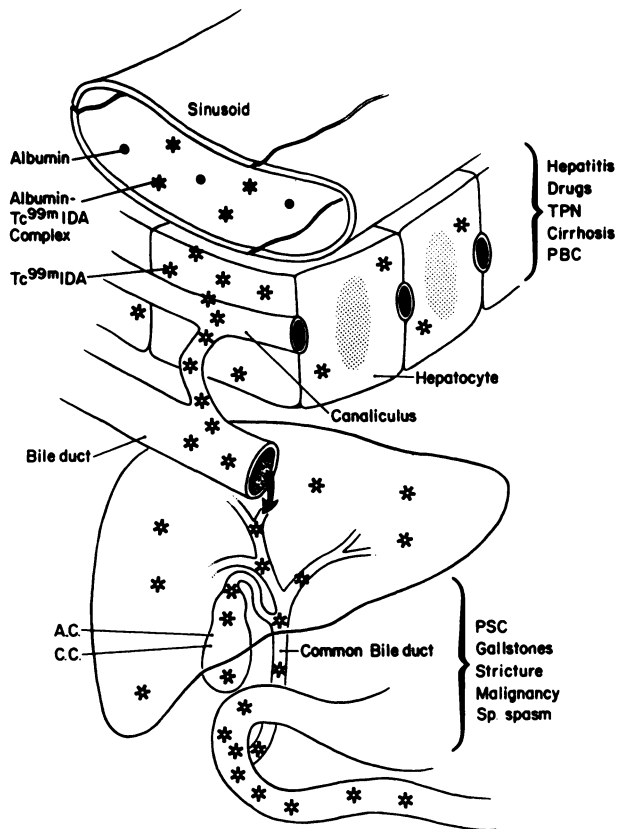
Nuclear medicine physicians accepted the challenge readily and took measures to correct the errors. Control subjects were studied to establish the normal and the variant pattern and the functional parameters were quantified by computer analysis of the data acquired simultaneously with the images. It was then realized that nonvisualization of the small intestine by 60 min was a variant pattern found in 20% of normal subjects. Also the small intestine may be seen within 60 min in 60% of patients with documented partial common bile duct (CBD) obstruction, suggesting that intestinal visualization or nonvisualization as a single parameter does not have either high sensitivity or high specificity to rule out biliary obstruction (18). These findings alerted the physicians not to rely only on intestinal appearance time as a sole sign of biliary obstruction.

### **Superior Agents**

By 1982 and, respectively, 1987 diisopropyl and tri-methylbromo IDA were approved by the FDA. About 85% of the dose of diisopropyl and 98% of trimethylbromo-IDA is taken up by the liver and rapidly secreted into bile. The high specific activity of hepatic bile result in excellent delineation of the extrahepatic biliary morphology as clear as in a contrast cholangiogram (19). Zeman et al., Kaplun et al., and Krishnamurthy et al. studied a total of 204 patients with early obstruction with the mean serum bilirubin of 1.9–5.06 mg% and showed that obstruction could be detected with [<sup>99m</sup>Tc]IDA scintigraphy with a sensitivity of 83–98% (19,21,22). Strictures or filling defects within the CBD were readily appreciated (19). Bile pooling in ducts proximal to obstruction was common and occurred even in the absence of ductal dilation. In 63% of the patients with biliary obstruction there was no dilation of ducts. Ultrasound studies in the same group of patients had a sensitivity of 36–50% indicating the superiority of scintigraphy over ultrasound in the diagnosis of early biliary obstruction (19,21,22).

### **Quantification of Hepatobiliary Function**

A unique feature of [<sup>99m</sup>Tc]IDA scintigraphy, not shared by radiocolloid imaging, CT, NMR, or ultrasound, is its ability to provide simultaneous quantitative functional information. Technetium 99m IDA is taken up by the hepatocyte by a non-sodium dependent organic anion path and secreted into bile without conjugation. Once it enters the bile canaliculi, it follows the path taken by hepatic bile and enables the study of major ducts much like in a contrast cholangiogram (Fig. 1). The hepatic extraction fraction (HEF), a measure of hepatocyte function is calculated by deconvolutional analysis of the first 30 min data points. Deconvolutional analysis treats the data as though [<sup>99m</sup>Tc]IDA was injected



**FIGURE 1**  
Schematic diagram [<sup>99m</sup>Tc]IDA transit through the hepatobiliary system and the disease categories that affects at various levels. Technetium-99m-IDA is carried to the liver loosely bound to albumin and enters the bile canaliculi without undergoing any conjugation during the transit through the hepatocyte. The diseases that affect the hepatocyte and the canaliculi are shown on the upper right and those that affect the major ducts are shown in the lower right position (AC = acute cholecystitis, CC = chronic cholecystitis, PSC = primary sclerosing cholangitis, SP = Sphincter, PBC = primary biliary cirrhosis, and TPN = total parenteral nutrition).

directly into the hepatic artery. The normal hepatic extraction fraction of 100% decreases in alcoholic cirrhosis and remains normal in early bile duct obstruction (23). Hepatic excretion  $T_{1/2}$ , on the other hand, is a measure of the rapidity of elimination of the agent from the squares fit. Normal mean biologic excretion  $T_{1/2}$  is 16 min for Mebrofenin and 18 min for DISIDA (20,23). Prolongation of excretion  $T_{1/2}$  is a measure of impedance to bile formation or flow. Measurement of HEF, thus, aids in differentiating primarily hepatocyte disease (alcoholic cirrhosis) from primarily ductal disease (CBD obstruction) and the measurement of excretion  $T_{1/2}$  aids in separating the diseases that affect the liver diffusely from those that affect the liver regionally (23,24).

### Sclerosing Cholangitis

Sclerosing cholangitis (SC) affects both intra and extrahepatic ducts and often the pathology is regional. In CBD, the level of obstruction is usually more proximal. Patients initially present with high serum alkaline phosphatase and bilirubin rises late in the course of the disease. In 13 patients with sclerosing cholangitis, studied by Rodman et al. planar scintigraphy showed ductal obstruction at multiple levels with typical beading pattern in five and strictures in seven patients; one had normal ducts. Bile pooling proximal to obstruction was not a common feature. HEF remained normal (23) with marked prolongation of hepatic excretion  $T_{1/2}$  which varied widely from region to region. Single photon tomography obtained between 60–90 min supplemented the planar images and often detected lesions in the ducts that could not be assessed by contrast cholangiography due to inability to inject the contrast above the obstructive segment. Often there was obstruction of the cystic duct and post-CCK gallbladder ejection fraction was usually low (24).

### Primary Biliary Cirrhosis

Primary biliary cirrhosis (PBC) is a disease of middle aged women and primarily affects the small intrahepatic bile ducts and canaliculi diffusely while sparing the extrahepatic ducts. The serum often contains antimitochondrial antibody in high titers. Serum alkaline phos-

phatase levels are high from the beginning, whereas the serum bilirubin begins to rise late in the course of the disease. In ten PBC patients studied by Keeffe et al. scintigraphy showed enlargement of the liver with a 6 to 10 fold prolongation of excretion  $T_{1/2}$ , with very little regional variation. Major extrahepatic ducts and the cystic ducts were all normal. Post-CCK gallbladder ejection fraction was low (25).

#### **Isolated Common Bile Duct Obstruction**

Isolated common bile duct obstruction (ICBDO) is usually due to gallstones, benign stricture or malignancy arising within CBD or in the head of the pancreas. In contrast to sclerosing cholangitis, the level of obstruction is usually single and more often located at the distal end of the CBD. Mild elevation of serum alkaline phosphates is the first liver function test to become abnormal. The bile ducts proximal to obstruction remain nondilated early in the course of the disease and begin to dilate when the serum bilirubin levels exceed 10 mg% (26). The hepatic extraction fraction is normal (23) and the excretion  $T_{1/2}$  is two- to three-fold increased and returns to normal when the obstruction is relieved (19). In contrast to SC, bile pooling proximal to obstruction is a salient feature and is seen even when the ducts are nondilated (19,21,22). The site of obstruction may appear as a smooth tapering (benign stricture) or as an abrupt CBD ending (stone). Post-CCK gallbladder ejection fraction and ejection rate are both low (19).

#### **Intrahepatic Cholestasis**

Clinically and biochemically, intrahepatic cholestasis due to drugs (estrogen, phenothiazines), infection (hepatitis), or total parenteral nutrition may present with routine liver function test abnormalities that are indistinguishable from those seen in PSC, PBC, or ICBDO. The prominent features of intrahepatic cholestasis on scintigraphy are diffuse three- to ten-fold prolongation of liver excretion  $T_{1/2}$ , very much analogous to that of PBC (25). The major intra and extrahepatic ducts retain normal caliber (27).

#### **Cholelithiasis**

The abnormal scintigraphic features in cholelithiasis are confined primarily to gallbladder motor function, in the form of reduction in gallbladder ejection fraction (18,28). Clinically, the distinction between chronic cholecystitis versus cholelithiasis is not very clear. Since many patients with nonsymptomatic cholelithiasis may not be treated, many feel that chronic cholecystitis should be differentiated from cholelithiasis. Scintigraphy may aid in making such a distinction. In chronic cholecystitis the gallbladder wall shows diffuse hypertrophy of the muscularis with or without mononuclear cell infiltration and there is 60–80% narrowing of the cystic duct. The patients complain of abdominal pain during post-CCK gallbladder emptying and the gallbladder ejection fraction is <20%. In such patients, the postprandial pain disappears after cholecystectomy (29). Most of the patients with cholelithiasis, on the other hand, show a mere reduction in post-CCK ejection fraction without concomitant abdominal pain during post-CCK gallbladder emptying period (18). We recommend that the term chronic cholecystitis (or cystic duct syndrome) be restricted to those patients who experience pain during CCK induced gallbladder emptying and the term cholelithiasis to those who do not experience post-CCK pain but have gallstones on ultrasound.

#### **Dissemination of Recent Information**

Nuclear medicine physicians should now undertake aggressive educational activities to familiarize the primary physicians with these recent advances in nuclear hepatology. The results of more recent clinical studies should be presented at the medical and surgical grand rounds to familiarize the housestaff with the current level of sophistication in nuclear hepatology. Emphasis should be placed on obtaining scintigraphic studies early before morphologic changes occur. Technetium-99m-IDA studies provide global and regional function directly from the liver and complements morphologic information obtained from CT

and ultrasound. Nuclear medicine physicians can now accelerate widespread acceptance of nuclear hepatology by primary care physicians, internists, gastroenterologists, and hepatologists by participating in widespread dissemination of information already available.

Shakuntala Krishnamurthy and Gerbail T. Krishnamurthy  
Nuclear Medicine Department  
Tuality Community Hospital, Hillsboro  
Nuclear Medicine Service  
VA Medical Center  
Oregon Health Sciences University  
Portland, Oregon

## REFERENCES

1. McClees EC, Yedgudas-McClees RK. Screening for diffuse and focal liver disease. The case for hepatic scintigraphy. *J Clin Ultrasound* 1984; 12:75-81.
2. Lewis F. Screening for diffuse and focal liver disease. The case for hepatic sonography. *J Clin Ultrasound* 1984; 12:67-73.
3. Berland LL. Screening for diffuse and focal liver disease. The case for hepatic computed tomography. *J Clin Ultrasound* 1984; 12:83-89.
4. Reinig JW, Dwyer AJ, Miller DL, et al. Liver metastasis detection: comparative sensitivities of MR imaging and CT scanning. *Radiology* 1987; 162:43-47.
5. Loberg MD, Cooper M, Harvey E, et al. Development of new radiopharmaceutical based on N-substitution of iminodiacetic acid. *J Nucl Med* 1976; 17:633-638.
6. Krishnamurthy GT. Acute cholecystitis: the diagnostic role for current imaging test. *West J Med* 1982; 137:87-94.
7. Weissmann HS, Badia J, Sugarman LA, et al. Spectrum of Tc-99m-IDA cholescintigraphic patterns in acute cholecystitis. *Radiology* 1981; 138:167-175.
8. Weissmann HS, Burkowitz D, Gliedman ML, et al. The role of technetium-99m iminodiacetic acid (IDA) cholescintigraphy in acute acalculous cholecystitis. *Radiology* 1983; 146:177-180.
9. Brachman MB, Tanasescu DE, Ramanna L, et al. Acute gangrenous cholecystitis radionuclide diagnosis. *Radiology* 1984; 151:209-211.
10. Bushnell DL, Pearlman SB, Wilson MA, et al. The rim sign: Association with acute cholecystitis. *J Nucl Med* 1986; 27:353-356.
11. Matzen P, Malchow-Moller A, Brun B, et al. Ultrasonography, computed tomography and cholescintigraphy in suspected obstructive jaundice—a prospective comparative study. *Gastroenterology* 1983; 84:1492-1497.
12. O'Conner KW, Swondgrass PJ, Swonder JE, et al. A blinded prospective study comparing four current non-invasive approaches in the differential diagnosis of medical vs. surgical jaundice. *Gastroenterology* 1983; 84:1498-1504.
13. Loberg MD, Ryan JW, Porter DW. A reply: A letter to the editor. *J Nucl Med* 1980; 21:1111-1112.
14. Scharschmidt BF, Goldberg HI, Schmid R. Approach to the patient with cholestatic jaundice. *N Eng J Med* 1983; 308:1515-1519.
15. Richter JM, Silverstein MD, Schapiro R. Suspected obstructive jaundice: Decision analysis of diagnostic strategies. *Ann Int Med* 1983; 99:46-51.
16. Williams W, Krishnamurthy GT, Brar HS, et al. Scintigraphic variations of normal biliary physiology. *J Nucl Med* 1984; 25:160-165.
17. Bobba VR, Krishnamurthy GT, Kingston E, et al. Comparison of biokinetics and biliary imaging parameters of four Tc-99m iminodiacetic acid derivatives in normal subjects. *Clin Nucl Med* 1983; 8:70-75.
18. Krishnamurthy GT, Bobba VR, McConnell D, et al. Quantitative biliary dynamics: introduction of a new non-invasive scintigraphic technique. *J Nucl Med* 1983; 24:217-223.
19. Krishnamurthy GT, Lieberman D, Brar HS. Detection, localization, and quantitation of degree of common bile duct obstruction by scintigraphy. *J Nucl Med* 1985; 26:726-735.
20. Gilbert S, Brown PH, Krishnamurthy GT. Quantitative nuclear hepatology. *J Nucl Med Tech* 1987; 15:38-43.
21. Zeman RK, Lee C, Jaffe MH, et al. Hepatobiliary scintigraphy and sonography in early biliary obstruction. *Radiology* 1984; 153:793-798.
22. Kaplun L, Weissmann HS, Rosenblatt RR, et al. The early diagnosis of common bile duct obstruction using cholescintigraphy. *JAMA* 1985; 254:2431-2434.
23. Brown PH, Juni JE, Lieberman DA, et al. Hepatocyte vs. biliary disease: A distinction by deconvolutional analysis of Tc-99m-IDA time activity curves. *J Nucl Med* 1988; 29:623-630.
24. Rodman C, Keeffe EB, Lieberman DA, et al. Diagnosis of sclerosing cholangitis with Tc-99m-IDA planar and SPECT scintigraphy. *Gastroenterology* 1987; 92:777-785.
25. Keeffe EB, Lieberman DA, Krishnamurthy S, et al. Scintigraphic features of primary biliary cirrhosis: comparison with sclerosing cholangitis. *Radiology* 1988; 166:143-148.

26. Lapis JL, Orlando RC, Mittelsteaedt A, et al. Ultrasonography in the diagnosis of obstructive jaundice. *Ann Int Med* 1978; 89:61-63.
27. Lieberman DA, Krishnamurthy GT. Intrahepatic versus extrahepatic cholestasis: distinction with biliary scintigraphy combined with ultrasound. *Gastroenterology* 1986; 90:734-743.
28. Fisher RS, Stelzer F, Rock E, et al. Abnormal gallbladder emptying in patients with gallstones. *Dig Dis Sci* 1982; 27:1019-1024.
29. Fink-Bennett D, DeRidder P, Kolozsi W, et al. Cholescystokinin cholescintigraphic findings in the cystic duct syndrome. *J Nucl Med* 1985; 26:1123-1128.
30. Shaffer EA, Hershfield NB, Logan K, et al. Cholescintigraphic detection of functional obstruction of the sphincter of Oddi. Effect of Papillotomy. *Gastroenterology* 1986; 90:728-733.