

Radionuclide Imaging in a Case of Tertiary Syphilis Involving the Liver and Bones

Edward B. Cronin, Walter H. Williams, and Donald E. Tow

Nuclear Medicine Service, Veterans Administration Medical Center, Brockton/West Roxbury, and The Harvard Joint Program in Nuclear Medicine, Boston, Massachusetts

Tertiary syphilis is an unusual entity. We have encountered a case of tertiary syphilis of the liver and bone demonstrated by scintigraphy. With liver involvement, the liver scan showed focal defects due to gummas, and distortion due to scarring. Bone involvement was shown as increased cortical activity from periostitis, focal hot spots due to osteomyelitis, and cold defects due to gumma formation. Because syphilis is easily treated, but may not be as readily recognized, the diagnosis should be considered in cases of focal liver or bone disease of obscure etiology.

J Nucl Med 28:1047-1051, 1987

Syphilis can be a chronic infectious disease; its diagnosis is often overlooked and it may affect many organ systems. Therefore, improved recognition of its manifestations with newer techniques, such as scintigraphy, becomes important. Radionuclide findings in tertiary syphilis have not been reported previously and there are only a few references in the literature dealing with the scintigraphic appearance of earlier forms of acquired syphilis. The following case report illustrates some findings of tertiary syphilis in a patient with bone and liver involvement demonstrated by scintigraphy.

CASE REPORT

A 39-yr-old male patient presented with an 8-mo history of back and right shoulder pain accompanied by 20-lb weight loss. Initial radiographs demonstrated multiple lytic and blastic lesions of the spine at T5, T10, T11, L3, L5, sacrum, and left ilium; destruction of the right glenoid was also noted (Fig. 1). He was admitted for workup of presumed metastatic carcinoma.

Twenty years earlier, the patient had undergone orchiectomy for an undescended testicle and had been treated for urethritis with an unknown antibiotic.

On admission the patient was afebrile; physical examination revealed a liver span of 14 cm with a palpable spleen tip. Percussion tenderness over L3 was present. There were no

skin lesions; cardiac and neurologic examinations were unremarkable.

Laboratory studies included a hematocrit of 36%, ESR 122 mm/hr, alkaline phosphatase 199 IU (normal <115 IU); other liver function studies were normal. Acid phosphatase, carcinoembryonic antigen, alpha fetoprotein, serum protein electrophoresis, and beta human chorionic gonadotrophin levels were normal. A chest x-ray demonstrated slight blunting of the right costophrenic angle; the heart and aorta were normal in appearance.

A bone scan demonstrated intense increased activity of the right glenoid and left third rib; irregular increased and decreased activity was evident in several vertebrae. A cold defect with a rim of increased activity was present in the left ilium (Fig. 2). A liver spleen scan showed hepatosplenomegaly with multiple focal liver defects (Fig. 3); single photon emission computed tomography (SPECT) images of the liver clearly demonstrated the parenchymal defects (Fig. 4). A computed tomography (CT) scan confirmed the presence of liver lesions and destructive change in the spine.

A bone biopsy was unsuccessful and two liver biopsies yielded only necrotic debris and granulomas; no organisms or neoplastic cells were found. Acid fast, PAS, and silver stains were negative. The patient underwent an exploratory laparotomy and was found to have several caseous liver masses but no tumor. Pathology from the surgical material demonstrated necrotic debris, granuloma-like formations, and marked fibrotic reaction surrounding the nodules. Again, acid fast, PAS, and silver stains were negative.

Because of the pathologic appearance, a chronic infectious etiology was believed to be likely and syphilis serologies were obtained. The VDRL was positive at 1:128, FTA-abs 4+; CSF VDRL was also positive. He was treated with intravenous penicillin. After therapy, the back pain resolved and he began to gain weight.

Received Aug. 13, 1986; revision accepted Feb. 4, 1987.

For reprints contact: Walter H. Williams, MD, Nuclear Medicine Service, VA Medical Center, 1400 V.F.W. Parkway, West Roxbury, MA 02132.

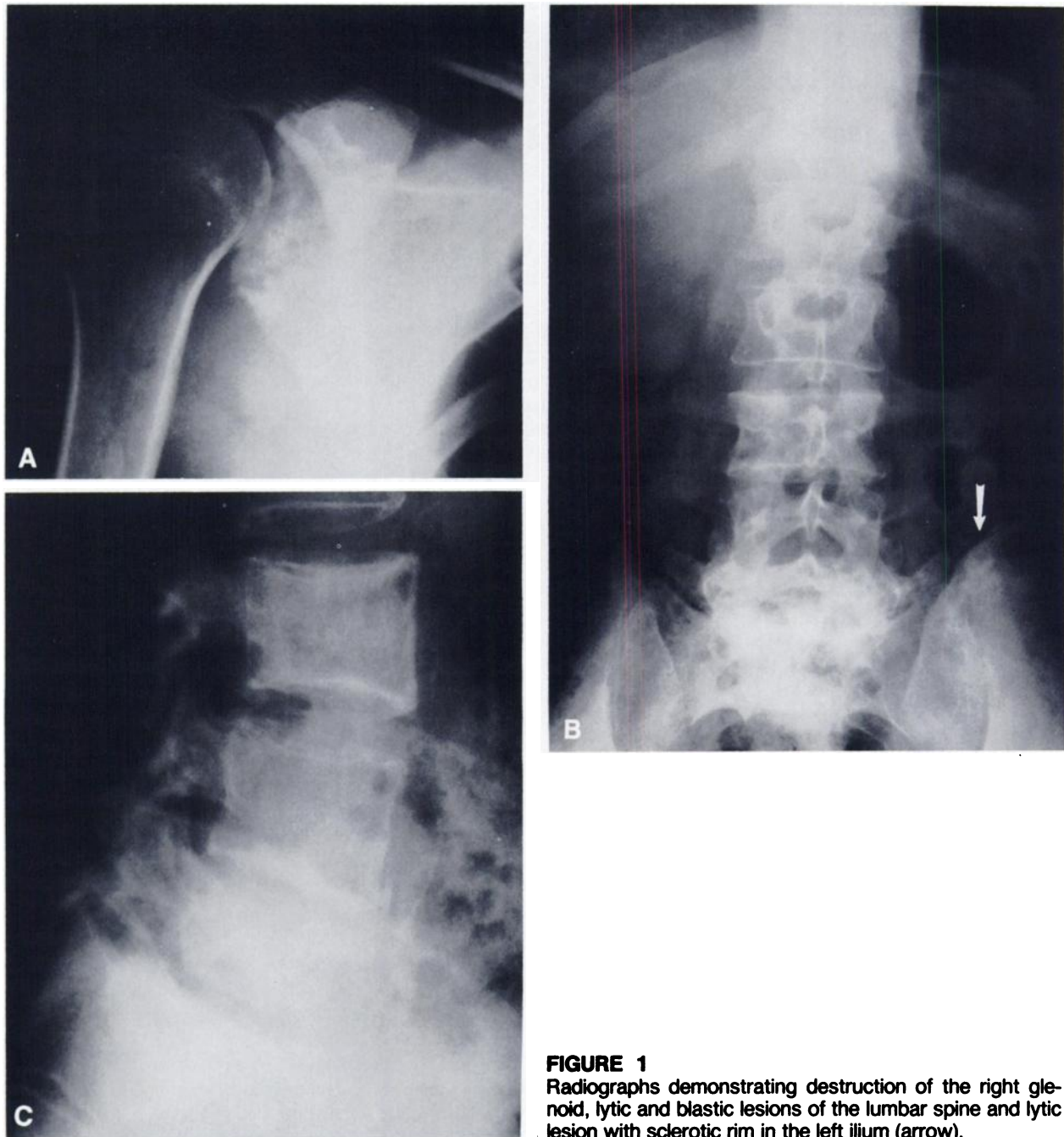


FIGURE 1
Radiographs demonstrating destruction of the right glenoid, lytic and blastic lesions of the lumbar spine and lytic lesion with sclerotic rim in the left ilium (arrow).

DISCUSSION

In 1984, 18,380 cases of late (tertiary) and late-latent syphilis were reported to the Centers for Disease Control (1). This represents ~25% of the nearly 72,000 reported cases of all types of syphilis for that year. The prevalence of tertiary and late-latent syphilis is 7.7/100,000 (1).

Tertiary syphilis is manifested by cardiovascular disease, neurosyphilis, or by gummatous disease (2). A gumma may be found in any organ, but skin, liver, bone, and spleen are the most common sites (2). The causative organism, *Treponema pallidum*, is almost

never seen in a gumma, although material from such a lesion is infective. In late syphilis, the gumma may be suggestive pathologically, but the diagnosis should be confirmed serologically. Penicillin therapy is effective at any stage in eradicating the organism.

Liver involvement may occur in tertiary or secondary syphilis. In late disease, Hahn (3) found the liver to be affected in 4.9% or 66 of 1165 syphilitics examined at autopsy. He found the liver to be affected in a focal manner, by large, often multiple, stellate scars and gummas. Gummas were almost always adjacent to scars. Amyloid of the liver was rare. Of the 66 patients

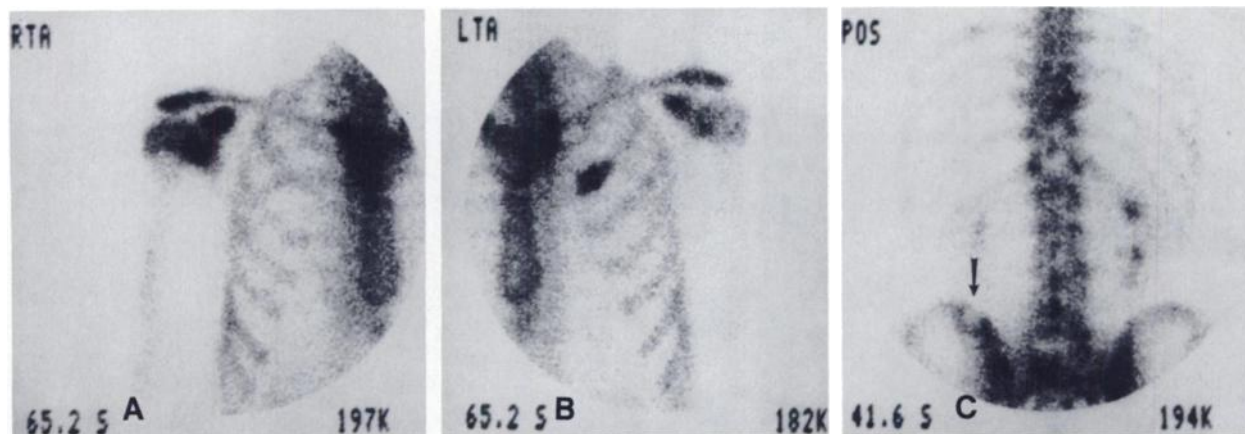


FIGURE 2
Bone scan. Note increased uptake in the right glenoid and left third rib, irregular increased and decreased activity in the lumbar spine and a cold defect with hot rim in the left ilium (arrow).

with tertiary syphilis of the liver, three had livers weighing >2200 g and eight had spleens weighing >300 g.

The scintigraphic appearance of liver disease in tertiary syphilis has not been described previously. The scan findings in this patient do appear consistent with Hahn's findings, however. Thus, one would expect varying degrees of liver distortion and focal liver defects due to scarring and gumma formation. Liver and spleen size should be normal or moderately enlarged. In the presence of severe hepatosplenomegaly, ascites, or severe liver dysfunction, the abnormalities are unlikely to be due to syphilis, and another cause should be sought. Patients with known syphilis do have a higher incidence of other liver diseases (4).

Scintigraphic abnormalities of the liver in secondary syphilis have not been reported. Siegel and Hirschman reported a patient with an elevated alkaline phosphatase but normal liver scan (5). Two other case reports demonstrated normal ultrasound findings in the presence of biopsy abnormalities (6,7); a single report, however,

describes focal lesions of the liver on both ultrasound and CT, but had no biopsy documentation of the cause (8).

Several investigators have reported that bone scintigraphy is sensitive for detection of bone lesions in secondary syphilis (5,9-11); bone scanning can detect affected regions that appear normal on plain radiographs (5,9,10) and, therefore, yield a better evaluation of extent of disease. Abnormal regions were described as areas of streaky, linear or focal increased activity. Scintigraphic abnormalities may persist for several months following adequate therapy (5,9,10). Veerapen et al. (9) reported one case in which scintigraphic resolution was noted at 7 mo, and Hansen et al. (10) reported 50% resolution of scan abnormalities at 9 mo in one patient.

In tertiary syphilis, bone lesions may be due to gummas, periostitis, or osteomyelitis (12). According to Resnick (13), the cranial vault, nasal bones, maxilla, mandible, tubular bones of the appendicular skeleton,

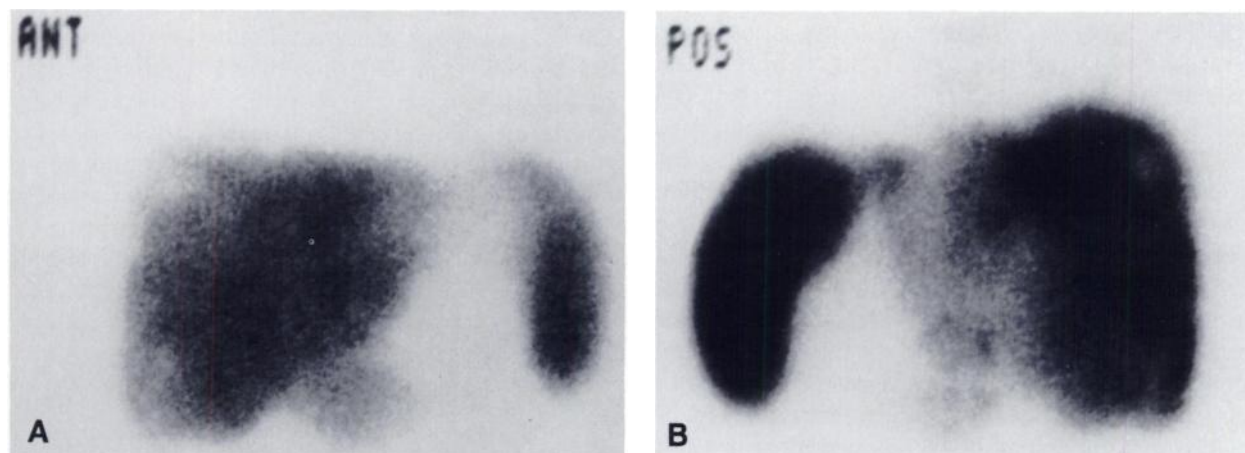


FIGURE 3
Liver-spleen scan. Liver is irregular with focal defects.

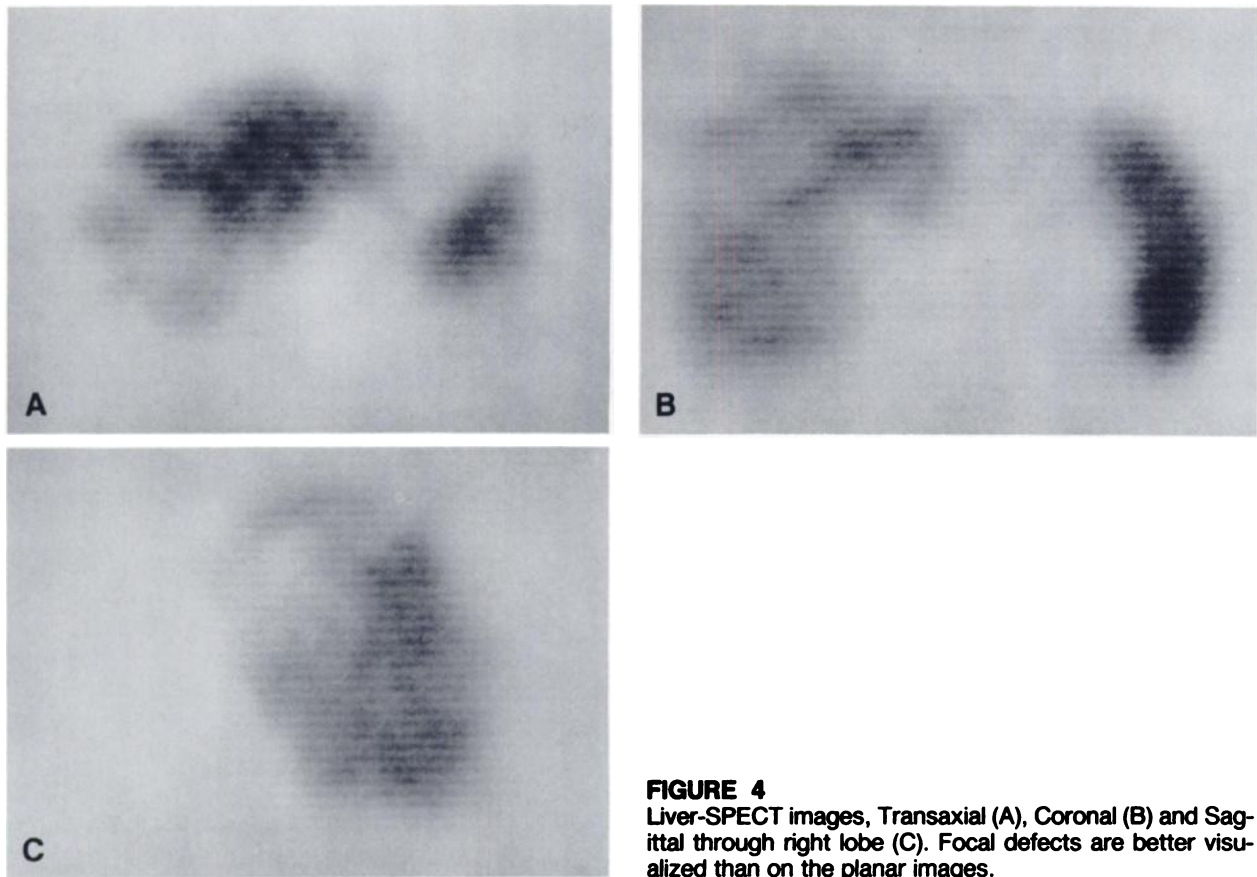


FIGURE 4
Liver-SPECT images, Transaxial (A), Coronal (B) and Sagittal through right lobe (C). Focal defects are better visualized than on the planar images.

spine, and pelvis may be affected in tertiary syphilis. In the spine, the vertebral body is most commonly affected (14). Articular involvement in tertiary syphilis is rare (12,13). The knee and elbow are most commonly affected, whereas, ankle, shoulder, and wrist less frequently seen; involvement tends to be symmetrical (12).

The bone scan appearance of tertiary syphilis also has not been previously described. Osteomyelitis, periostitis, and proliferative bony change should give rise to regions of increased uptake. Gummas with their associated bony destruction, if extensive enough, may be identified as photopenic or "cold" defects. In this patient, the intense uptake and radiographic changes in the rib and glenoid lesions suggests destructive osteomyelitis. A ring of increased activity surrounding a cold defect, as seen in the left ilium in this case, may reflect either ongoing inflammation around a gumma or, possibly, healing of a gummatous lesion. The irregular increased and decreased activity of the spine, with destructive and blastic changes evident radiographically indicates there may be osteomyelitis, gummatous change, or both occurring there. Neuropathic joint disease may occur in late syphilis due to tabes dorsalis. No reports of scintigraphy in syphilitic neuroarthropathy exist. However, in diabetic osteoarthropathy, focal and diffuse uptake of affected joints has been reported; scan

abnormalities were always more extensive than and often preceded radiographic changes (15). The pathologic changes of affected joints are similar in these two entities, thus scintigraphic abnormalities should be comparable.

CONCLUSION

Acquired syphilis remains an unusual entity in clinical practice. Its presentation is often ambiguous, with nonspecific manifestations involving several organ systems. The liver or bone scan findings in syphilis may also be nonspecific and suggestive of a variety of processes, such as metastatic neoplasm, which are far more commonly seen. In cases with bone or liver disease of obscure etiology, syphilis should be a consideration. Once suspected, it is reliably diagnosed by serologic testing and readily treated with antibiotics, sparing the patient from more invasive and potentially morbid evaluation procedures.

REFERENCES

1. Centers for Disease Control. STD Statistics 1984. Number 134:25-31, December 1985.
2. Tramont EC. *Treponema pallidum* (syphilis). In: Mandell GL, Douglas RG, Bennett JE, eds. Principles and practice of infectious diseases, 2nd ed. New York:

- John Wiley and Sons, 1985:1323–1333.
3. Hahn RD. Syphilis of the liver. *Am J Syphilis* 1943; 27:529–562.
 4. Holmes KK. Syphilis. In: Petersdorf RG, Adams RD, Braunwald E, et al., eds. *Harrison's principles of internal medicine*, 10th ed. New York: McGraw-Hill, 1983:1034–1045.
 5. Siegel D, Hirschman SZ. Syphilitic osteomyelitis with diffusely abnormal bone scan. *Mt Sinai J Med* 1979; 46:320–322.
 6. Petersen LR, Mead RH, Perlroth MG. Unusual manifestations of secondary syphilis occurring after orthotopic liver transplantation. *Am J Med* 1983; 75:166–170.
 7. Agrawal NM, Sarris M, Brooks B, et al. The liver in secondary syphilis. *South Med J* 1982; 75:1136–1138.
 8. Vas W, Thomasson J, Tang-Barton P, et al. Computed tomography and ultrasound appearance of liver disease in secondary syphilis. *Diagn Imag Clin Med* 1985; 54:1–6.
 9. Veerapen K, Bruckner FE, Halsey JP, et al. Periostitis in secondary syphilis: a place for bone scintigraphy. *J R Soc Med* 1985; 78:721–724.
 10. Hansen K, Hvid-Jacobsen K, Lindewald H, et al. Bone lesions in early syphilis detected by bone scintigraphy. *Br J Vener Dis* 1984; 60:265–268.
 11. Tight RR, Warner JF. Skeletal involvement in secondary syphilis detected by bone scanning. *JAMA* 1976; 235:2326.
 12. Jaffe HL. Acquired syphilis. In: *Metabolic degenerative and inflammatory diseases of bones and joints*. Philadelphia: Lea and Febiger, 1972:924–941.
 13. Resnick D. Syphilis. In: Resnick D, Niwayama G, eds. *Diagnosis of bone and joint disorders*. Philadelphia: W. B. Saunders, 1981:2188–2198.
 14. Johns D. Syphilitic disorders of the spine. *JBJS* 1970; 52B:724–731.
 15. Eymontt MJ, Alavi A, Dalinka MK, et al. Bone scintigraphy in diabetic osteoarthropathy. *Radiology* 1981; 140:475–477.