

---

# Radionuclide Diagnosis and Therapy of Neural Crest Tumors Using Iodine-131 Metaiodobenzylguanidine

C. A. Hoefnagel, P. A. Voûte, J. de Kraker, and H. R. Marcuse

*Department of Nuclear Medicine and Werkgroep Kindertumoren, The Netherlands Cancer Institute, Plesmanlaan 121, 1066 CX Amsterdam, The Netherlands*

The successful application of [<sup>131</sup>I]metaiodobenzylguanidine (MIBG) in diagnosis and therapy of pheochromocytoma has led to its use in other tumors which derive from the neural crest and potentially concentrate this radiopharmaceutical as well. In the present series, [<sup>131</sup>I]MIBG total-body scintigraphy was used for detection of neuroblastoma in 47 patients and 47 cases of other neural crest tumors. The method was found to be as reliable in neuroblastoma (sensitivity 95%, specificity 100%), as it is in pheochromocytoma. Although other neural crest tumors may concentrate [<sup>131</sup>I]MIBG, this is not a consistent finding; however, it is useful to investigate which tumors do, as this may provide an alternative treatment modality for some patients. Although followup is still very short, preliminary results of therapeutic use of [<sup>131</sup>I]MIBG in 21 patients indicate that this treatment modality may be effective in neuroblastoma and malignant pheochromocytoma.

J Nucl Med 28:308-314, 1987

---

Iodine-131 metaiodobenzylguanidine ([<sup>131</sup>I]MIBG) has proven to be useful in the localization (1,2) and therapy (3,4) of pheochromocytoma. More recently, [<sup>123</sup>I]MIBG has been introduced for diagnostic purposes (5).

As this radiopharmaceutical is concentrated in neurosecretory storage granules of chromaffin cells (6), it was to be expected that other tumors, which derive from the neural crest and are capable of production and storage of catecholamines, might also concentrate [<sup>131</sup>I]MIBG. After case reports of [<sup>131</sup>I]MIBG concentration in neuroblastoma (7,8), series of 20 and ten patients with this tumor have been reported (9,10). Tumor concentrations of [<sup>131</sup>I]MIBG in some of these patients were found to be adequate for potential therapeutic use of this agent.

In addition, cases of [<sup>131</sup>I]MIBG-positive medullary thyroid carcinoma (11,12), paraganglioma (13), and carcinoid (14) have been reported, as well as therapeutic use in a patient with a carcinoid of the stomach (15).

We have further evaluated the diagnostic yield of [<sup>131</sup>I]MIBG total-body scintigraphy in 47 patients with neuroblastoma and 47 patients with other neural crest tumors and have used [<sup>131</sup>I]MIBG for treatment in 21 patients.

## PATIENTS AND METHODS

Forty-seven patients with histologically confirmed neuroblastoma (24 F, 23 M) were examined. Forty-two were children with ages ranging 0-14 yr, the other patients were aged 17, 18, 22, 32, and 52 yr, respectively. Disease was documented with plain radiographs, ultrasonography, computed tomographic scans, bone scintigraphy, and/or bone marrow aspirations. In all patients the urinary excretion of catecholamines and catecholamine metabolites were determined as previously described (16). Eight patients had residual or recurrent abdominal tumor masses, 33 had metastases and six were in complete remission. A total of 169 [<sup>131</sup>I]MIBG studies have been performed in these patients.

Forty-seven patients with other neural crest tumors, confirmed histologically, were examined, 20 females and 27 males, of whom six were children (60 studies). Nine of these patients had pheochromocytoma (two malignant), eight medullary thyroid carcinoma (sporadic), 12 carcinoid, two a ganglioneuroma, one an unclassified neuroectodermal tumor of the lung and two paraganglioma. Iodine-131 MIBG scintig-

---

Received Feb. 3, 1986; revision accepted July 17, 1986.

For reprints contact: C. A. Hoefnagel, MD, Dept. of Nuclear Medicine, Antoni van Leeuwenhoekhuis, The Netherlands Cancer Institute, Plesmanlaan 121, 1066 CX Amsterdam, The Netherlands.

raphy was also done in six patients with melanoma, four with oat cell carcinoma and three with neurofibromatosis.

Total-body scintigraphy was performed 24, 48, and 72 hr after i.v. injection of 0.5 mCi [<sup>131</sup>I]MIBG in children (18.5 MBq) or 1 mCi [<sup>131</sup>I]MIBG in adults (37 MBq). A potassium-iodide solution (containing 60 or 120 mg KI and 30 or 60 mg free iodine, respectively) was administered orally for 5 days to prevent <sup>131</sup>I concentration in the thyroid. Multiple digital images in a 256 × 256 matrix were made using a large field-of-view gamma camera fitted with a parallel hole, high-energy collimator and connected with an on-line computer system, acquiring counts over 10 min.

At three to four different intervals after administration of [<sup>131</sup>I]MIBG, concentrations at tumor sites were measured by comparing counts in the tumor region, from which counts from an adjacent background region were subtracted, to those of an <sup>131</sup>I standard solution. Concentrations were expressed as a percentage of the given dose and the effective half-life was calculated (17). The myocardial uptake was recorded and scored normal, diminished, or absent on 48-hr scintigrams. Single photon emission tomography was performed after tracer doses in four patients and with therapeutic amounts of [<sup>131</sup>I]MIBG in 14 patients, using a dual head rotating gamma camera fitted with parallel hole, medium-energy collimators. Selected upon the merits of dosimetry and the availability of other treatment modalities 21 patients have received [<sup>131</sup>I]MIBG therapy. Fifteen children and one adult with neuroblastoma received multiple therapeutic doses of 41-200 mCi (1.5-7.4 GBq), administered intravenously over 1-4 hr at 3-6 wk intervals initially. In only five of these patients the tumor concentration exceeded 1.0% of the dose, in three patients 3.0% of the dose and in the other patients the indication for therapy was progressive or residual disease after all other treatment modalities had been used. Five adults, one with medullary thyroid carcinoma, two with malignant pheochromocytoma, and two with carcinoid received 87-213 mCi (3.2-7.9 GBq) doses. Patients were admitted to hospital isolation facilities for 4-5 days and used the iodide medication for 2 wk. In case of isolation of a young child one of the parents, taking precautions as has been described (18), was involved in caring for the child; the external radiation dose to these parents was monitored continuously with a pocket dosimeter and internal contamination was checked daily by counting a urine sample in a gamma counter. The parent also used the iodide solution (120 mg KI + 60 mg free I) for 5 days.

## RESULTS

### Diagnosis

In 47 patients with neuroblastoma 169 total-body scintigrams using [<sup>131</sup>I]MIBG were made. The results are listed in Table 1. In six patients who were in a complete remission with negative catecholamine metabolites in urine the scintigram showed no pathological concentration of [<sup>131</sup>I]MIBG (Fig. 1A). Iodine-131 MIBG scintigraphy was positive in 39 of 41 patients (95%) with histologically confirmed neuroblastoma. Among these were six patients with negative urinary excretion of catecholamine metabolites. Both false-neg-

**TABLE 1**  
Iodine-131 MIBG Total-Body Scintigraphy Results in Neuroblastoma

	Scintigram +	Scintigram -	Total
Neuroblastoma +	39	2	41
Neuroblastoma -	0	6	6
Total	39	8	47

ative results occurred in adults, who also had a negative urinalysis. The scintigram detected primary, residual, or recurrent abdominal masses in 17 patients (Figs. 1B and 1C), skeletal metastases in 23 (Fig. 1D), diffuse bone marrow infiltration in six (Fig. 1E), lymph node metastases in 12 (Fig. 1F), liver metastases in two, and a soft-tissue metastasis in one patient. Tumor concentrations of [<sup>131</sup>I]MIBG ranged 0.05-10.1% dose, the calculated effective half-life 2.6-8.0 days.

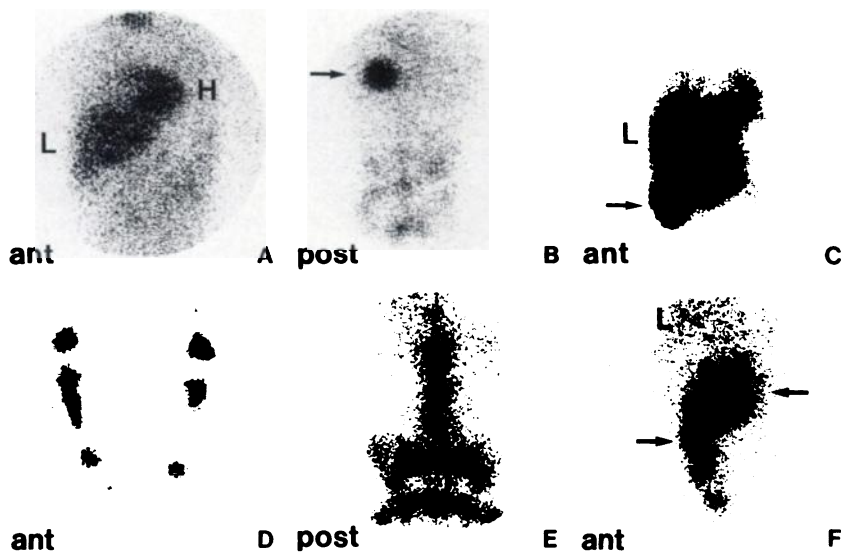
Myocardial uptake of [<sup>131</sup>I]MIBG was regarded to be normal in the six patients who were in a complete remission (Fig. 1A). However, in [<sup>131</sup>I]MIBG-positive cases of neuroblastoma the myocardial concentration was found to be normal in two, diminished in 27, and absent in nine patients. Twenty-seven patients had multiple examinations during the course of their disease: in 16 patients, whose condition improved by chemotherapy, myocardial concentration of [<sup>131</sup>I]MIBG reappeared in three, increased in 11, and showed no change in two patients; however, in 11 patients with progression of disease myocardial uptake disappeared in four, decreased in six, and remained the same in one patient. These changes in myocardial uptake were inversely correlated with those in the levels of catecholamines and catecholamine metabolites excreted in urine.

Single photon emission tomography demonstrated residual disease behind the bladder in one patient, which was missed on conventional scintigraphy, revealed more tumor localizations in three patients, led to a better understanding of the location and the extent of disease in eight patients, and added no new information in the remaining six patients (Fig. 2).

In the 47 patients with other neural crest tumors 68 [<sup>131</sup>I]MIBG scintigrams were made. Table 2 gives the results in this group together with those in neuroblastoma. Tumor concentration of [<sup>131</sup>I]MIBG was found in all nine cases of pheochromocytoma, in two of eight patients with medullary thyroid carcinoma, in six of 12 patients with carcinoid, in two patients with a ganglioneuroma, and in one patient with an unclassified neuroectodermal tumor of the lung. All other studies were false negative. Figure 3 shows multiple metastases from malignant pheochromocytoma, Figure 4 liver metastases from a carcinoid of the stomach, and Figure 5 lymph node and liver metastases from medullary thyroid carcinoma.

**FIGURE 1**

Iodine-131 MIBG scintigrams in neuroblastoma, taken 2 days after administration. A: Normal distribution of [<sup>131</sup>I]MIBG in the myocardium (H) and liver (L) of a patient in a complete remission. B: Primary neuroblastoma of the left adrenal gland (arrow). C: Recurrent abdominal neuroblastoma (arrow). D: Skeletal metastases in the lower extremities. E: Diffuse bone marrow infiltration. F: Multiple abdominal lymph node metastases (arrow).



**Therapy**

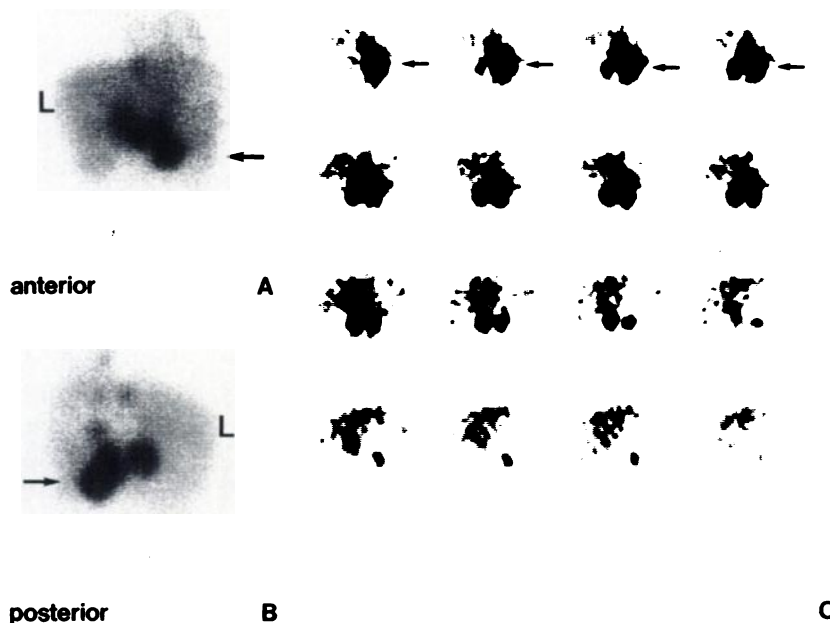
Twenty-one patients received 64 therapeutic doses of [<sup>131</sup>I]MIBG. The indications for treatment, dosages, intervals, results, and side effects are listed in Tables 3 and 4.

The first two patients with chemotherapy resistant progressive neuroblastoma showed a marked regression (50%) of the tumor mass with good palliation (relief of pain). However, the initial response was followed by rapid progression. In the third patient, [<sup>131</sup>I]MIBG therapy was combined with subsequent chemotherapy (ARA-C): regression and palliation were achieved, but after three cycles [<sup>131</sup>I]MIBG therapy was discontinued due to severe bone marrow toxicity. These patients have died after 2, 4, and 4 mo, respectively.

In the other patients with neuroblastoma the follow-

ing results were obtained: (a) a complete remission in two patients, one of whom had a relapse in the bone marrow after 3 mo; the other developed recurrent bone metastases after 9 mo and is again being treated with [<sup>131</sup>I]MIBG; (b) partial remissions with a good palliative effect (relief of pain) in five patients, i.e., a >50% decrease in tumor volume in three and decrease of scintigraphic and biochemical evidence of bone metastases in two patients; (c) no change in two patients; and (d) in three patients, who are still on treatment, the tumor response has not been evaluated yet; one patient was lost to followup.

In these patients the following side effects were recorded: bone marrow depression in three patients, two had bone marrow involvement and the third pre-existent bone marrow depression after autologous bone



**FIGURE 2**

Anterior (A) and posterior (B) conventional scintigrams and transaxial single photon emission tomograms (6 mm eff. slice thickness) of the abdomen, taken after 3 days, showing recurrent neuroblastoma localizations (arrow) below and behind the liver (L).

**TABLE 2**  
Iodine-131 MIBG Total-Body Scintigraphy Results in  
Neural Crest Tumors

Diagnosis	TP <sup>†</sup>	TN <sup>†</sup>	FP <sup>‡</sup>	FN <sup>§</sup>	Total
Neuroblastoma	39	6	—	2	47
Pheochromocytoma	9	—	—	—	9
Medullary thyroid carc.	2	—	—	6	8
Carcinoid	6	—	—	6	12
Ganglioneuroma	2	—	—	—	2
Neuroectodermal tumor	1	—	—	—	1
Paraganglioma	—	—	—	2	2
Neurofibromatosis	—	—	—	3	3
Oat cell carcinoma	—	—	—	4	4
Melanoma	—	—	—	6	6
<b>Total</b>	<b>59</b>	<b>6</b>	<b>—</b>	<b>29</b>	<b>94</b>

<sup>†</sup> True positive.

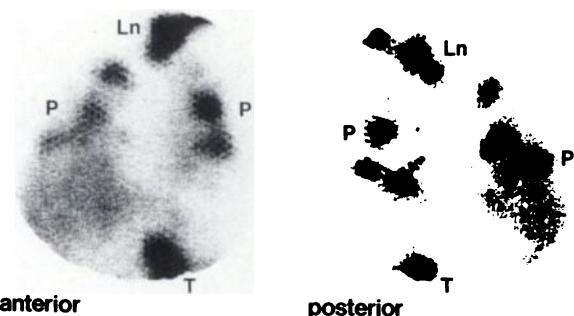
<sup>†</sup> True negative.

<sup>‡</sup> False positive.

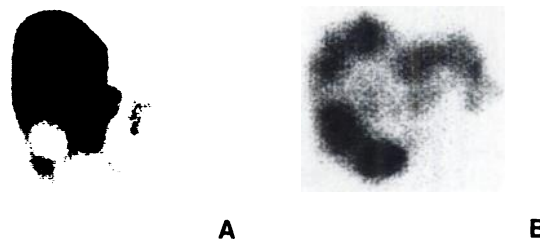
<sup>§</sup> False negative.

marrow transplantation; one patient had a mild leucopenia ( $3.1 \times 10^9/l$ ) and four patients developed transient thrombocytopenia ( $40-120 \times 10^9/l$ ); one patient, who received the highest cumulative dose ( $40.7 \text{ GBq} = 1,100 \text{ mCi}$ ) and previously underwent a unilateral adrenalectomy, developed adrenal insufficiency requiring substitution therapy.

Of the five patients treated for other neural crest tumors, one patient with malignant pheochromocytoma shows radiological evidence of regression of lung metastases and the second pheochromocytoma patient was relieved of bone pain; the patient with metastatic medullary thyroid carcinoma shows no change; in one patient with carcinoid liver metastases causing pain, nausea, anorexia, and fever, disease progressed although a good palliative effect had been obtained; the other patient with chemotherapy resistant carcinoid liver and bone metastases was completely relieved of pain. No



**FIGURE 3**  
48-hr scintigrams of the thorax showing multiple pulmonary (P) and lymph node (Ln) metastases from malignant pheochromocytoma of the left adrenal gland (T).



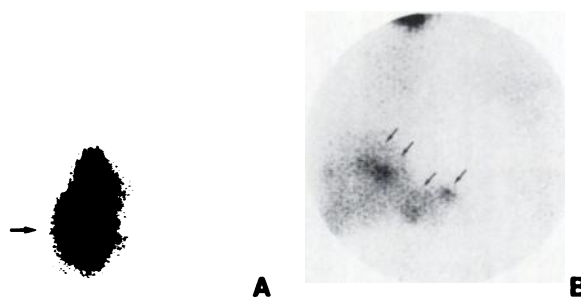
**FIGURE 4**  
Anterior abdominal scintigram 3 days after administration of [<sup>131</sup>I]MIBG, showing concentration in liver metastases from a carcinoid of the stomach (B), closely correlating with the defects in colloid deposition shown by the liver scintigram (A).

side effects were recorded in these patients. Figure 6 demonstrates the therapeutic effect of [<sup>131</sup>I]MIBG on multiple skeletal metastases in a 12-yr-old girl with neuroblastoma.

In neuroblastoma patients the calculated radiation dose to the tumor was greater than 30 Gy in seven (one complete remission, five partial remissions, and one no change), between 10 and 30 Gy in two (both partial remissions) and lower than 10 Gy in three patients (one complete remission, one partial remission, and one no change). Continuous monitoring of the external radiation dose to parents participating in patient care during isolation therapy showed cumulative doses of 30-125 mrem (0.3-1.25 mSv) per treatment dose. The calculated dose equivalent from internal contamination range was 0.03-2.4 mrem (0.3-24  $\mu\text{Sv}$ ). This was judged acceptable.

## DISCUSSION

The efficacy of [<sup>131</sup>I]MIBG scintigraphy for detection of pheochromocytoma has been well established. A



**FIGURE 5**  
Anterior 48-hr scintigrams of a patient with inoperable medullary thyroid carcinoma, revealing intense tumor concentration of [<sup>131</sup>I]MIBG in lymph node metastases in the neck (A), as well as in clinically unsuspected liver metastases (arrows, B).

**TABLE 3**  
Patient Data, Indications, Doses, and Results of [<sup>131</sup>I]MIBG Therapy in Neuroblastoma

Patient no./age (yr)	Diagnosis	Site/indication	Dose in GBq (interval)	Result	Side effects
1. M; 4	Neuroblastoma	Soft tissue/progressive	2.2	Temporary regression (50%)	None
2. F; 5	Neuroblastoma	Abdomen + bone/progressive	1.7/2.7/1.7 (3–6 wk)	Temporary regression (50%) good palliation	BM-depression
3. M; 2	Neuroblastoma	Bone/progressive	2.0/2 × 3.7 (3 wk) + chemotherapy	Temporary regression/good palliation	BM-depression
4. M; 7	Neuroblastoma	Bone/residual disease	1.5/4 × 3.7 (3–5 wk)	Partial remission	Thrombocytopenia
5. M; 22	Neuroblastoma	Abdomen + mediastinum/progressive	3.7/5 × 7.4 (4 wk, later 3 m)	Partial remission (75+%)	Adrenal insufficiency
6. F; 12	Neuroblastoma	Bone + abdomen/residual disease	3 × 3.7 (4 wk)	Complete remission (9 m)	BM-depression (pre-existent)
7. M; 5	Neuroblastoma	Abdomen/recurrent	3.7/5.5/3.7/5.5 (3 wk)	Complete remission (3 m)	Mild leucopenia
8. M; 4	Neuroblastoma	Abdomen/progressive	3.7	Lost to follow-up	—
9. M; 4	Neuroblastoma	Bone + bone marrow/residual disease	3 × 3.7 (3 + 7 wk)	Partial remission (90%)	BM-depression
10. F; 4	Neuroblastoma	Bone marrow/residual disease	3.7/3.7/5.5/2.3 (4–8 wk)	No change	BM-depression
11. M; 2	Neuroblastoma	Bone + liver + ln/progressive	6 × 3.7 (4 wk)	Partial remission	Thrombocytopenia (sixth dose only)
12. F; 9	Neuroblastoma	Soft tissue/residual	3.7/5.5 (4 wk)	No change	None
13. F; 7	Neuroblastoma	Soft tissue/residual	3.7/5.5/3.7 (5 wk)	On treatment	Thrombocytopenia (second dose)
14. F; 13	Neuroblastoma	Bone/progressive	3.7/3.7/5.5 (5 wk)	Partial remission	Thrombocytopenia
15. F; 7	Neuroblastoma	Lymph node/residual	2 × 3.7 (5 wk)	On treatment	None
16. F; 3	Neuroblastoma	Bone/residual disease	2 × 3.7 (4 wk)	On treatment	None

**TABLE 4**  
Patient Data, Indications, Doses and Results of [<sup>131</sup>I]Therapy in Other Neural Crest Tumors

Patient no./age (yr)	Diagnosis	Site/indication	Dose in GBq (interval)	Result	Side effects
1. M; 67	Malignant pheochromocytoma	Lung + lymph node/progressive	3.7/4 × 7.4 (2–6 m)	Partial remission	None
2. M; 77	Medullary thyroid carcinoma	Lymph node + liver/progressive	3.2	No change	None
3. F; 39	Carcinoid	Liver/progressive	7.7/7.9 (4 wk)	Good palliation, progression	None
4. F; 63	Carcinoid	Liver + bone/progressive	4.7/2 × 7.4 (6 wk)	Good palliation, no change	None
5. M; 57	Malignant pheochromocytoma	Bone + lung/progressive	7.4	Palliation	None

recent survey of experience in 400 cases at the University of Michigan (19) showed an overall sensitivity of 87.4% and a specificity of 98.9%.

The present study demonstrates that the same diagnostic accuracy can be achieved in neuroblastoma. The fact that the only two false-negative results occurred in adults with no elevated urinary excretion of catecholamine metabolites raises the question whether these neuroblastomas are tumors of the sympathetic nervous tissue. It is not possible to differentiate between neuroblastomas of different nervous tissues on morphologic criteria.

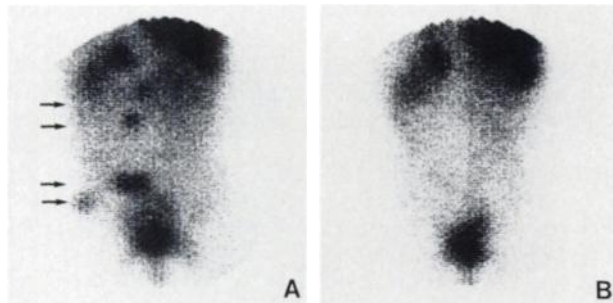
Microscopic residual disease was detected in eight patients, demonstrating that for detection the adrenergic activity of the tumor is more important than the volume. Despite negative outcome of the urinalysis for catecholamine metabolites, which so far has been regarded to be the most sensitive indicator of active neuroblastoma, [<sup>131</sup>I]MIBG scintigraphy revealed metastases, which were histologically confirmed, in six of these patients. For follow-up we now regard [<sup>131</sup>I]MIBG scintigraphy to be the more sensitive parameter and have started to confirm clinical and biochemical com-

plete remissions with this technique routinely and repeat scintigraphy every 6 mo thereafter or whenever clinical symptoms or elevation of catecholamine metabolites in urine occur.

The use of [<sup>123</sup>I]MIBG for this purpose has advantages in terms of imaging properties and radiation burden and is also more suitable for single photon emission tomography. However, as the maximum tumor uptake was usually found only after 48 hr and often the feasibility of [<sup>131</sup>I]MIBG therapy was to be evaluated, prolonged imaging was indicated and therefore the longer half-life of [<sup>131</sup>I]MIBG preferred.

Consistent with the observation of rapid [<sup>131</sup>I]MIBG clearance from the heart in pheochromocytoma (20), an inverse relationship between myocardial and tumor activities was found in neuroblastoma patients. In 18 patients, MIBG single photon emission tomography was performed. Although the gamma camera used was not specifically equipped for the <sup>131</sup>I energy peak, transaxial reconstructions demonstrating the [<sup>131</sup>I]MIBG distribution in depth could be obtained satisfactorily (21). Three-dimensional display was found to be very helpful in localizing disease, especially of tumor localizations in the vicinity of the liver and the bladder.

The concentrations of [<sup>131</sup>I]MIBG and the relatively long biologic half-life at tumor sites in comparison to normal tissues makes therapy with this radiopharmaceutical feasible. In analogy with the use of <sup>131</sup>I in thyroid cancer, [<sup>131</sup>I]MIBG tracer studies can reveal which patients might benefit from this form of treatment. However, the calculation of the absorbed radiation dose suffers from many inaccuracies, caused by the choice of region of interest and the method of background subtraction, variations in geometry and homogeneity of tracer uptake, and the assumption that the biologic decay is monoexponential. More importantly, although a tumor volume may be assessed by other imaging modalities, such as CT scan, magnetic resonance imaging, and ultrasonography, determination of the actual mass of viable tumor tissue to be



**FIGURE 6**  
Posterior view scintigrams of abdomen/pelvis 3 days after the first (A) and third (B) [<sup>131</sup>I]MIBG therapy dose (3.7 GBq) in a 12-yr-old girl with multiple skeletal metastases from neuroblastoma (arrows), demonstrating a good response to treatment.



treated creates the greatest error in the calculated radiation dose. Not surprisingly in this series the calculated absorbed radiation dose and the tumor response obtained were not closely correlated in every case. Therefore, the technique of assessment of the absorbed radiation dose from treatment with unsealed sources requires further development. Because of the aggressive nature of widespread neuroblastoma in early childhood the intervals chosen for therapy were relatively short (3-6 wk) in comparison to those reported for therapy of pheochromocytoma in adults (4).

Mechanisms to increase the [<sup>131</sup>I]MIBG therapy effectiveness, such as dose schedules, pharmacological modulation of uptake and release of [<sup>131</sup>I]MIBG in the tumor cell and combination of therapies active in different parts of the tumor cell cycle, need to be investigated. Apart from myelodepression in some patients and the temporary inconvenience of isolation, [<sup>131</sup>I]MIBG therapy is well tolerated, even in very young children. Involving parents in nursing their child during isolation proved to have major advantages at essentially no increased radiation risk.

Whereas [<sup>131</sup>I]MIBG total-body scintigraphy is extremely reliable in the detection of pheochromocytoma and neuroblastoma, positive [<sup>131</sup>I]MIBG scintigrams are not a consistent finding in other neural crest tumors. However, as other treatment modalities are often ineffective in these conditions, it is worthwhile to investigate if tumors in this group concentrate [<sup>131</sup>I]MIBG, as this may provide an alternative treatment modality with meaningful palliation for some patients.

Iodine-131 MIBG has demonstrated its usefulness as an agent for diagnosis, follow-up, and therapy of neuroblastoma, as it is in pheochromocytoma. Other neural crest tumors may occasionally concentrate [<sup>131</sup>I]MIBG; therefore further studies are required to establish which tumors do and by which mechanism.

#### ACKNOWLEDGMENTS

The authors thank the Audiovisual Department of The Netherlands Cancer Institute (department head: Mr. J. Lomecky) for preparing the illustrations of this publication. The determinations of catecholamines and catecholamine metabolites were done by the Biochemistry Department of the Emma Kinderziekenhuis in Amsterdam (N. G. Abeling and A. H. van Gennip).

#### REFERENCES

1. Sisson JC, Frager MS, Valk TW, et al. Scintigraphic localization of pheochromocytoma. *N Engl J Med* 1981; 305:12-17.
2. Sutton H, Wyeth P, Allen AP, et al. Disseminated malignant pheochromocytoma: localisation with iodine-131-labelled meta-iodobenzylguanidine. *Br Med J* 1982; 285:1153-1154.
3. Fischer M, Winterberg B, Müller-Rensing R, et al. Nuklearmedizinische therapie des phäochromocytoms. *Nuc Compact* 1983; 14:172-176.
4. Sisson JC, Shapiro B, Beierwaltes WH, et al. Radiopharmaceutical treatment of malignant pheochromocytoma. *J Nucl Med* 1984; 25:197-206.
5. Lynn MD, Shapiro B, Sisson JC, et al. Portrayal of pheochromocytoma and normal human adrenal medulla by m-[<sup>123</sup>I]-iodobenzylguanidine: concise communication. *J Nucl Med* 1984; 25:436-440.
6. Wieland DM, Brown LE, Rogers WL, et al. Myocardial imaging with a radioiodinated norepinephrine storage analog. *J Nucl Med* 1981; 22:22-31.
7. Feine U, Treuner J, Niethammer D, et al. Erste Untersuchungen szintigraphischen darstellung von neuroblastomen mit <sup>131</sup>I-meta-benzylguanidin. *Nuc Compact* 1984; 15:23-26.
8. Kimmig B, Brandeis WE, Eisenhut M, et al. Scintigraphy of a neuroblastoma with I-131-meta-iodobenzylguanidine. *J Nucl Med* 1984; 25:773-775.
9. Hoefnagel CA, Voûte PA, de Kraker J, et al. Total body scintigraphy with <sup>131</sup>I-meta-iodobenzylguanidine for detection of neuroblastoma. *Diagn Imag Clin Med* 1985; 54:21-27.
10. Geatti O, Shapiro B, Sisson JC, et al. Iodine-131 metaiodobenzylguanidine for the location of neuroblastoma: preliminary experience in ten cases. *J Nucl Med* 1985; 26:736-742.
11. Endo K, Shiomi K, Kasagi K, et al. Imaging of medullary thyroid carcinoma with <sup>131</sup>I-MIBG. *Lancet* 1984; II:233.
12. Sone T, Fukunaga M, Otsuka N, et al. Metastatic medullary thyroid cancer: localization with iodine-131 metaiodobenzylguanidine. *J Nucl Med* 1985; 26:604-608.
13. Smit AJ, van Essen LH, Hollema H, et al. Meta-[I-131]-iodobenzylguanidine uptake in a nonsecreting paraganglioma. *J Nucl Med* 1984; 25:984-986.
14. Fischer M, Kamanabroo D, Sonderkamp H, et al. Scintigraphic imaging of carcinoid tumours with <sup>131</sup>I-metaiodobenzylguanidine. *Lancet* 1984; II:165.
15. Hoefnagel CA, den Hartog Jager FCA, van Gennip AH, et al. Diagnosis and treatment of a carcinoid tumor using I-131-meta-iodobenzylguanidine. *Clin Nucl Med* 1986; 11:150-152.
16. Abeling NG, van Gennip AH, Overmars H, et al. Simultaneous determination catecholamines and metanephrines in urine by HPLC with fluorometric detection. *Clin Chim Acta* 1984; 137:211-226.
17. Marcuse HR, Delprat CC, Delemarre J, et al. Is a comparison of I-131-treatment results by the delivered radiation dose practicable? In: Third international radiopharmaceutical dosimetry symposium, Oak Ridge, FDA 81-8166, 1981, 595-601.
18. Van der Steen J, Maessen HJM, Hoefnagel CA, et al. Radiation protection during therapy of unsealed sources at young children. *Health Phys* 1986; 50:515-522.
19. Shapiro B, Copp JE, Sisson JC, et al. Iodine-131 metaiodobenzylguanidine for the locating of suspected pheochromocytoma: experience in 400 cases. *J Nucl Med* 1985; 26:576-585.
20. Nakajo M, Shimabukura K, Miyaji N, et al. Rapid clearance of iodine-131 MIBG from the heart and liver of patients with adrenergic dysfunction and pheochromocytoma. *J Nucl Med* 1985; 26:357-365.
21. Hoefnagel CA, Klumper A, Voûte PA. Single photon emission tomography using I-131-meta-iodobenzylguanidine in malignant pheochromocytoma and neuroblastoma: case reports. *J Med Imag* 1987;1.